CENTRO HOSPITALAR
LISBOA NORTE, EPE

HOSPITAL DE SANTA MARIA

Hospital Pulido Valente

Livro de Casos Clínicos CHULN

3ª edição

Organização:

Comissão de Médicos Internos CHULN

Comissão organizadora das Jornadas do Internato Médico / Junior Doctors' International Meeting

ISBN:

ISBN 978-989-33-4028-8

9 789893 340288

ÍNDICE

A Man with a Duplicate Home – A Reduplicative Paramnesia Subtype 1
O Homem da Casa Duplicada – Um Subtipo De Paramnésia Reduplicativa

Transnasal Sphenopalatine Ganglion Block in Postdural Puncture Headache 9
Bloqueio do Gânglio Esfeno-palatino na Cefaleia Pós-punção da Dura

Tuberculosis or Atypical Mycobacterial Infection: About a Case in a Health-Care Worker 16
Tuberculose ou Infeção por Micobactérias Atípicas: a Propósito de um Caso num Profissional de Saúde

Night-work and arrhythmia: a clinical case 21
Trabalho noturno e arritmia: um caso clínico

Surgical approach to malignant otitis externa 26
Abordagem cirúrgica da otite externa maligna

Leber's Hereditary Optic Neuropathy – an atypical presentation 32
Neuropatia Ótica Hereditária de Leber – apresentação atípica

Internal mammary artery perforator flap for esophageal reconstruction 36
Reconstrução esofágica com retalho internal mammary artery perforator

Femoral neck fractures following electrical shock injuries 41
Fracturas do colo do femur após electrocussão

Vermilionectomia num caso de queilite actínica 46
Vermilionectomy in a case of actinic cheilitis

A rare biliary cyst – Todani type I 49
Quisto biliar raro – Todani tipo I

Unilateral facial nerve palsy in the setting of Waldenström Macroglobulinemia: an unusual association 55
Parésia Facial Unilateral no contexto de Macroglobulinémia de Waldenström: uma associação pouco habitual

Radiation Recall Dermatitis num Cancro da Mama Localmente Avançado 64
Radiation Recall Dermatits in Locally Advanced Breast Cancer

Treating inside the womb: a rare case of a fetal arrhythmia 68
Tratar dentro do útero: um caso raro de arritmia fetal

Atypical presentation and clinical course in a rare primary malignant giant cell tumor of bone 74
Apresentação e evolução clínica atípicas num raro tumor primário maligno de células gigantes do osso

Colangite Esclerosante Associada a IgG4 82

IgG4-Related Sclerosing Cholangitis

Surgery for a large pelvic chondrosarcoma: pearls and pitfalls of a complex clinical case 90
Tratamento cirúrgico de um volumoso condrossarcoma pélvico: aspetos preponderantes e complicações de um caso clínico complexo

Posterior Reversible Encephalopathy Syndrome- An Atypical Imaging Pattern 97
Síndrome De Encefalopatia Posterior Reversível - Um Padrão Imagiológico Atípico

Schizoaffective disorder: how long does it takes to diagnose? 117
Perturbação esquizoafectiva: quanto tempo demora para o diagnóstico?

Cistinose: Descrição de dois Casos Clínicos 123
Cystinosis: Two case reports

Back pain in cancer patients –they are not always metastasis 128
Dorsalgia em doente oncológico - nem sempre são metástases

Mania Após Um Acidente Vascular Cerebral - Uma Complicação Rara A Não Esquecer 134
Post Stroke Mania - A Rare Complication Not To Forget

Imunoactivação associada à infecção não controlada pelo vírus da imunodeficiência humana – a propósito de um caso clínico 141
Uncontrolled human immunodeficiency virus infection associated immune activation – a case report

Intravascular lymphoma with exclusive involvement of the central nervous system presenting with myelopathy, epileptic seizures and encephalopathy 147
Linfoma intravascular com envolvimento exclusivo do sistema nervoso central com apresentação de mielopatia, crises epilépticas e encefalopatia

The boundaries between persistent delusional disorder associated with alcohol use and alcohol induced psychosis 155
As fronteiras entre a perturbação delirante persistente associada ao uso de álcool e psicose induzida pelo álcool: a propósito de um caso clínico

Ileus biliar: uma causa rara de oclusão intestinal 162
Gallstone ileus: a rare cause of bowel obstruction

Pelvic actinomycosis – Suspicious adnexal mass 169
Actinomicose pélvica – Massa anexial suspeita de neoplasia ginecológica

Cutaneous Angiosarcoma 175
Angiosarcoma cutâneo

Double Trouble in the OR: Lown-Ganong-Levine and long QT syndromes 178
Double Trouble no bloco operatório: Sindrome Lown-Ganong-Levine e QT longo

Alergia ao ácido clavulânico 182
Clavulanic acid allergy

Rhinoentomophthoramycosis 188
Conídiobolomicose Rino-Facial

Acute postpartum dyspnea 193
Dispneia aguda pós-parto

A Man with a Duplicate Home – A Reduplicative Paramnesia Subtype

O Homem da Casa Duplicada – Um Subtipo De Paramnésia Reduplicativa

Inês Souto Braz[a], André Bonito Ferreira[a], Joana Crawford[a], Tiago Mendes[a], Frederico Simões do Couto[b]

[a] Department of Psychiatry and Mental Health, Hospital de Santa Maria – Lisboa, Portugal, [b] Faculty of Medicine, University of Lisbon – Lisboa, Portugal

Abstract:

Reduplicative paramnesia is a delusional misidentification syndrome, characterized by the certainty that a place, person or event is duplicated, coexisting in two different locations simultaneously. Usually, it is attributed to a neurological cause. We present the clinical case of a 77-year-old man, with no previous psychiatric history, and a medical history of two right-sided ischaemic strokes and multiple myeloma. After a short hospital stay, he began reporting that he was certain that his house had been duplicated for 2 years. He also started to have urinary incontinence and gait ataxia. He had no other psychiatric or neurological alterations. The brain MRI showed normal pressure hydrocephalus. This clinical report suggests a possible association between reduplicative paramnesia and normal pressure hydrocephalus, beyond the typical link with right hemisphere lesions.

Resumo:

A Paramnésia Reduplicativa é uma síndrome de falsa identificação delirante, caracterizada pela crença que um lugar, pessoa ou evento foi duplicado, coexistindo simultaneamente em dois lugares diferentes. Frequentemente é-lhe atribuída uma causa neurológica. Apresentamos um caso clínico de um homem de 77 anos de idade, sem história psiquiátrica prévia, com antecedentes médicos de dois AVCs isquémicos direitos e mieloma múltiplo. Após um internamento hospitalar de curta duração, o doente iniciou um discurso de que tinha a certeza que a sua casa tinha sido duplicada há 2 anos atrás. Concomitantemente começou a desenvolver um quadro de incontinência urinária e alterações da marcha, sem outras alterações psiquiátricas ou neurológicas. A RMN-CE evidenciou hidrocefalia de pressão normal. O caso clínico sugere uma associação hipotética entre paramnésia reduplicativa e hidrocefalia de pressão normal, para além além da relação já conhecida com as lesões do hemisfério direito.

Keywords: Reduplicative Paramnesia; Normal Pressure Hydrocephalus; Delusional Misidentification Syndromes; Neuropsychiatry.

Introduction

"Delusional misidentification syndromes" are psychopathological phenomena in which a patient misidentifies people, places or objects; they may be superimposed on neurological or psychiatric disorders (**Table 1**). They can be divided into Capgras and Fregoli delusions as well as intermetamorphosis and twinning (*doppelganger*). Rarer phenomena such as misidentification of Self in the mirror, reduplicative paramnesia and clonal multiplication of the Self are also listed among these syndromes. [1]

Table 1. Subtypes of delusional misidentification syndromes

Syndrome	Clinical Features	Comments
Capgras (negative misidentification)	Familiar persons are impostors or have doubles with different psychic identity	No response to familiar faces despite conscious recognition (opposite of prosopagnosia)
Fregoli (positive misidentification)	A stranger is believed to be a familiar person	A person takes on others' appearances but retains psychic identity; is often the object of persecutory ideas.
Intermetamorphosis	Familiar and unfamiliar people change both physical and mental identity into one another	Usually transforms into someone familiar to the patient
Doppelganger	Familiar or unfamiliar person is mentally and physically transformed into the patient	The patient considers this other person a double of himself
Mirror sign (self-misidentification)	Misidentification of oneself in the mirror	Able to identify others in the mirror while unable to identify himself
Reduplicative Paramnesia Loss of familiarity for places (Capgras for places) Hyperfamiliarity for places	Familiar place (eg home) is considered a duplicate in another location A place simultaneously exists in two or more physical locations	Sometimes labelled foreign reduplicative paramnesia For example, a strange hospital is duplicated in a hometown setting

Reduplicative paramnesia (RP) is characterized by strong adherence to a belief in the duplication or relocation of a familiar place. The term RP was first used by the neurologist Arnold Pick in 1903, whilst describing the phenomenon in a female patient with a suspected neurodegenerative disease [2], who claimed that the Prague clinic she was being treated in was in fact an exact replica of the clinic in her hometown, and that she was actually in the 'duplicate' clinic of her hometown and not Prague. When questioned about this she insisted that Pick and the hospital staff worked at both locations in order to explain the discrepancies. It is a common characteristic of RP patients to remain certain that their claims are correct, even when other, plausible, explanations are presented [3].

Three variants of RP may be present alone or coexist. 'Place reduplication' refers to the belief that two places with identical features exist simultaneously, but are geographically distant. 'Chimeric assimilation' presents as two places becoming combined, for example, a patient in hospital believes that he/she is in his/her own home which has somehow transformed into the hospital. Finally

‘extravagant spatial localization’ presents as a patient believing that their current location is actually somewhere else, usually a location familiar to them. [3]

RP is generally considered to be of primarily neurologic aetiology and falls within the domain of a neuropsychiatric disturbance. [3-5]. It has been associated with a variety of neurologic disorders such as tumours, strokes, degenerative disorders and traumatic head injuries. Most commonly, lesions are localized in the right hemisphere and/or frontal (including bi-frontal) regions. [5-8]. The right hemisphere plays an important role in visuospatial functions, spatial organization, facial recognition, and emotional and *gestalt* processing. As such it may play a role in misidentification syndromes. [2]

We present the case of a 77-year-old man with reduplicative paramnesia with a normal pressure hydrocephalus pattern which was not previously reported in the literature, beyond the right hemisphere lesions he presents.

Case Presentation

The patient was a 77-year-old man, married, currently retired (former taxi driver), diagnosed with type 2 diabetes mellitus, chronic kidney disease, arterial hypertension, hyperthyroidism and multiple myeloma, stable and treated with radio and chemotherapy. He has a history of 2 ischaemic strokes: the first located on the right cerebellar hemisphere (when he was 63 years old); the second located on the right occipital lobe (when he was 65 years old). No sequelae persisted after each event.

He had no known personal or family psychiatric history. He was observed for the first time by psychiatric services when he was 75 years old after exhibiting a delirium state characterized by confusion, disorientation, visual hallucinations and persecutory delusions following opioid and corticoid treatment related to the multiple myeloma. A brief iatrogenic condition was hypothesised and he was prescribed aripiprazole 10mg daily, which helped manage these symptoms.

In 2018 he was assessed again by the psychiatric services in our hospital, this time reporting he was certain that his neighbourhood, where he had been living for decades, had been duplicated for 2 years. He explained that, after being discharged from a short hospital admission due to a respiratory infection, he began to realize that his neighbourhood had been duplicated, including his own house. He reported that it was not his original home and he noticed it by observing details of the furniture and the house corners; according to the patient there were some minor differences. He did not know where the location of the original house was, which was of some concern to him. When asked why that had happened, he answered that the government might have created a replica of his house and the original place had been used as accommodation for refugees. The patient reported one episode, after awakening, when he had “surreal” feelings as if his car was flying and invading his room. At his psychiatric appointment he was informed about the impossibility of what he had perceived and he didn’t seem disturbed. No history otherwise compatible with seizure activity was reported.

His daughter also reported there were several episodes when she was trying to park her car in front of the patient’s house and he refused to enter in it, saying they needed to go to his original place. Sometimes his daughter simulated going out from the block and park the car in the exact same place, and he did not realize it. The patient did not to appear to be disturbed when he was confronted

by the fact that he was the only person thinking about the reduplication, as his wife and daughter denied it. Currently he is becoming gradually dependent on others for basic daily activities, such as preparing meals; managing money; going out for a walk alone and taking care of his personal hygiene.

Concomitantly with these psychopathological alterations, he started having urinary incontinence and difficulty walking, in small steps.

The neuropsychological assessment showed marked and moderate changes in executive functions, namely, planning, sequencing, divided attention, processing speed, semantic and phonological verbal fluency; also, marked to moderate changes in visuo-perceptive abilities were observed and, mild changes in the visuo-spatial ability. Interestingly, verbal memory and learning abilities seemed to be preserved. In particular, episodic memory was maintained for immediate recall and despite a minor loss of information in the long term free recall that should be reported, the patient recovered the information in cued recall (**Table 2**). [9-12]

Table 2. Neuropsychological assessment with tests results.

Domains	Tests	Scores	
Language	Token Test	17,5/22	Normal
Sustained Attention	Cancellation Task*	15/16	Normal
	Time	47s	Normal
Memória			
Word Delayed Recall	5 words*	12(15)	Normal
Associate Learning	Paired Associate Learning*	12(21)	Normal
Episodic Memory	Logical memory (immediate free recall)*	10	Normal
	Logical memory (delayed free recall)*	9	Normal
Semantic Memory	Information*	20/20	Normal
Visuo-perceptive abilities	WMS Figures*	3(15)	Severe
	Rey-Osterrieth Complex Figure	20/32	Severe
Visuo-constructional abilities	Cube copy*	1(3)	Mild
Visuo-Spatial abilities	Clock Drawing*	1(3)	Mild
Verbal Abstract Thought	Interpretation of Proverbs*	5(9)	Normal
Non-verbal abstract thought	Raven's Progressive Matrices*	6(12)	Mild
Executive Functions			
Working Memory	Digit span backwards*	2	Normal
Planning, sequencing , processing spead	Trail Making Test B	300s	Severe
Semantic Verbal Fluency	Food Products*	13(26)	Moderate
Phonological Verbal Fluency	Words_letters P, M, R*	3;2;3	Impaired
Cognitive Global Functionning	MMSE**	28/30	Normal
Depressive Symptomatology	GDS***	13/15	Severe
Behaviour, Personality and Daily Functioning	BLESSED (Blessed et al. 1968)	5,5 (3,5+2)	Impaired
	IADL (Lawton & Brody, 1969)	1	Impaired
Subjective Memory	SMCScale****	10(21)	

*

Tests part of BLAD, Bateria de Lisboa para Avaliação das Demências (Garcia, 1984)

** Mini-Mental State Examination, Portuguese version adapted from Guerreiro et al (1998)

*** Geriatric Depression Scale, Portuguese version adapted from Barreto et al (2008)

**** Subjective Memory Complaints Scale, Portuguese version adapted from Ginó et al (2007)

Laboratory Evaluation (1st Gerontopsychiatry appointment in Hospital de Santa Maria, 77 years old): Anemia (Hb 7,6g/dL; normochromic normocytic); PCR 8,64mh/dL; GGT 109U/L; TSH 25,2uU/mL and T4 0,82ng/dL; HIV, VDRL and hepatitis serologies were negative; folic acid and vitamin B12 normal.

CT scan of the brain showed a pattern of chronic ischemic leukoencephalopathy; small cortico-subcortical encephalomalacia foci, probable sequelae from previous ischaemic vascular lesions, namely on the right parietal convexity, in the anterior segment of the gyrus and in the right callosal commissure; pattern of diffuse cerebral atrophy, cortical and subcortical, with generalized sulcal enlargement, along the middle convexity and sylvian sulcus bilaterally; moderate ectasia of the supratentorial ventricular system with sulcal attenuation in the high convexity and sulcal ectasia in middle convexity and sylvian fissures bilaterally, this pattern being suggestive of normal pressure hydrocephalus (NPH).

Brain MRI with CSF dynamics revealed several intense periventricular, subcortical and bihemispheric white matter hyperintense foci, which suggest probable chronic microvascular disease. Small right occipital vascular sequelae with adjacent hematic residues. Coexistence of a small right cerebellar hemisphere vascular sequelae. Supratentorial ventricular system ectasia, which seems proportional to the bi-hemispheric sulcal ectasia. An important void in the aqueduct of Sylvius was verified, which suggests hyperdinamic CSF flow, commonly seen in NPH (**Image 1 and 2**).

Image 1

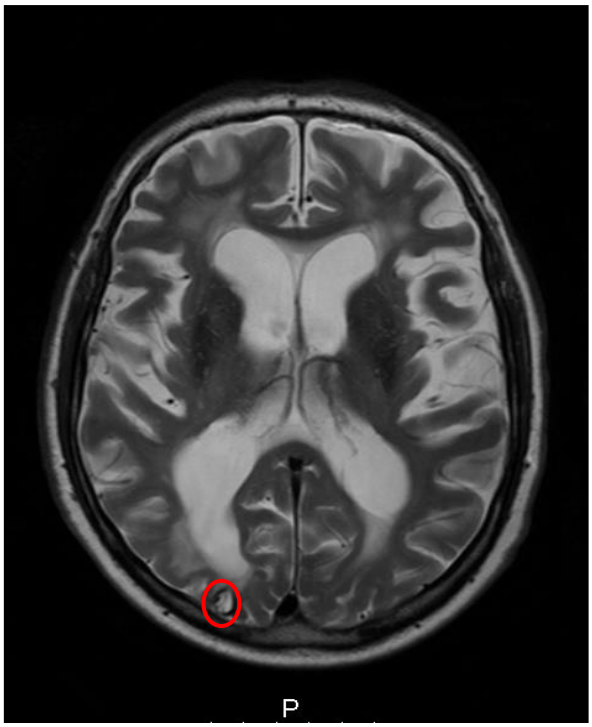

Axial sT2 - Ischaemic lesion located in the right occipital lobe and lateral ventricles enlargement

Image 2

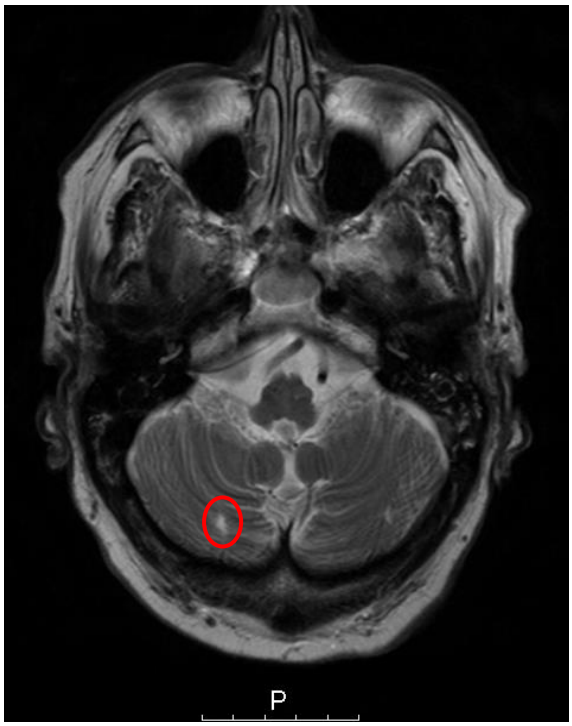

Axial sT2 – Ischaemic lesion located in the right cerebellar hemisphere

The patient was referred to Neurology and Neurosurgery for treatment.

Discussion

RP has been associated with a variety of neurologic disorders, most commonly lesions on the right hemisphere and/or frontal (including bi-frontal) lobes. Herein is reported a case of RP in which neuroimaging findings showed right hemisphere vascular lesions, but in occipital and cerebellar topography.

A dual mechanism is postulated for the delusional misidentification syndromes, such as RP: negative effects from right hemisphere and frontal lobe dysfunction as well as positive effects from release (i.e., overactivity) of preserved left hemisphere areas. Negative effects of right hemisphere lesions impair self-monitoring, establishment of Self boundaries, and attaching emotional valence and familiarity to stimuli. The unchecked left hemisphere unleashes a creative narrator from the monitoring of Self, memory, and reality by the frontal and right hemisphere areas, leading to false explanations. Furthermore, the left hemisphere's cognitive style of categorization, often into dual categories, leads it to invent a duplicate or impostor to resolve conflicting information. Delusions seem to result from right hemisphere lesions, but it is the left hemisphere that is deluded. This explains why content-specific delusions involve people, places, or things of personal significance and distort their relation to the Self. [13] So in the case of our patient, the left hemisphere recognizes "this is my home", but fails to receive other information (sparkle of familiarity, global gestalt, and relation to Self) and concludes that "this is not my home". The conflict is resolved with the fabrication of a duplicate. "It looks like my home, but it really is not my home".

We did not find any report of RP relating to an occipital lesion, but a theoretical explanation might be elaborated, based on recent findings. Tractography evidence confirms that visually specialized cortical areas are connected by two parallel pathways: 1) the ventral-lateral parieto-frontal U-shaped fibres; and 2) the direct occipito-temporal pathway or inferior longitudinal fasciculus (ILF), connecting pre-striate cortex to medial temporal structures (the hippocampus, parahippocampal gyrus, and amygdala). It is possible that the direct occipito-temporal pathway relates to emotional visual memory. [14] Furthermore, the superior longitudinal fasciculus (SLF; connecting the visual parietal lobe and frontal cortex) and the inferior fronto-occipital fasciculus (IFOF; connecting areas in the occipital lobe and ventral frontal lobe) are likely to relate to functions such as visual working memory and visual attention. RP can be considered a type of disorder where these pathways are disturbed, leading to a disconnection of visual and affective or memory regions. [15-17]. It would be interesting to study these cases with Diffusion Tensor Imaging (DTI), to demonstrate whether damage exists to specific tracts carrying reciprocal connections between the occipital lobe, the hippocampus, the amygdala and the frontal lobe.

This case also illustrates the co-occurrence of RP with HPN, which the authors did not find described in the previously published literature. Not only did the patient exhibit the HPN classic triad of urinary incontinence, gait ataxia and cognitive decline, but the neuroimaging supported this diagnosis, showing supratentorial ventricular system ectasia and sulcal attenuation. Although RP and HPN may be separate and independent phenomena occurring in the same patient, the cognitive decline afforded by the HPN may have had a synergistic role in the development of RP.

The neuropsychological assessment revealed significant executive dysfunction and alterations in visuospatial capacities, which is congruent with what has been previously hypothesized and observed in the small extent of literature on RP. [18]

Conclusions

This case adds to the observational literature on RP phenomena, particularly in terms of clinical presentation, detailed neuroimaging and neuropsychological findings obtained.

This patient's profile is consistent with right hemisphere involvement, but not specifically frontal, as he had two right hemisphere infarctions located in occipital and cerebellar areas. Another hallmark of this case report is the hypothetical association between the pattern suggestive of HPN and RP, which is a new descriptive element in this rare and very incompletely understood phenomena. As far as we know, HPN has not been associated with RP, but this patient did present with the typical clinical triad of the former entity (urinary incontinence, gait apraxia and cognitive decline) as well as RP. Thus, in this case RP could be an unusual symptom of HPN, an association which in the authors' perspective merits further study.

An explanation for RP that relies on reducing the complexity of the phenomena observed to the effects of localization associated with a single focal lesion is likely insufficient. Further, while damage may occur specifically with the frontal lobe in many, if not most, cases of RP, more broadly the disruption of pathways associated with the right frontal lobe may be necessary thought not sufficient.

The authors emphasize that the presence of delusions does not necessarily mean a psychiatric condition, even more so when the patient is elderly, has no psychiatric prior history and has no first-rank symptoms, such as third-person auditory hallucinations, delusions of thought interference and passivity phenomenon.

References

Arisoy O, Tufan A, Bilici R, et al. The comorbidity of Reduplicative Paramnesia, Intermetamorphosis, Reverse-Intermetamorphosis, Misidentification of Reflection, and Capgras Syndrome in an Adolescent Patient. Hindawi Publishing Corporation Case Reports in Psychiatry, volume 2014, Article ID 36080, 3 pages.

Pick A. Clinical studies: III. On reduplicative paramnesia. 1903; Brain 26, 260-267.

Politis M, Loane C. Reduplicative Paramnesia: A Review. Psychopathology. 2012; 45:337-343.

Ardila A. Some unsusal neuropsychological syndromes: somatoparaphrenia, akinetopsia, reduplicative paramnesia, autotopagnosia. Arch. Clin. Neuropsychol. 2016; 31 (5), 456-464.

Anderson CA, Filley CM. Dual misidentification syndromes: progress and new challenges. J. Neuropsychiatry Clin. Neurosci. 2016; 28(3), 160-161.

Benson DF, Gardner H, Meadows JC. Reduplicative paramnesia. Neurology. 1976; 26(2), 147-151.

Darby R, Prasad S. Lesion-related delusional misidentification syndromes: a comprehensive review of reported cases. J. Neuropsychiatry Clin. Neurosci. 2016; 28(3), 217-222.

Spiegel D, Cadacio K, Kiamanesh M. A probable case of reduplicative paramnesia status-post right fronto-temporal cerebrovascular accident, treated sucessfully with risperidone. J Neuropsychiatry Clin Neurosci. Winter. 2014; 26:1.

Garcia C. Doença de Alzheimer, problemas do diagnóstico clínico. Tese de Doutoramento. Faculdade de Medicina de Lisboa. 1984

Guerreiro M. Contributo da Neuropsicologia para o Estudo das Demências. Dissertação e Doutoramento em Ciências Biomédicas, Faculdade de Medicina de Lisboa. 1998

Barreto J, Leuschner A, Santos F et al. Geriatric Depression Scale (GDS). In Escalas e Testes na Demência, Mendonça A, Guerreiro M, eds. Grupo de Estudos de Envelhecimento Cerebral e Demências, 3rd edition, Lisboa, 2008; pp 71-72.

Ginó, S, Guerreiro M, Garcia C. (2008). Subjective memory complaints. Tests and Scales in Dementia. Dementia and Cerebral Aging Study Group, 2nd Edition Portugal; 2008.

Devinsky O. Delusional misidentifications and duplications; right brain lesions, left brain delusions. Neurology 2009; 72:1-1.

Catani M, Jones DK, Donato R, et al: Occipito-temporal connections in the human brain. Brain 2003; 126:2093-2107.

Ffytche DH, Blom JD, Catani M: Disorders of visual perception. J Neurol Neurosurg Psychiatry 2010; 81:1280-1287.

Soldan A, Mangels JA, Lynn A: Effects of dividing attention during encoding on perceptual priming of unfamiliar visual objects. Cooper Memory 2008; 16:873-895.

Catani M, Ffytche DH: The rises and falls of disconnection syndromes. Brain 2005; 128:2224-2239.

Nelson D. Reduplicative Paramnesia: A neuropsychological case analysis. Neuropsychiatry (London), 2017, 7(3), 274-280.

Transnasal Sphenopalatine Ganglion Block in Postdural Puncture Headache

Bloqueio do Gânglio Esfeno-palatino na Cefaleia Pós-punção da Dura

Onassis Silva[1], Mariana Alves [1, 2] ,Teresa Fonseca[1, 2]

[1] Medicina III, Hospital Pulido Valente, Centro Hospitalar Lisboa Norte, [2] Faculdade de Medicina da Universidade de Lisboa

Abstract

Postdural puncture headache (PDPH) is an iatrogenic condition following puncture of the dura and is manifested by intense headache that aggravates with standing. Currently, the treatment offered passes through the conservative approach or epidural blood-patch, however, sphenopalatine ganglion block (SPGB) has been shown to be effective in these situations.

The authors present the case of a young female patient who presented with PDPH following a diagnostic lumbar puncture. After failure of conservative treatment, SPGB was performed. The procedure was uneventful and effective. However, after 30 minutes the patient presented as an adverse effect a transitory episode of intense vertigo, being unable to walk, but recovered completely 2 hours later.

The authors intend to highlight the efficacy of this therapeutic approach, as well as to alert to its adverse effects that must be known and anticipated to the patient.

Keywords: Sphenopalatine ganglion block; Postdural puncture headache; Lumbar puncture; Analgesia.

Resumo:

A cefaleia pós-punção da dura (CPPD) é um quadro iatrogénico subsequente a punção da dura-máter e manifesta-se por cefaleia intensa que agrava com o ortostatismo. Atualmente, o tratamento oferecido passa pela abordagem conservadora ou *blood-patch* epidural, no entanto, o bloqueio do gânglio esfeno-palatino (BGEP) tem-se revelado eficaz nestas situações.

Os autores apresentam o caso de uma doente jovem do sexo feminino que apresentou um quadro de CPPD na sequência de punção lombar diagnóstica. Após insucesso do tratamento conservador, foi realizado o BGEP. O procedimento decorreu sem intercorrências imediatas, tendo sido eficaz no desaparecimento da cefaleia. No entanto, ao fim de 30 minutos, a doente apresentou como efeito adverso um quadro vertiginoso intenso com limitação da marcha que durou cerca de 2h, ficando posteriormente assintomática.

Os autores pretendem destacar a eficácia desta abordagem terapêutica, bem como alertar para os seus efeitos adversos que devem ser conhecidos e antecipados ao doente.

Palavras-chave: Bloqueio do gânglio esfeno palatino; Cefaleia pós-punção da dura; Punção lombar, Analgesia.

Introdução

A cefaleia pós-punção da dura (CPPD) é uma complicação comum após punção lombar diagnóstica ou terapêutica, ocorrendo em 30-40% dos casos. [1-3] É também frequente após procedimentos anestésicos (ex. raquianestesia), podendo também ocorrer como iatrogenia após punção acidental da dura, durante a anestesia epidural. [4,5] Em Portugal, a incidência de punção acidental da dura foi estimada em 0.3% em doentes obstétricas. [6] Apesar de na literatura a incidência variar de 1 a 80% nesta mesma população. [6] A ocorrência desta entidade clínica varia de acordo com o calibre e tipo da agulha usada, idade e género do doente, sendo mais frequente em mulheres jovens. [5-7]

O quadro clínico habitual geralmente manifesta-se como cefaleia frontal e occipital intensa, que agrava com ortostatismo e alivia com decúbito, começando nos primeiros três dias após punção da dura. [5,8] A abordagem terapêutica da CPPD divide-se numa abordagem conservadora (repouso no leito, hidratação forçada, bebidas com cafeína, analgésicos e/ou anti-inflamatórios não esteróides), ou num procedimento invasivo denominado *blood-patch* epidural (placa de sangue epidural) com sangue autólogo. [5,6,8-10] Este procedimento é atualmente o tratamento padrão após insucesso das medidas conservadoras, no entanto não está isento de riscos significativos como meningite, convulsões, défices motores e sensoriais, entre outros. [5-7,9,10]

O bloqueio do gânglio esfenopalatino (BGEP) no tratamento da CPPD foi inicialmente descrito em 2001 por Cohen *et al*. [11] Posteriormente, vários autores publicaram casos e séries de casos sobre este procedimento. [5,10,12,13] Em Portugal alguns centros também já publicaram resultados favoráveis na utilização desta técnica na CPPD. [5,9,12]

Os autores apresentam o caso de uma doente com CPPD após punção lombar diagnóstica, sem melhoria com medidas conservadoras e resolução imediata da cefaleia com a realização do BGEP.

Caso clínico

Doente do sexo feminino, 33 anos de idade, previamente saudável, medicada em SOS com Nimesulide por cefaleias ocasionais. Foi observada em Hospital Dia Polivalente por quadro de dormência desde a cintura até aos pés bilateralmente, incluído a região perineal, de igual intensidade nas várias regiões. Da história clínica destaca-se ainda episódio isolado de incontinência urinária e viagem recente ao Brasil em trabalho. Nega alterações da força, descoordenação, dor lombar ou dor irradiada, nega episódios prévios semelhantes. Nega infeções recentes. À observação apresentava hemihipostesia álgica, com nível em D8, envolvendo a região perineal, hipostesia vibratória até aos joelhos bilateralmente. Sem alterações da força muscular, sensibilidade propriocetiva, reflexos osteo-tendinosos ou cutâneo-plantares. Por suspeita de mielite, foi encaminhada para o Serviço de Urgência Central para avaliação por neurologia. Esteve internada durante 7 dias, tendo realizado estudo analítico, imagiológico e potenciais evocados. O estudo imagiológico revelou lesão desmielinizante a nível de D3. Procedeu-se a punção lombar diagnóstica com agulha Quincke, calibre 20G, que se revelou traumática à primeira tentativa, com necessidade de repetição. O líquido cefaloraquidiano não apresentou alterações citobioquimicas, sendo os

restantes exames microbiológico e serológicos negativos, bem como o restante estudo etiológico. Foi medicada com metilprednisolona durante 5 dias, sem melhoria da hipostesia. Ao segundo dia após a punção lombar diagnóstica, inicia um quadro de cefaleia, desvalorizado e assumido pela doente como resultante da ansiedade gerada pelo internamento hospitalar. Teve alta com diagnóstico de mielite dorsal, encaminhada para a consulta de doenças desmielinizantes, medicada com pregabalina.

Por manutenção em ambulatório do quadro de cefaleia, a doente recebeu indicação posterior para manter repouso, realizar reforço hídrico, analgesia de esquema e ingesta de bebidas com cafeína. Uma semana após a alta (8 dias após a realização da punção lombar), foi novamente avaliada em Hospital Dia onde referia manutenção do quadro de cefaleia apesar do cumprimento da terapêutica instituída. Referia cefaleia occipital durante o ortostatismo, ficando assintomática em decúbito, sem défice neurológico de novo, náuseas ou vómitos. Foi contactado o serviço de anestesia, que colocou à consideração da doente a hipótese de realização de uma abordagem mais invasiva para o tratamento da CPPD, como o bloqueio esfeno-palatino ou *blood-patch* epidural, tendo a doente optado pela primeira opção.

O procedimento foi realizado com recurso a dois aplicadores com ponta de algodão, embebidos em lidocaína 1%. Os aplicadores (um para cada narina), foram introduzidos um de cada vez, paralelamente ao pavimento do nariz e avançados até sentir resistência, sendo mantidos nesta posição durante 10 minutos (Figura 1). O BGEP decorreu sem intercorrências, à exceção de sabor amargo na boca que tinha sido previamente antecipado. Após remoção dos aplicadores a doente realizou levante, não referindo já qualquer cefaleia. No entanto, cerca de 30 minutos após o procedimento, iniciou quadro vertiginoso intenso com limitação da marcha, sem náuseas ou vómitos ou outro défice neurológico associado. Manteve-se em repouso, tendo apresentado melhoria progressiva dos sintomas em duas horas. Assumiu-se, portanto, quadro de iatrogenia associada ao procedimento realizado. Posteriormente não houve recorrência do quadro de cefaleia nem do quadro vertiginoso.

Figura 1 - Doente com aplicadores de algodão durante a realização de bloqueio de gânglio esfeno-palatino

A doente mantém seguimento habitual em consulta com vigilância semestral, apresentando melhoria da hipostesia.

Discussão

O presente caso clínico pretende alertar para dois pontos principais: (1) BGEP é um procedimento simples, de fácil realização e eficaz, mas que como todos os procedimentos, não está isento de complicações; (2) o quadro vertiginoso é um efeito adverso possível, mas raramente reportado na literatura.

O BGEP é habitualmente indicado como terapêutica nos casos de dor facial aguda e/ou crónica, entre as quais a enxaqueca, nevralgia do trigémeo, dor facial atípica, dor associada à cancro da cabeça e do pescoço bem como em outras síndromes de algias cefálicas. [4,10,12,14]

Os efeitos adversos descritos após a realização do BGEP são tipicamente locais (Tabela 1). Não há relatos de complicações graves associadas a esta técnica, no entanto, alguns dos efeitos adversos ocasionalmente reportados são hemorragia ligeira devido à introdução traumática do aplicador, dormência e desconforto nasofaríngeo inicial, relacionados com a disseminação do anestésico. [12,14]

Tabela 1 - Efeitos adversos mais frequentes no BGEP realizado por CPPD. [10,13,15]

Desconforto nasal
Dormência do nariz, palato e garganta
Dormência ocular ipsilateral
Lagrimejo ipsilateral
Náusea
Sensação de sabor amargo
Sangramento nasal
Vómitos

Apenas num estudo sobre esta técnica anestésica em doentes com quadro clínico de enxaqueca, o quadro vertiginoso foi descrito como efeito adverso (em 11% dos doentes). [7] No entanto, este efeito adverso não foi mencionado em vários outros estudos (casos clínicos, séries de casos e ensaios clínicos) realizados no âmbito da CPPD. [9,10,12,13,15–17]

Todos os efeitos adversos reportados na literatura foram transitórios e duraram menos de 24 horas. [12,15]

Relativamente à cefaleia pós-punção da dura é importante notar que embora a resolução da lesão da dura-máter seja um processo espontâneo que geralmente leva menos de sete dias até a sua resolução, este procedimento analgésico permite que o paciente tenha uma recuperação mais

rápida, com raros efeitos adversos. [12] O objetivo desta técnica é o alívio sintomático, por isso, vale a pena ressaltar que o bloqueio não altera a produção ou a circulação de fluidos cerebrais, a sua ação analgésica é devido ao bloqueio trigeminal e parassimpático, alterando assim o tónus do vaso meníngeo e a transmissão da nocicepção. [12] Várias abordagens anatómicas são empregues num esforço de anestesiar o gânglio esfenopalatino, cada uma tem potenciais complicações e desafios técnicos. Existem três tipos principais de abordagem para a realização do BGEP: via transnasal, transoral e infrazigomatica, sendo a via transnasal a mais comummente usada por ser a mais simples e menos invasiva. [12,13,18] Quanto ao fármaco a lidocaína e a bupivacaina são os anestésicos mais usados [10,13,16], embora estudos portugueses utilizem ropivicaína e levobupivacaína a 0,5%. [5,12]

No caso da CPPD, o BGEP é feito pela via transnasal. É uma técnica de abordagem simples que pode ser realizada nas enfermarias à cabeceira do doente, no serviço de urgência e em contexto de ambulatório, com a particularidade de poder ser executada por médicos não anestesiologistas. [4,10] O doente deve estar em posição supina, com ligeira extensão cervical. Dois aplicadores com ponta de algodão devem ser embebidos na quantidade e tipo de anestésico determinado e introduzidos de forma rápida, mas suave, até a parede posterior de ambas as narinas. O aplicador deve permanecer por cerca de 5-10 minutos dentro de cada narina, não entrando em contacto direto com o gânglio. No entanto, o anestésico local infiltra o tecido conjuntivo e o revestimento da membrana mucosa, em toda a região em torno dele facilitando a disseminação e a penetração do fármaco. [4,12]

Alguns estudos sugerem que pela facilidade de aplicação seria até possível ensinar os doentes como fazer auto-realização da técnica em ambulatório, como terapia adjuvante no tratamento da dor cronica em diversas patologias e assim melhorar a sua qualidade de vida. [10,12-14,16]

O BGEP é atualmente alvo de intensa investigação científica no âmbito de ensaios clínicos, que pretendem reafirmar a sua eficácia e demonstrar a sua primazia relativamente a outras abordagens terapêuticas. Dentro de alguns meses/anos, provavelmente será consensual a realização precoce desta terapêutica em detrimento de uma abordagem conservadora que é pouco eficaz ou o *blood-patch* epidural que é um procedimento invasivo que embora eficaz acarreta maiores riscos. [8-10,16,17]

Conclusão

O BGEP tem mostrado ser uma técnica interessante de auxílio no tratamento da CPPD, também para médicos não anestesiologistas, uma vez que se trata de técnica simples, com raros efeitos adversos e que pode ser realizada à cabeceira do doente. Apesar de todas as vantagens referidas, a evidência atual ainda é parca e dispersa, sendo importante aguardar por estudos robustos que confirmem os resultados favoráveis demostrados em casos isolados e séries.

Referências

1. Evans RW. Complications of lumbar puncture. *Neurol Clin*. 1998;16(1):83-105. doi:10.1016/S0733-8619(05)70368-6.
2. Ahmed S V., Jayawarna C, Jude E. Post lumbar puncture headache: Diagnosis and management. *Postgrad Med J*. 2006;82(973):713-716. doi:10.1136/pgmj.2006.044792.
3. Roos KL. Lumbar puncture. *Semin Neurol*. 2003;23(1):105-114. doi:10.1055/s-2003-40758.
4. Nair AS, Rayani BK. Sphenopalatine ganglion block for relieving postdural puncture headache: Technique and mechanism of action of block with a narrative review of efficacy. *Korean J Pain*. 2017;30(2):93-97. doi:10.3344/kjp.2017.30.2.93.
5. Cardoso JM, Sá M, Graça R, et al. Bloqueio do gânglio esfenopalatino para cefaleia pós-punção dural em contexto de ambulatório. *Brazilian J Anesthesiol*. 2017;67(3):311-313. doi:10.1016/j.bjan.2017.02.003.
6. Antunes MV, Moreira A, Sampaio C, Faria A. Punção acidental da dura e cefaleia pós-punção da dura na população obstétrica: Oito anos de experiência. *Acta Med Port*. 2016;29(4):268-274. doi:10.20344/amp.6815.
7. Kent S, Mehaffey G. Transnasal sphenopalatine ganglion block for the treatment of postdural puncture headache in obstetric patients. *J Clin Anesth*. 2016;34:194-196. doi:10.1016/j.jclinane.2016.04.009.
8. Channabasappa SM, Manjunath S, Bommalingappa B, Ramachandra S, Banuprakash S. Transnasal sphenopalatine ganglion block for the treatment of postdural puncture headache following spinal anesthesia. *Saudi J Anaesth*. 2017;11(3):362-363. doi:10.4103/sja.SJA_59_17.
9. Gonçalves LM, Godinho PM, Durán FJ, Valente EC. Sphenopalatine ganglion block by transnasal approach in post-dural puncture headache. *J Clin Anesth*. 2018;48(May):50. doi:10.1016/j.jclinane.2018.05.006.
10. Kent S, Mehaffey G. Transnasal sphenopalatine ganglion block for the treatment of postdural puncture headache in the ED. *Am J Emerg Med*. 2015;33(11):1714.e1-2. doi:10.1016/j.ajem.2015.03.024.
11. Cohen S, Trnovski S, Zada Y. A new interest in an old remedy for headache and backache for our obstetric patients: a sphenopalatine ganglion block. *Anaesthesia*. 2001;56(6):606-607.
12. Furtado I, Lima IF de, Pedro S. Uso de ropivacaína em bloqueio do gânglio esfenopalatino via transnasal para cefaleia pós-punção dural em pacientes obstétricas - série de casos. *Brazilian J Anesthesiol*. 2018;(xx). doi:10.1016/j.bjan.2017.11.007.
13. Ho KWD, Przkora R, Kumar S. Sphenopalatine ganglion: block, radiofrequency ablation and neurostimulation - a systematic review. *J Headache Pain*. 2017;18(1). doi:10.1186/s10194-017-0826-y.
14. Sanghavi PR, Shah BC, Joshi GM. Home-based Application of Sphenopalatine Ganglion Block for Head and Neck Cancer Pain Management. *Indian J Palliat Care*. 2017;23(3):282-286. doi:10.4103/IJPC.IJPC_39_17.
15. Schaffer JT, Hunter BR, Ball KM, Weaver CS. Noninvasive Sphenopalatine Ganglion Block for Acute Headache in the Emergency Department: A Randomized Placebo-Controlled Trial. *Ann Emerg Med*. 2015;65(5):503-510. doi:10.1016/j.annemergmed.2014.12.012.
16. Cohen S, Sakr A, Katyal S, Chopra D. Sphenopalatine ganglion block for postdural puncture headache. *Anaesthesia*. 2009;64(5):574-575. doi:10.1111/j.1365-2044.2009.05925.x.
17. Cohen S, Ramos D, Grubb W, Mellender S, Mohiuddin A, Chiricolo A. Sphenopalatine ganglion block: a safer alternative to epidural blood patch for postdural puncture headache. *Reg Anesth Pain Med*. 2014;39(6):563. doi:10.1097/AAP.0000000000000172.
18. Binfalah M, Alghawi E, Shosha E, Alhilly A, Bakhiet M. Clinical Study Sphenopalatine Ganglion Block for the Treatment of Acute Migraine Headache. 2018;2018. doi:10.1155/2018/2516953.

Agradecimentos

Dr. Pedro Gomes (anestesiologista) pela realização da técnica de bloqueio do gânglio esfeno-palatino.

Tuberculosis or Atypical Mycobacterial Infection: About a Case in a Health-Care Worker

Tuberculose ou Infeção por Micobactérias Atípicas: a Propósito de um Caso num Profissional de Saúde

Diana França[1], Gary Morales[1], Clara Fernandes- Almeida[1], Ema Sacadura-Leite[1,2]

[1] Serviço de Saúde Ocupacional, Centro Hospitalar Lisboa Norte, Lisboa, Portugal, [2] CISP. Escola Nacional de Saúde Pública da Universidade NOVA de Lisboa, Lisboa, Portugal

Abstract

Atypical mycobacterial infections occur more frequently in people with structural lung diseases such as bronchiectasis, emphysema, and sequelae of pulmonary tuberculosis (TB). *M.kansasii* is one of the most common species causing atypical micobacteriosis and has a clinical presentation which is very similar to TB. We describe the case of a 65-year-old physician with a personal history of smoking, bronchiectasis, pulmonary emphysema, and childhood pulmonary TB. The physician came to the Occupational Health Service because of symptoms suggestive of TB. Even though he had no recent history of significant unprotected exposure to *M.tuberculosis*, it was notified as an occupational disease, due to the increased risk associated with his profession. After the result of the sputum culture, which was positive for *M.kansasii*, the notification was withdrawn, since this microorganism is not transmitted between humans and isn't associated with occupational exposure.

Keywords: Nontuberculous Mycobacterium Infections, *Mycobacterium kansasii*, pulmonary tuberculosis, occupational diseases

Resumo

As infeções por micobactérias atípicas ocorrem mais frequentemente em pessoas com doenças que afetam a estrutura do tecido pulmonar, nomeadamente bronquiectasias, enfisema e sequelas de tuberculose pulmonar (TP). A *M.kansasii* é um dos agentes mais frequentes e causa um quadro clínico muito semelhante ao da TP. Descreve-se o caso de um médico, de 65 anos de idade, com antecedentes pessoais de tabagismo, bronquiectasias, enfisema pulmonar, TP na infância, que recorre ao Serviço de Saúde Ocupacional por quadro clínico, analítico e imagiológico sugestivo de TP. Mesmo não tendo conhecimento de exposição não protegida significativa ao *M.tuberculosis,* mas sim pelo risco acrescido associado à sua profissão, foi realizada a notificação de doença profissional. Após o resultado do exame cultural, que foi positivo para *M.kansasii*, a notificação acabou por ser retirada, uma vez que este microrganismo não se transmite entre humanos e não está associado à exposição profissional.

Palavras-chave*:* Micobacterioses Atípicas, *Mycobacterium kansasii*, Tuberculose pulmonar, doenças profissionais

Introdução

A *Mycobacterium kansasii* é uma das principais causas de infeção pulmonar por micobactérias não-tuberculosas em doentes imunocompetentes, tanto em Portugal como no resto do mundo ocidental. [1-3]

A infeção por *M.kansasii*, assim como no caso de outras micobactérias atípicas, é mais frequente em pessoas com doenças que afetam a estrutura do tecido pulmonar, como DPOC, bronquiectasias ou sequelas de tuberculose pulmonar, neoplasias das vias respiratórias (laringe, traqueia e brônquios), alterações da caixa torácica, artrite reumatoide e uso de imunossupressores, entre outras.[3,4]

A transmissão da micobacteriose a *M.kansasii* não ocorre por via aérea entre humanos, mas sim por aerossolização de água contaminada. Ao contrário de outras micobactérias que contaminam o solo e águas não tratadas, a *M.kansasii* é mais frequente na água canalizada e é frequentemente resistente ao tratamento da mesma com desinfetantes como as soluções contendo cloro.[3-5]

A doença tem uma apresentação clínica, analítica e radiológica muito semelhante à da tuberculose pulmonar (TP), pelo que as duas podem ser confundidas, exigindo confirmação microbiológica para o seu diagnóstico diferencial. [4,5] A distinção entre estas duas entidades é importante devido às diferenças na terapêutica, uma vez que a infeção por *M.kansasii* exige tratamento prolongado com Etambutol.[5]

Caso Clínico

Homem de 65 anos, médico, ex-fumador (carga total de 16 UMA), com antecedentes pessoais de bronquiectasias e enfisema pulmonar, história de pneumonia em 2010 e primo-infeção tuberculosa na infância.

Recorre ao Serviço de Saúde Ocupacional (SSO) em Janeiro de 2014 por quadro de emagrecimento, sudorese noturna, febre vespertina e tosse com expetoração purulenta, com cerca de um mês de evolução.

Analiticamente apresentava elevação dos parâmetros inflamatórios:

- Leucocitose com neutrofilia, com 16990 leucócitos/L e 80,1% de neutrófilos;
- Trombocitose, com 556000 plaquetas/L;
- Velocidade de sedimentação de 110 mm;
- Proteína C reativa de 21,6 mg/dL.

A radiografia do tórax evidenciava hipotransparência heterogénea bilateral, mais acentuada na metade superior do campo pulmonar esquerdo, onde se verificam imagens sugestivas de cavitação.

O exame direto da expetoração revelou a existência de muitos bacilos álcool-ácido resistentes (BAAR).

Apesar de não existir história de exposição significativa, assumiu-se o diagnóstico de tuberculose pulmonar profissional, pelo risco geral acrescido associado à profissão de médico, pelo que foi notificada a doença profissional ao Instituto de Segurança Social (ISS). O paciente foi

encaminhado para o Centro de Diagnóstico Pneumológico (CDP), foi afastado temporariamente do trabalho e iniciou terapêutica com Rifampicina, Isoniazida, Etambutol e Pirazinamida. O SSO adotou as medidas protocoladas para rastreio de contactos com *M.tuberculosis*, relativamente aos seus colegas de trabalho.

Em Fevereiro 2014 o resultado da reação em cadeia da polimerase (PCR) para *M.tuberculosis* revelou-se negativo e o exame cultural isolou *M.kansasii*.

De salientar que, só nesta altura, o trabalhador relembrou e referiu ter tido, dois anos antes, uma suspeita de infeção urinária e prostatite por micobactéria atípica.

O doente manteve terapêutica antibacilar tripla (Rifampicina, Isoniazida e Etambutol) durante um total de doze meses. Dois meses depois do início do tratamento o exame cultural da expetoração negativou e o profissional regressou ao trabalho em Julho 2014.

O Centro Nacional para a Proteção contra os Riscos Profissionais do ISS foi informado da situação e a notificação da doença profissional indeferida.

Discussão

A prevalência de infeções pulmonares por micobactérias atípicas tem vindo a aumentar em muitos países sendo que, num estudo português recente, este tipo de bactérias foram isoladas nas secreções respiratórias de 11% dos pacientes com doença pulmonar crónica acompanhados num centro especializado em Lisboa. [2,4]

Apesar das infeções por *Mycobacterium tuberculosis* e por micobactérias atípicas apresentarem um quadro clínico semelhante, [4-6] a tuberculose pulmonar (TP) continua a ter um peso maior na morbilidade de doentes, devido à sua maior incidência. [5] Assim, é frequentemente a primeira hipótese diagnóstica perante a presença de BAAR nas secreções respiratórias.

Para o diagnóstico diferencial é então imprescindível o exame cultural, sendo que a micobacteriose atípica é confirmada quando existem:

- Duas culturas de expetoração consecutivas positivas; ou
- Uma cultura colhida por broncofibroscopia positiva; ou
- Uma cultura de expetoração positiva em doente com clínica compatível (como no caso em análise).[5]

Pelos motivos referidos anteriormente, no caso descrito, a TP foi a primeira suspeita do médico do trabalho perante o quadro clínico apresentado e tendo em conta que o doente tinha antecedentes de tuberculose na infância.[5] Só posteriormente à obtenção do resultado do exame cultural, foi possível valorizar que, de facto, o doente tinha fatores de risco tipicamente descritos em doentes infetados por *M.kansasii*. Tratava-se de um ex-fumador, com enfisema pulmonar e bronquiectasias. Por outro lado, só após a confirmação diagnóstica nos foi referida a história de uma infeção urinária e prostatite a microbactéria atípica, que dois anos antes teria motivo internamento.

Relativamente à declaração da doença profissional, uma vez que a TP consta na lista portuguesa de doenças profissionais (Decreto-Regulamentar n.º 76/2007, de 17 de Julho), e tratando-se de um profissional de saúde, assume-se um risco geral acrescido pelo que não é necessário demonstrar o nexo de causalidade entre uma exposição específica no local de trabalho

e a doença.[7,8] Após a confirmação diagnóstica de infeção a *M.kansasii* através do exame cultural, deixou de existir base para a presunção da doença profissional. Como já referido, a transmissão deste microrganismo não ocorre entre humanos, mas sim por aerossolização de água canalizada, pelo que não era possível fundamentar uma relação da doença com a atividade profissional.[3-5] Vários estudos da década de setenta avaliaram a possível associação entre infeção por *M.kansasii* e trabalho. Estes estudos centram-se em trabalhadores expostos a poeiras, designadamente antigos operadores de locomotivas a carvão e todos concluíram que o aumento da prevalência nesta população se deve ao maior número de casos de pneumoconioses e não diretamente à exposição ocupacional.[9-11]

O diagnóstico diferencial é fundamental uma vez que a infeção por *M.kansasii* não exige rastreio de contactos nem quimioprofilaxia, não havendo transmissão entre humanos.[6]

O tratamento de primeira linha da infeção a *M.kansasii* consiste em terapêutica antibacilar tripla com Isoniazida, Rifampicina e Etambutol durante doze meses.[5]

Conclusão

Concluindo, tendo em conta o crescimento recente da prevalência de infeções por micobactérias atípicas, este diagnóstico diferencial deve ser considerado em doentes com quadro clínico sugestivo de TP, com fatores de suscetibilidade individual específicos e sem história de exposição significativa a *M.tuberculosis*. A confirmação diagnóstica por PCR ou exame cultural é fundamental para se proceder à notificação de tuberculose profissional em trabalhadores da saúde.

Referências

1. Johnston JC, Chiang L, Elwood K. Mycobacterium kansasii. Microbiol Spectr. 2017;5(1): TNMI7-0011-2016.
2. Dabó H, Santos V, Marinho A, Ramos A, Carvalho T, Ribeiro M, Amorim A. Micobactérias não tuberculosas em espécimes respiratórios: significado clínico em um hospital terciário no norte de Portugal. J Bras Pneumol. 2015; 41(3): 292–294.
3. Prevots DR, Marras TK. Epidemiology of human pulmonary infection with nontuberculous mycobacteria: a review. Clin Chest Med. 2015;36(1):13-34.
4. Stout JE, Koh WJ, Yew WW. Update on pulmonary disease due to non-tuberculous mycobacteria. Int J Infect Dis. 2016;45:123-34.
5. Evans SA, Colville A, Evans AJ, Crisp AJ, Johnston ID. Pulmonary Mycobacterium kansasii infection: comparison of the clinical features, treatment and outcome with pulmonary tuberculosis. Thorax. 1996;51(12):1248-52.
6. Evans AJ, Crisp AJ, Hubbard RB, Colville A, Evans SA, Johnston ID. Pulmonary Mycobacterium kansasii infection: comparison of radiological appearances with pulmonary tuberculosis. Thorax. 1996;51(12):1243-7.
7. Direcção-Geral da Saúde. Vigilância da Tuberculose nos Profissionais de saúde. Orientação nº 010/2014 da DGS. 2014.
8. Ministério do trabalho e da Solidariedade Social. Decreto Regulamentar n.º 76/2007, de 17 de Julho. Diário da República, 1.ª série - N.º 136.
9. Marks J. Occupation and kansasii infection in Cardiff residents. Tubercle. 1975;56(4):311-13.

10. Marks J, Jenkins PA. The opportunist mycobacteria - a 20-year retrospect. Postgrad Med J. 1971;47(553):705–709.
11. British thoracic and tuberculosis association. Opportunist mycobacterial pulmonary infection and occupational dust exposure: an investigation in England and Wales. Tubercle. 1975; 56(4):295-313.

Night-work and arrhythmia: a clinical case

Trabalho noturno e arritmia: um caso clínico

Pietro Scaramuzzo[1], Diana França[1], Rodrigo Lobo[1], Luís Mendonça-Galaio[1], Ema Sacadura-Leite[1,2]

[1] Serviço de Saúde Ocupacional, Centro Hospitalar Lisboa Norte, Lisboa, Portugal, [2] CISP. Escola Nacional de Saúde Pública da Universidade NOVA de Lisboa, Lisboa, Portugal

Abstract

Night-work has been associated with an increased risk of development and worsening of cardiovascular diseases, by promoting a disruption in the circadian rhythm, thus altering the secretion of adrenaline and noradrenaline. In the case of rhythm disturbances, the literature is controversial, but there is a theoretical possibility of aggravation of underlying arrhythmias. In the present article is described a case of a nurse assistant, asymptomatic on her first occupational health exam. Three years gone by, she returns to our practice with a non-specific arrhythmia with paroxysmal ventricular tachycardia, confirmed by a 24-hour Holter monitoring. Other exams performed were negative for structural heart disease or myocardial ischemia. Given the published scientific evidence and after clinical evaluation, the worker's occupational activity was limited, with indication for avoidance of night-work. Also, she was referred to an Arrhythmology consultation for further study and clinical follow-up.

Key-words: Cardiac arrythmias, circadian rhythm, night work, shift work

Resumo

O trabalho noturno tem sido associado a um maior risco de desenvolvimento e agravamento de patologia cardiovascular, por promover uma disrupção do ritmo circadiano, alterando a secreção de adrenalina e noradrenalina. No caso específico das perturbações do ritmo cardíaco, a literatura é controversa, assumindo-se, no entanto, uma possibilidade teórica de agravamento de eventuais arritmias pré-existentes. No presente artigo, descreve-se um caso de uma assistente operacional, assintomática à data do exame de admissão de Medicina do Trabalho. Passados 3 anos, volta à consulta com um quadro de arritmia inespecífica, com salvas de taquicardia ventricular paroxística, confirmada em contexto de registo Holter de 24 horas. A restante avaliação complementar realizada foi negativa para cardiopatia estrutural ou isquemia do miocárdio. Perante a evidência científica publicada e após avaliação clínica, a trabalhadora ficou apta condicionalmente com indicação para evicção de trabalho noturno, e foi referenciada para a consulta de Arritmologia para acompanhamento especializado.

Palavras-chave*:* Arritmia, ritmo circadiano, trabalho noturno, trabalho por turnos

Introdução

As doenças cardiovasculares (DCV) constituem a principal causa de morte em Portugal, correspondendo a 29,5% dos óbitos na população geral. [1,2] Estas doenças são também a principal causa de morte e incapacidade permanente em trabalhadores, apesar de os respetivos fatores de risco profissionais não estarem completamente esclarecidos. [3]

Nas últimas décadas, vários estudos observaram um padrão circadiano na ocorrência de eventos cardiovasculares e colocaram a hipótese de estes serem desencadeados por alterações no sistema nervoso autónomo que ocorrem ao longo das 24 horas. [4,5] Estas suposições implicariam, portanto, que o trabalho por turnos e noturno, ao causar uma disrupção do ritmo circadiano normal do indivíduo, poderia constituir um fator de risco para desenvolvimentos de DCV, incluindo doença arterial coronária, acidentes vasculares cerebrais e arritmias, entre outras. [5] De facto, as queixas associadas ao sistema cardiovascular são as terceiras mais frequentes em trabalhadores por turnos, precedidas somente por alterações do padrão do sono e sintomas gastrointestinais. [5]

No entanto, no caso específico das arritmias, os estudos têm apresentado resultados contraditórios sobre a sua possível relação com o ritmo circadiano do indivíduo, [4,6-9] pelo que não existe consenso sobre o trabalho por turnos como agente etiológico de alterações do ritmo cardíaco.

Contudo, o trabalho por turnos poderá constituir um eventual fator de agravamento de patologia do ritmo cardíaco, levantando frequentemente dúvidas sobre a aptidão de profissionais que têm esse regime de horário de trabalho.

Apresenta-se de seguida o caso de uma trabalhadora a exercer atividade laboral por turnos, incluindo trabalho noturno, e com arritmia paroxística.

Apresentação do caso

Assistente operacional de 46 anos de idade, do sexo feminino, a exercer funções numa Unidade de Cuidados Intensivos desde 2015. Desde o início da sua atividade a nível hospitalar, realizou trabalho por turnos, incluindo trabalho noturno. No exame de admissão em 2015, apresentava obesidade grau I, mas não tinha referido qualquer outro antecedente médico ou familiar relevante, estava assintomática e tinha realizado um ECG que apresentava ritmo sinusal, com frequência cardíaca de 78 bpm e sem desvios do eixo elétrico, sinais de isquémia miocárdica ou outras alterações.

Em 2018, durante o exame periódico de Medicina do Trabalho, quando questionada sobre eventuais intercorrências desde o último exame de Medicina do Trabalho, a paciente referiu ter sido avaliada em consulta de Cardiologia, na sequência da qual realizou um registo Holter de 24 horas, que apresentou:

- episódios de ritmo auricular ectópico;
- sístoles ventriculares prematuras frequentes (1253/h) com maior incidência entre as 0h e 8h, surgindo sob formas repetitivas com 23 pares e 2 salvas de taquicardia ventricular, com 3 complexos atingindo frequência cardíaca de 134 bpm;
- numerosos episódios de bigeminismo e trigeminismo (total 11h21m55s).

Referiu ainda ter sido medicada com Bisoprolol 5 mg por dia, que suspendeu por iniciativa própria.

À data do exame periódico, a trabalhadora negava qualquer queixa do foro cardíaco, e não apresentava alterações no exame objetivo, sendo a auscultação cardíaca normal.

Perante o abandono da medicação e do seguimento em consulta de Cardiologia, pediu-se um novo registo Holter de 24 horas, que apresentou:

- curtos episódios de ritmo ectópico auricular de predomínio noturno;
- 9 sístoles prematuras supraventriculares isoladas;
- uma sístole prematura ventricular;
- no canal Y (derivações D1, D2 e aVF) inversão da onda T nos períodos de maior FC, associada a registo de “dores no peito” no diário.

Foi realizado ecocardiograma, onde não se objetivou cardiopatia estrutural,

Foi também pedida uma prova de esforço que resultou ser negativa para isquémica miocárdica.

Apesar de o último registo Holter não apresentar as alterações observadas no primeiro exame, não é suficiente para assumir a resolução do quadro clínico, dado tratar-se de uma arritmia que ocorre esporadicamente. Assim, a trabalhadora foi enviada à consulta de Arritmologia para acompanhamento especializado e eventual estudo mais minucioso de possíveis alterações estruturais, nomeadamente por Ressonância Magnética.

A profissional ficou apta condicionalmente com indicação para evicção de trabalho noturno.

Discussão e Conclusões

As DCV são patologias com etiologia multifatorial, sendo que vários estudos já demonstraram a contribuição de fatores como dislipidémia, tabagismo e hábitos alimentares e de atividade física no seu desenvolvimento. [10] Mais recentemente, foi evidenciado que as condições de trabalho podem também ter uma influência direta no desenvolvimento destas patologias, tanto por fatores de risco relacionados com o ambiente de trabalho, como relacionados com a atividade em si. [11] O primeiro grupo inclui características do ambiente em que o trabalhador exerce a sua profissão, como por exemplo, a exposição a compostos químicos, como dissulfato de carbono, nitroglicerina, vários solventes ou organofosforados. [11] O segundo está relacionado com as características da atividade em si, como no caso do trabalho sedentário ou por turnos. [11] Nesta última modalidade de trabalho têm especial relevância os turnos noturnos. Uma metanálise recente demonstra, de facto, que os turnos noturnos causam mudanças importantes que favorecem o aumento das DCV nos trabalhadores. [12] Em primeiro lugar, porque os indivíduos que trabalham em turnos noturnos apresentam maior frequência de dislipidemia, devido a um possível aumento na ingestão de alimentos e a alterações na digestão e absorção de nutrientes. [12,13] Também se tem verificado que os trabalhadores noturnos têm maior tendência para fumar mais comparativamente aos que trabalham em horário diurno. [14]

Relativamente às arritmias cardíacas e, mais especificamente às extrassístoles ventriculares, apesar da literatura reportar resultados contraditórios, alguns autores verificaram a existência de um aumento das mesmas em quem realiza trabalho noturno. [12,15] Em vários estudos foi demonstrado que o trabalho noturno altera a secreção de adrenalina e noradrenalina. A alteração da homeostase consequente parece estar na base de um possível efeito do trabalho noturno no ritmo cardíaco, podendo desta forma promover o aparecimento de arritmias. [12,15,16]

Apesar de os estudos não serem consensuais, no que respeita à repercussão do trabalho noturno nas alterações do ritmo cardíaco, por uma questão de precaução e em concordância com a trabalhadora, foi decidido limitar a atividade profissional no período noturno.

Referências

1. Instituto Nacional de Estatística. Direcção-Geral de Saúde. Pordata. Óbitos por algumas causas de morte. [Web page] Fundação Francisco Manuel do Santos; 2018 [Updated 30 Abr 2018; cited 4 Jul 2018]. Available from: https://www.pordata.pt/Portugal/%C3%93bitos+por+algumas+causas+de+morte+(percentagem)-758.
2. Instituto Nacional de Estatística. Morre-se mais de doenças do aparelho circulatório, mas os tumores malignos matam mais cedo. INE; 2017 [Updated 23 Mai 2017; cited 4 Jul 2018]. Available from: https://www.ine.pt/xportal/xmain?xpid=INE&xpgid=ine_destaques&DESTAQUESdest_boui=281091494&DESTAQUESmodo=2.
3. Leigh JP, Miller TR. Job-related diseases and occupations within a large workers' compensation data set. Am J Ind Med. 1998;33:197-211.
4. Viola AU, Simon C, Ehrhart J, Geny B, Piquard F, Muzet A, Brandenberger G. Sleep processes exert a predominant influence on the 24-h profile of heart rate variability. J Biol Rhythms. 2002;17(6):539-47.
5. Klerman EB. Clinical aspects of human circadian rhythms. J Biol Rhythms. 2005;20(4):375-86.
6. Kräuchi K, Wirz-Justice A. Circadian rhythm of heat production, heart rate, and skin and core temperature under unmasking conditions in men. Am J Physiol. 1994;267:R819-29.
7. Scheer FA, van Doornen LJ, Buijs RM. Light and diurnal cycle affect human heart rate: possible role for the circadian pacemaker. J Biol Rhythms. 1999;14(3):202-12.
8. Fujiwara S, Shinkai S, Kurokawa Y, Watanabe T. The acute effects of experimental short-term evening and night shifts on human circadian rhythm: the oral temperature, heart rate, serum cortisol and urinary catecholamines levels. Int Arch Occup Environ Health. 1992;63(6):409-18.
9. Ito H, Nozaki M, Maruyama T, Kaji Y, Tsuda Y. Shift work modifies the circadian patterns of heart rate variability in nurses. Int J Cardiol. 2001;79(2-3):231-6.
10. Beaglehole R. International trends in coronary heart disease mortality, morbidity, and risk factors. Epidemiol Rev. 1990;12:1-15.
11. Kristensen TS. Cardiovascular diseases and the work environment. A critical review of the epidemiologic literature on nonchemical factors. Scand J Work Environ Health. 1989;15(3):165-79.
12. Bøggild H, Knutsson A. Shift work, risk factors and cardiovascular disease. Scand J Work Environ Health. 1999;25(2):85-99.
13. Lennernäs M, Akerstedt T, Hambraeus L. Nocturnal eating and serum cholesterol of three-shift workers. Scand J Work Environ Health. 1994;20(6):401-6.

14. Knutsson A, Nilsson T. Tobacco use and exposure to environmental tobacco smoke in relation to certain work characteristics. Scand J Public Health. 1998;26(3):183-189.
15. Härenstam A, Theorell T, Orth-Gomèr K, Palm UB, Unden AL. Shift work, decision latitude and ventricular ectopic activity: A study of 24-hour electrocardiograms in Swedish prison personnel. Work & Stress. 1987;4:341-350.
16. Theorell T, Akerstedt T. Day and night work: changes in cholesterol, uric acid, glucose and potassium in serum and in circadian patterns of urinary catecholamine excretion. A longitudinal cross-over study of railway workers. Acta Med Scand. 1976;200(1-2):47-53.

Surgical approach to malignant otitis externa

Abordagem cirúrgica da otite externa maligna

Tomás Carvalho, Tiago Eça, Diogo Tomé, Vítor Oliveira, Leonel Luís

Serviço de Otorrinolaringologia, Centro Hospitalar Lisboa Norte EPE

Abstract

Necrotizing otitis externa (NOE) is a rare but potentially life-threatening infection that affects the external auditory canal and temporal bone. It's most frequently caused by *Pseudomonas aeruginosa*. Treatment includes correction of immunosuppression, control of diabetes, local treatment of the auditory canal and long-term systemic antipseudomonal antibiotic. We describe the case of a 84-years old man, diabetic type II, referred to our emergency department with a history of unilateral external otitis for 2 months, that haven't resolved with antibiotic. Our approach with high intravenous antibiotic doses, control of diabetes and local treatment wasn't successful, and surgical intervention was necessary. Despite the fact that surgical approach remains controversial, in this case was determinant in achieving a good outcome. The authors also intend to emphasize the importance of an early diagnosis in cases of NOE, a condition frequently misdiagnosed in a susceptible population with major comorbidities and a high mortality rate.

Keywords: Malignant/ Necrotizing Otitis externa, diabetes mellitus.

Resumo

A Otite Externa Maligna representa uma infeção rara, mas potencialmente fatal que afeta o canal auditivo externo e o osso temporal. O principal agente etiológico é a *Pseudomona aeruginosa*. O tratamento implica correção da imunossupressão, controlo do nível de glicémia, terapêutica tópica do ouvido, bem como antibioterapia endovenosa antipseudomonas, durante um período de tempo prolongado. Descrevemos o caso de um homem de 84 anos, com diabetes tipo II, referenciado ao nosso serviço de urgência por uma otite externa unilateral, com 2 meses de evolução, que não cedia à terapêutica médica. A nossa abordagem terapêutica inicial com recurso a altas doses de antibioterapia endovenosa, controlo glicémico e terapêutica tópica do canal auditivo externo, não foi eficaz, pelo que foi necessário recorrer a terapêutica cirúrgica. Apesar da abordagem cirúrgica desta patologia, ser considerada controversa, neste caso esta intervenção foi determinante em obter uma melhor resposta terapêutica.

Palavras-chave: Otite Externa Maligna, diabetes mellitus

Introduction

Necrotizing otitis externa (NOE) is a rare but potentially life-threatening disease that affects the external auditory canal and temporal bone. It occurs mainly in diabetes, immunocompromised patients, elderly (>60 years old), males and in humid and warm climates. It was first described by Chandler in 1968, and was initially entitled malignant external otitis, in which “malignant” was chosen to describe the high mortality (46%) associated with this condition [1].

It’s most frequently caused by *Pseudomonas aeruginosa* [2,3]. Other agents are *staphylococci*, *streptococci*, and *fungi*, but they are far less frequent [2,3]. Diabetic patients are more prone to the disease probably due to microangiopathy with progressive microcirculatory changes and impaired immunity [4].

Acute otitis external usually precedes the full NOE clinical picture, non-responsive to medical therapy. Patients complain of otalgia and sensitivity to auricular movement. Otorrhea may be present, obliteration of the external auditory canal (EAC) by edema and secretions may cause hearing loss. The pathognomonic sign is the presence of active granulation tissue in the bone–cartilage junction of the EAC [5].

As the infection progresses the disease spreads rapidly, invading surrounding soft tissues, cartilage and bones, causing necrosis and even spreading to the cranial nerves, resulting in skull base osteomyelitis and cranial nerve palsies. The facial nerve is usually the first nerve to become involved due to its anatomic location in the temporal bone [2,3].

Diagnostic laboratory tests include erythrocyte sedimentation rate, white and red blood cell counts, glucose and creatinine levels. Culture of ear secretions, before antibiotic therapy is started, is essential to achieve a good outcome [2,5]. High resolution CT and a technetium (Tc 99m) scintigraphy or gallium (Ga 67) scintigraphy of the temporal bone with contrast are the gold standard to delineate the extent of the disease [6,7]. Thus, histopathological examination of granulation tissue removed from the external auditory canal is helpful to exclude malignant processes

Treatment of necrotizing otitis externa includes correction of immunosuppression, local treatment of the auditory canal and long-term systemic antipseudomonal antibiotic and strict control of diabetes mellitus. The role of surgery in the treatment of necrotizing otitis externa remains controversial. With aggressive treatment the mortality rate from this disease, which used to be 50% in the past, has now been reduced to 10-20% [8].

The authors address the challenges faced in diagnosing and managing malignant otitis externa, as well as the potential role of surgery in these patients.

Case Report

We describe the case of an 84-year-old man, with history of type II diabetes and hypertension, that was referred to our emergency department due to an unilateral external otitis associated, with 2 months of history, not responsive with weekly local cleaning of the ear canal and antibiotics (initially penicillin twice a week and then gentamicine 80mg intravenous (IV) per day).

The patient complained of otalgia, otorrhea and hearing loss of the right ear. He was hemodynamically stable, conscious and oriented. The otoscopic examination showed a granulation

tissue, edema of the EAC, and a partially bony exposure with tissue necrosis. The tympanic membrane was not visible due to the edema and granulation tissue of the EAC. There were no retroauricular inflammatory signs, facial paralysis or vertigo. The left ear was normal on examination.

Laboratory tests revealed an elevated erythrocyte sedimentation rate and protein C reaction, with a high glucose serum level. There was no leukocytosis or anemia. Before starting medical therapy an ear swab and a tissue biopsy were taken.

A high-resolution CT scan of the ear and temporal bone was performed showing a soft tissue opacification of the external ear canal and an erosion of the temporal bone with an inflammatory process extending to the mastoid (Figure 1).

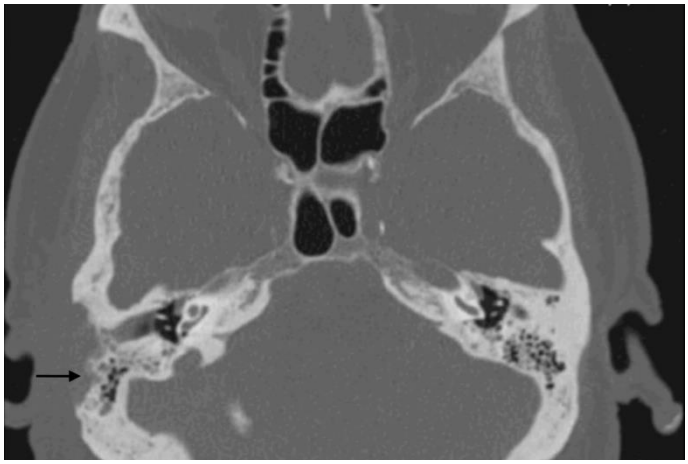

Figure 1 – Axial CT scan of the temporal bone. Erosion of the cortical temporal bone (arrow) with an inflammatory process extending to the mastoid without involvement of the midlle ear

The patient was hospitalized in order to continue intravenous antibiotic treatment and strict metabolic control of diabetes. The swab result of the EAC showed isolation of *Pseudomona aeruginosa*, sensible to gentamicin, piperacillin/tazobactam and ciprofloxacin. Mycology culture were negative. Considering these results, the authors decided to switch from gentamicin, a well-known ototoxic antibiotic, to piperacillin/tazobactam (4 g IV every 6 hours) and ciprofloxacin (400 mg IV every 12 hours). Diagnosis was later confirmed by the anatomopathological result.

Local treatment of the auditory canal, with topical antibiotic (ofloxacin) and aural toiling, including the removal of debris from the ear canal, was performed daily.

During hospitalization the patient showed no signs of clinical improvement, maintaining elevated erythrocyte sedimentation rate and protein C reaction, and so a new CT scan of the temporal bone was performed. This revealed an extension of the inflammatory process with osteomyelitis, involvement to temporomandibular joint, and an otomastoiditis with erosion of cortical of the temporal bone. There was no middle ear or intracranial involvement.

Based on the clinical evolution, analytical and imagological findings, and after 10 days of intravenous antibiotic therapy, the patient was submitted to a modified enlarged *Bondy* mastoidectomy and local debridement of involved soft tissue.

An extended retroauricular approach was used to gain access to the posterior retrosigmoid area, mastoid cortical temporal bone and to extend the dissection into the inferior aspect of the EAC. A lazy “S” retroauricular skin incision was used. After elevation of the skin flaps and pinna, the involved necrotic subcutaneous tissue was resected and identified a partial erosion of the inferior bony part of the EAC and osteomyelitis of the mastoid cortical bone extending into the retrosigmoid area of the temporal bone. A standard canal-wall-up timpanomastoidectomy technique was performed to gain access to the antrum and middle ear allowing identification of the key surgical

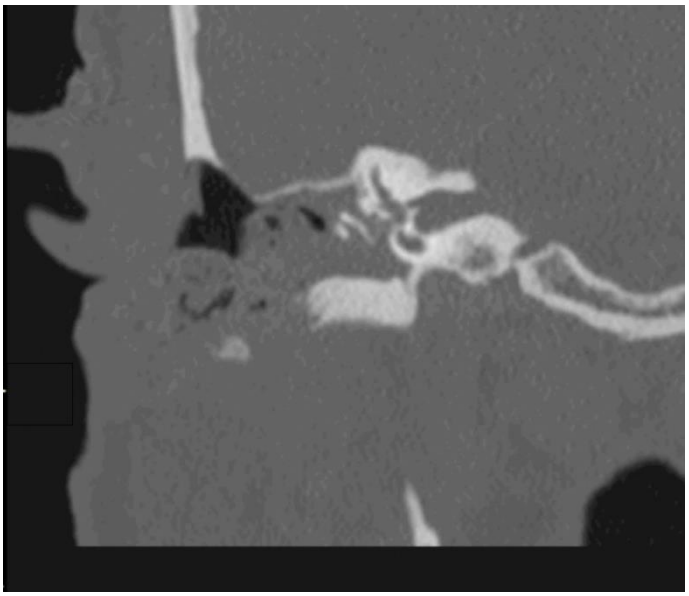

Figure 2 - Coronal CT scan of the temporal bone of the right ear after canal-wall-down mastoidectomy without opening the middle ear (Bondy mastoidectomy). Ear cavity filled with absorbable hemostat material, middle ear with soft tissue opacification but integrity of ossiculair chain maintained.

landmarks to permit the resection of the involved infected bone. As middle ear was free of disease the surgeons opted to convert the canal-wall-up technique into a canal-wall-down mastoidectomy without opening the middle ear - *Bondy* mastoidectomy which allows a full control of the ear cavity during follow-up.

During the postoperative care, antibiotic was changed from piperacillin/tazobactam and ciprofloxacin to Meropenem (2000 mg IV per day) for 20 days. During this period the patient showed a progressive clinical, analytical and imagological improvement (Figure 2). The patient was discharged 30 days after hospital admission, 20 after surgical intervention, with no signs of local infection, or elevated inflammatory parameters.

Discussion

At presentation, NOE is essentially a clinical diagnosis made in the presence of severe pain plus granulation tissue in the external auditory canal. In all cases, priority must be given to obtaining early microbiological culture specimen, in order to guide treatment [9].

The causative organism is mainly *Pseudomonas aeruginosa* [2,3]. The disease spreads rapidly, invading surrounding soft tissues, cartilage and bone causing necrosis and even spreading to the cranial nerves. The disease can be fatal if treatment is not rapidly implemented, especially if it spreads outside the EAC with involvement of the cranial nerves [2,3].

Diabetic patients are more prone to the disease due to poor vascular supply, resulting from microvascular disease which is aggravated by *pseudomonal* vasculitis, which further restricts tissue perfusion [2,3]. There is no dispute that the incidence of diabetes mellitus is an increasing disorder in developed countries worldwide. The increasing longevity of patients with HIV infection, due to antiretroviral therapy, can potentially increase the risk of malignant otitis externa. Hence, there will in future be a larger percentage of the population in significant risk factor for development of NOE. When combined with the increasing life expectancy and increasing cumulative antibiotic usage worldwide, malignant otitis externa could become life-threatening when multi-resistant pathogen strains are encountered as the causative organism. Necrotizing otitis externa in many patients, the initiating event may be self-inflicted or iatrogenic trauma to the ear canal. Therefore, susceptible patients should be instructed to avoid manipulation of the external auditory canal.

Mandatory laboratory tests include erythrocyte sedimentation rate (ESR), white and red blood cell counts, glucose and creatinine levels, and culture of ear secretions [2,5]. Imaging modalities include CT scanning that is used to evaluate the correct location and extent of the diseased tissue. Conversing the imaging, at least one third of bone erosion must be present before any radiologic changes become apparent. Magnetic resonance imaging (MRI) may overcome some limitations of CT and can usefully complement information of soft tissue invasion into the nasopharyngeal, parapharyngeal, intracranial involvements and the retrocondylar fat infiltration [6,7].

Treatment of necrotizing otitis externa includes correction of immunosuppression, local treatment with aural toiling and antibiotic therapy directed to the EAC and long-term systemic antibiotic therapy. Strict control of diabetes mellitus is mandatory, although it can be difficult to achieve during the acute period of the illness. Other immunosuppressive states and comorbid conditions must also be aggressively managed.

An antipseudomonal agent should be used as first line therapy [10,11]. If necessary, the agent can be changed on the basis of the results of the microbiological culture. Antibiotics that are effective against *Pseudomona aeruginosa* include aminoglycosides, penicillins, ceftazidime, and fluoroquinolones. Depending on bacterial sensitivity, a combination of agents may be needed [10,11,12]. The excellent antipseudomonal activity of the fluoroquinolones (ofloxacin and ciprofloxacin) has made them the treatment of choice [10,12,13]. The advantages of quinolones include its low toxicity profile and excellent penetration into bone. The dosing of ciprofloxacin does not require adjustment in the elderly patient with renal dysfunction [14]. Poor vascularization of the infected area is one of the reasons why high-dose antibiotic therapy is usually need to treat malignant otitis externa.

The role of surgery in the treatment of necrotizing otitis externa remains controversial [11, 12,15]. *Amorosa et al.* advocated that the process of debridement itself may expose healthy bone to the pathogen, causing more aggressive progression of the disease [15]. Surgery is generally limited to local debridement and biopsy collection, the latter both to exclude malignancy and to guide antimicrobial therapy. This is a significant paradigm change from the management described in related case reports [11, 12,15].

The mortality in malignant otitis externa has been markedly reduced due to a high diagnosis suspicion, the availability of antibiotics, and rapidly institute treatment [5,16]. Mortality often attributed to bilateral ear involvement and multiple cranial nerve palsies [17]. Cranial nerve involvement indicates a poor prognosis [5, 16,17]. Mortality can be due to intracranial complications such as sigmoid sinus thrombosis, but it may also occur due to treatment complications, including bone marrow suppression induced by long-term antibiotic therapy [5]. Prognosis is adversely affected by comorbid conditions, which are common in patients who develop malignant otitis externa [5, 16,17].

Conclusion

In this case report, we intend to emphasize malignant otitis externa remains a potentially life-threatening disease and a high suspicion is necessary in order to institute appropriate treatment. Despite the role of surgical treatment remaining controversial, due to the possibility of compromising

healthy exposed bone, we believe the surgical intervention in this patient was determinant in achieving a better response to the disease. As this concerns an increasingly prevailing disorder, in which surgical therapy remains a challenge, it is imperative that the optimal medical and surgical treatment can be combined. This case also reminds us a clinical entity easily misdiagnosed in a comorbid population, such as the elderly and diabetics, which may put life at risk.

References:

1. Chandler JR. Malignant Otitis Externa. Laryngoscope 1968;78:1257–94
2. Rubin J, Yu VL. Malignant external otitis: insights into pathogenesis, clinical manifestation, dianosis, and therapy. Am J Med 1988;85:391–8.
3. Strauss M, Aber RC, Conner GH. Malignant external otitis: long-term (months) antimicrobial therapy. Laryngoscope 1982;92:397–406.
4. Driscoll PV, Ramachandrula A, Drezner DA, Hicks TA, Schaffer SR. Characteristics of cerumen in diabetic patients: a key to understanding malignant otitis externa. Otolaryngol Head Neck Surg 1993;109:676–9
5. Martel J, Guyot M, Darrouzet V (1999) Otites externes «malignes» ou nécrosantes progressives. Revue de l'ACOMEN 5:405–415
6. Sudhoff H, Rajagopal S, Mani N, Moumoulidis I, Axon PR, Moffat D. Usefulness of CT scans in malignant external otitis: effective tool for the diagnosis, but of limited value in predicting outcome. Eur Arch Otorhinolaryngol 2008;265:53–6
7. Levin WJ, Shary JH, Nichols LT, Lucente FE. Bone scanning in severe external otitis. Laryngoscope 1986;96:1193–5
8. Bhandary S, Karki P, Sinha BK. Malignant otitis externa: a review. Pac Health Dialog. 2002 Mar;9(1):64-7.
9. S hollis, K evans. Management of malignant (necrotising) Otitis externa. The journal of laryngology & otology (2011), 125, 1212–1217.
10. Cahana Z, Gilboa A, Raz R. Changes in susceptibility to ciprofloxacin in a community in northern Israel. Drugs 1995; 49(suppl 2):173-4.
11. Kraus DH, Rehm SJ, Kinney SE. The evolving treatment of necrotizing external otitis. Laryngoscope 1988;98:934-9.
12. Joshua BZ, Sulkes J, Raveh E, Bishara J, Nageris BI. Predicting outcome of malignant external otitis. Otol Neurotol 2008;29:339–43.
13. Pistorius B et al (1999) Prospective randomised, comparative trial of ciprofloxacin otic drops with or without hydrocortisone vs. polymyxine B-néomycin-hydrocortisone otic suspension in the treatment of acute diVuse otitis externa. Infect Dis clin Prat 8:387–395
14. Grandis JR, Branstetter BF, Yu VL (2004) The changing face of malignant external otitis: clinical, radiological, and anatomic correlations. Lancet Infect Dis 4:34–39
15. Amorosa L, Modugno GC, Pirodda A. Malignant external otitis: review and personal experience. Acta Otolaryngol Suppl 1996;521: 3–16.
16. Grandis JR, Branstetter BF, Yu VL (2004) The changing face of malignant external otitis: clinical, radiological and anatomic correlations. Lancet Infect Dis 4:34–39
17. Ph Ceruse, Colleaux B, Truy E, Disant F, Morgon AH (1993) Les otites malignes externes. A propos de sept cas récents. Ann Otolaryngol 110:332–33

Leber's Hereditary Optic Neuropathy – an atypical presentation

Neuropatia Ótica Hereditária de Leber – apresentação atípica

Patrícia José[1], Nuno Pinto Ferreira[1], Fátima Campos[1]

Department of Ophthalmoloy, Centro Hospitalar Lisboa Norte, EPE

Abstract

Leber hereditary optic neuropathy is a rare mitochondrial genetic disease of the retina that preferentially targets the optic nerve and causes bilateral visual loss specially in young males. The purpose is to report a challenging diagnostic case in a 67-year-old man with progressive vision loss and bilateral optic disc atrophy. A rare mutation makes the diagnosis of the disease.

Keywords: Leber hereditary optic neuropathy, optic nerve atrophy, genetic diagnosis

Resumo

A neuropatia óptica hereditária de Leber constitui uma doença genética mitocondrial que afecta predominantemente o nervo óptico e causa diminuição da acuidade visual bilateral, tendencialmente em jovens do sexo masculino.

O objetivo deste artigo é apresentar um caso de diagnóstico desafiante num paciente do sexo masculino, de 67 anos de idade, com sintomatologia de baixa acuidade visual progressiva e ao exame fundoscópico com atrofia bilateral do disco óptico. O diagnóstico foi efetuado com recurso à genética, tendo uma mutação rara sido identificada.

Palavras-chave: Neuropatia Ótica Hereditária de Leber, atrofia do nervo ótico, diagnóstico genético

Introduction

Leber hereditary optic neuropathy (LHON) is a rare retinal ganglion cells degeneration caused by a mitochondrial disorder. A total of three mutations in polypeptides ND1 (G3460A), ND4 (G11778A) and ND6 (T14484C), in which all involved genes encode complex I subunits of a respiratory chain, are responsible for 90-95% of all cases. [1,2,3] Only 50% of the male and 10% of the female with mutations develop optic neuropathy (incomplete penetrance), which leads to consider environmental factors as modulation factors. [2]

The condition typically affects males in the second or third decade of life. It is characterized by acute or subacute painless unilateral loss of central vision, sequentially affecting the fellow eye in weeks or months. [2,3,4] In the acute stage, some patients may have a normal optic disc but typically there is an optic disc hyperemia with obscuration of the margins. Sometimes telangiectatic microangiopathy and swelling of the peripapillary nerve fiber layer may be found. In the late stages (chronic atrophic phase), a pallor optic disc accompanied by a cupping are developed. [3,4]. The

clinical manifestations and electrophysiologic studies can help to diagnose LHON, however the presence of a mutation associated with the disease is necessary. [5,6,7]

The authors aim to describe an atypical case of LHON in which the genetic mutation found is not common.

Case presentation

A 76-year-old man presented to the ophthalmology department with a bilateral and progressive vision loss, after two years of evolution and no other symptoms associated. No past ocular history was revealed.

His past medical history included renal lithiasis and prostate cancer which was being treated with hormonal therapy (in the past completed some sessions of chemotherapy and radiotherapy). The patient had moderate alcohol intake which ceased one year before.

His mother had had low visual acuity but it wasn't investigated, she died with ninety-year-old.

Under observation, his best corrected visual acuity was 1/10 in the right eye (RE) and 6/10 in the left eye (LE). Pupils were symmetric but with a slowed down reaction to light. Ocular motility was painless and no restrictions were found. Intraocular pressures were within normal limits. Eyelids had no abnormalities. Slit lamp examination was unremarkable, except incipient cataracts. Fundoscopy revealed bilateral optic atrophy. (Figure 1) Spectral domain optic coherence tomography of the retinal nerve fiber layer (SD-OCT RNFL) showed generalized loss of nerve fiber layers in both eyes. (Figure 2) Visual field (Humphrey 24:2) was coincident with OCT but demonstrated low reliability. (Figure 3)

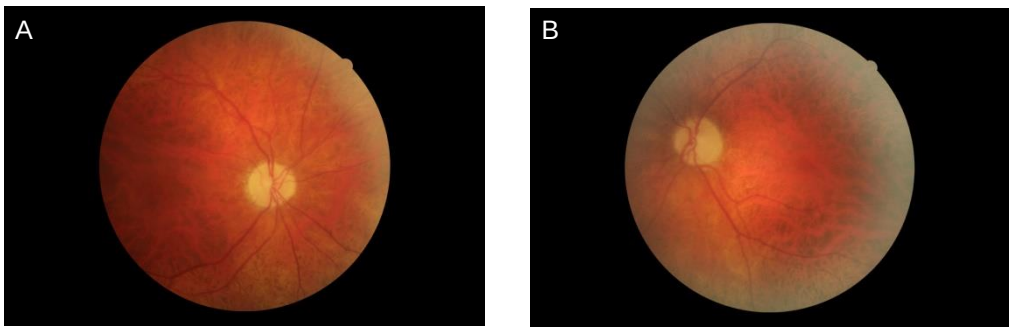

Figure 1 – Retinography (A - right eye, B - left eye)

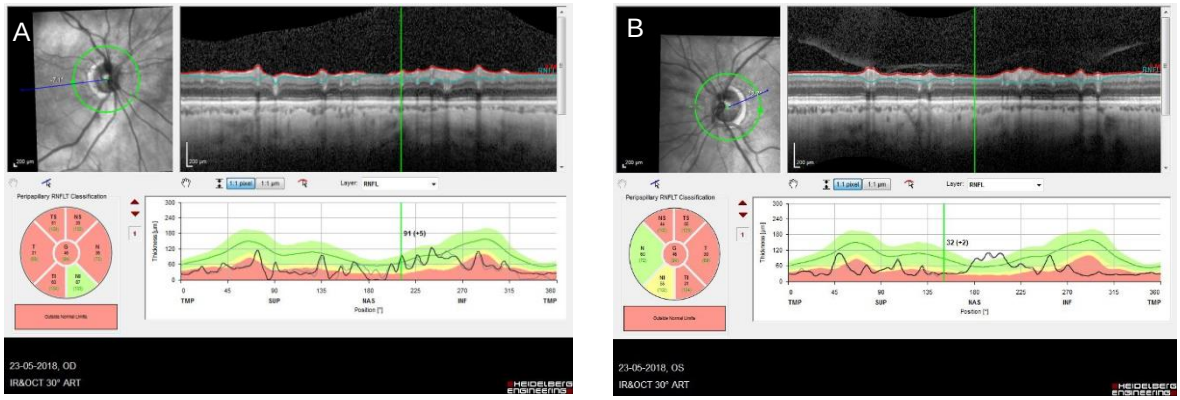

Figure 2 – SD-OCT CFN (A – right eye, B – left eye)

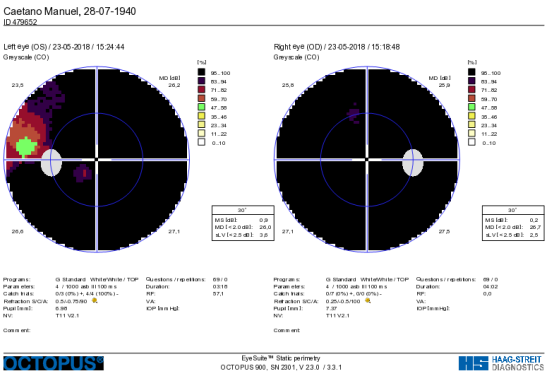

Figure 3 – PEC

Visual evoked potentials (VEP) revealed a significant reduction in amplitude of P100 wave bilaterally (RE: 3mV, LE: 2mV) and a high latency in the RE (116ms). (figure 4) A normal full field electroretinogram (ERG) was recorded in both eyes.

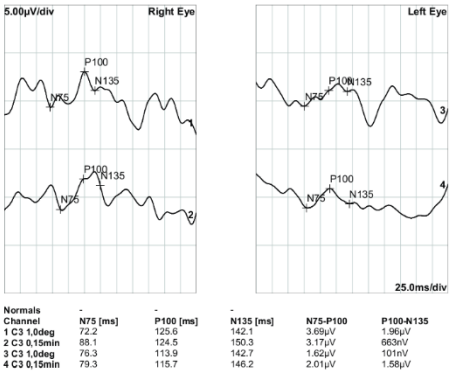

Figure 4 – VEP

Brain and orbital magnetic resonance imaging revealed a moderate reduction in the brain's volume, but no other changes were detected on neuroimaging. Blood tests were normal, with a low folate level.

Genetic results for the most common causative mutations associated with LHON phenotype (MT-ND1 – m3460G>A, MT-ND4 – m1778G>A, MT-ND6 – m14484T>6) weren't found. However, in the MT-ND1 gene, the mutations m.3394T>C and m.4216T>C were identified.

Discussion

The reported LHON case was a diagnostic challenge. The majority of the patients tend to be young and have an acute/subacute presentation of the disease (6 months). Unlike most cases, our patient was older and had a progressive loss of vision. History family is known in 60% of the patients, in our case the disease seemed to be sporadic. [1,2,4]

The clinical findings on fundus examination (bilateral optic neuropathy) are found in the LHON chronic stage LHON. They were consistent with a differential diagnosis of a nutritional-toxic or ischemic etiology and this could not be excluded indubitably. The genetic test gave us the molecular confirmation that LHON was the main cause of our clinical findings and the gene identified is one of the most common affected by this disease (ND1). Nevertheless, the mutations found (m3394T>C and m4216T>C) are considered "secondary mutations". [8] There are no studies or cases reported in Portugal about the mutations found in our case. In a study using a multi-gene panel carried out in Chinese population, these mutations had a low incidence, m3394T>C and m4216T>C

4.00% and 1.09%, respectively. Whereas, the incidence of mutations varies between different ethnic backgrounds. [9]

The OCT RNFL and visual field demonstrated a generalized involvement of the nerve fiber layers which is consistent with the chronic stage of the disease. [4,5,7]

The VEPs and ERGs are often abnormal in LHON patients. The results in our patient (prolonged latency and decreased amplitudes) were consistent with LHON but a normal ERGs was not a typical situation. [4,7,8]

Finally, this case shows that the diagnosis of LHON should be considered in all cases of unexplained optic neuropathy, even if there is no family history, late age of onset or clinical findings atypical.

Conclusions

LHON is the most common neuropathy caused by mitochondrial DNA mutation and leads to a severe and irreversible loss of vision. [1,2,5] This case is remarkable in the sense that unlike most cases, our patient had LHON with atypical presentation and a rare mutation. In the context of unexplained vision loss and bilateral optic neuropathy, all the efforts must be undertaken to investigate the etiology and to guide the patient the best way we could.

References

[1] E.Kirches. LHON Mitochondrial Mutations and More. Current Genomics. 2011; 12: 44-54

[2] Man PYM, Turnull DM, Chinnery PF. Leber hereditary neuropathy. Review article. J.Med Genet. 2002; 39: 162-169

[3] Bowling B. Neuro-ophthalmology: Optic nerve. Kanski's Clinical Ophthalmology: A Systemic Approach. Elsevier. 2016: 779-806

[4] Meyerson C, Stavern G, McClelland C. Leber hereditary optic neuropathy: current perspectives. Clinical Ophthalmology. 2015; 9: 1165-1176

[5] Grupo português de Neuroftalmologia. Neuropatias Ópticas Hereditárias. Neuroftalmologia baseada na evidência. Portugal: Ondagrafe, 2014; 99-117

[6] Yu-Wai-Man P, Chinnery P. Leber Hereditary Optic Neuropathy. GeneReviews [Internet]. 2016.

[7] Yang S, Yang H, Ma S, Wang S, He H, Zhao M. Evalutation of Leber's hereditary optic neuropathy patients prior to a gene therapy clinical trial. Medicine. 2016; 95: 40

[8] Orssaud C. Leber's hereditary optic neuropathy. Orphanet [Internet]. 2003.

[9] Mitomap – A human mitochondrial genoma database: https://www.mitomap.org/foswiki/bin/view/MITOMAP/WebHome

[10] Dai Y, Wang C, Nie Z, Han J, Chen T, Zhao X, et al. Mutation analysis of Leber's hereditary optic neuropathy using a multi-gene panel. Biomedical Reports. 2018; 8: 51-58

Internal mammary artery perforator flap for esophageal reconstruction

Reconstrução esofágica com retalho internal mammary artery perforator

Xavier de Sousa[1,2], Carlos Pinheiro[2], Vitor Fernandes[2]

[1] Department of General Surgery, Centro Hospitalar de Setúbal, EPE, [2] Departement of Plastic and Reconstructive Surgery, Centro Hospitalar Lisboa Norte, EPE
Correspondence to: Xavier de Sousa. E-mail: xavierpdesousa@gmail.com

Abstract

Esophageal cutaneous fistula is a severe complication and is increasingly more frequent in patients with malignant cervical diseases who are treated with long duration radiation therapy.

The authors present a case of a 74-year-old patient with a squamous cell carcinoma of the larynx, who underwent 22 sessions of neoadjuvant radiation therapy, followed by total laryngectomy. In the postoperative period he developed an esophageal cutaneous fistula, with two unsuccessful surgical closures. He was submitted to reconstruction with an internal mammary artery perforator (IMAP) flap.

Small to medium pharyngoesophageal or near tracheostomy defects represent a problem of difficult reconstruction. The IMAP flap has been shown to be an important option in the reconstruction of pharyngoesophageal or near tracheostomy defects, as in, laryngeal or esophageal reconstruction. It is an excellent surgical option due to its optimal vascularization and permits the direct closure of the donor site with no morbidity.

Keywords: Oncologic surgery, esophageal cutaneous fistula, reconstruction, IMAP flap

Resumo

A fístula esófago-cutânea é uma complicação grave e cada vez mais frequente nos doentes com patologia maligna cervical submetidos a radioterapia de longa duração.

Os autores apresentam o caso de um doente de 74 anos com um carcinoma celular da laringe, que realizou 22 sessões de radioterapia neoadjuvante, seguido de laringectomia total. No pós-operatório desenvolveu uma fístula esófago-cutânea, com duas tentativas de encerramento cirúrgico sem sucesso. Foi submetido a reconstrução com retalho pediculado *internal mammary artery perforator* (IMAP).

Os defeitos faringoesofágicos de pequena a média dimensão ou peritraqueostomia representam um problema de difícil reconstrução. O retalho pediculado IMAP tem vindo a demonstrar ser uma ferramenta importante na reconstrução de defeitos faringoesofágicos ou peritraqueostomia, assim como na reconstrução laríngea ou esofágica. É uma excelente opção cirúrgica devido à óptima vascularização, confiável e permite o encerramento directo da área dadora sem morbilidade.

Palavras-chave: Cirurgia oncológica, fístula esófago-cutânea, reconstrução, retalho IMAP

Introduction

Most head and neck cancers begin in the mucosal surfaces of the upper aerodigestive tract and are more likely to be advanced at the time of diagnosis [1]. Trends in the treatment of head and neck cancers have led to an increasing use of chemotherapy and radiotherapy as a first line treatment and the development of more intense radiotherapy regimens. When oncologic surgery is preceded of neoadjuvant therapy, head and neck cancer patients present an increase in both the incidence and the severity of oropharyngeal complications [2, 3]. In these cases the most important complication after oncologic surgery is the development of fistula. Studies show the patients undergoing total laryngectomy have a higher rate of fistula development, ranging from 10% to 40%. These fistulae present with significant morbidity and sequelae. It has been shown that besides neoadjuvant chemotherapy and radiotherapy, the extent of the surgery and concurrent neck dissection are also a contributive risk factor for the development of fistulae [3, 4].

The management of fistulae include non-surgical and surgical strategies. Non-surgical conservative treatments aim to promote healing by secondary intention, by using a variety of wound dressing options [3, 4]. Healing by secondary intention in a previous irradiated field is rarely successful and definite treatment commonly requires well vascularized tissue [5]. The choice of using pediculated flaps in head and neck reconstruction surgery is increasing [3]. They are reliable and easy to harvest, allow a reliable coverage of the defect and primary closure of the donor site, with great results and functionality [5]. The use of an internal mammary artery perforator (IMAP) island flap has shown great results for anterior neck reconstruction with favorable outcomes and is described by several authors [3, 5 - 10].

Case Report

We present the case of a 74-year-old male patient, with a personal history of silicosis and smoking habits of 50 pack year unit. The patient was diagnosed with stage IV (T4N2M0) squamous cell carcinoma of the larynx. After a multidisciplinary team discussion, neoadjuvant radiation therapy prior surgery was proposed. The patient underwent 22 sessions of low grade radiation therapy, followed by total laryngectomy with cervical lymph node dissection. In the postoperative period, the patient developed an esophageal cutaneous fistula (Figure 1). Two unsuccessful attempts of surgical closure of the fistula by otorhinolaryngology were made. With reference to this result, the patient was sent to a plastic surgery consultation for evaluating the possibility of closure of the fistula. An IMAP flap was proposed for the closure of the esophageal cutaneous defect. Preoperative Doppler was performed to select the site of the most optimal IMAP. It identified the second perforator of the right internal mammary artery as the best IMAP to use and its location was marked (Figure 2). Under general anesthesia,

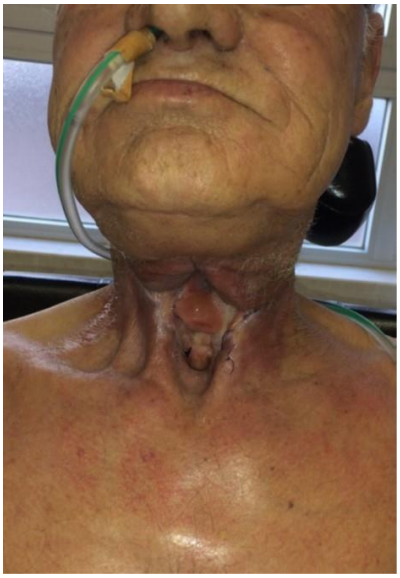

Figure 1

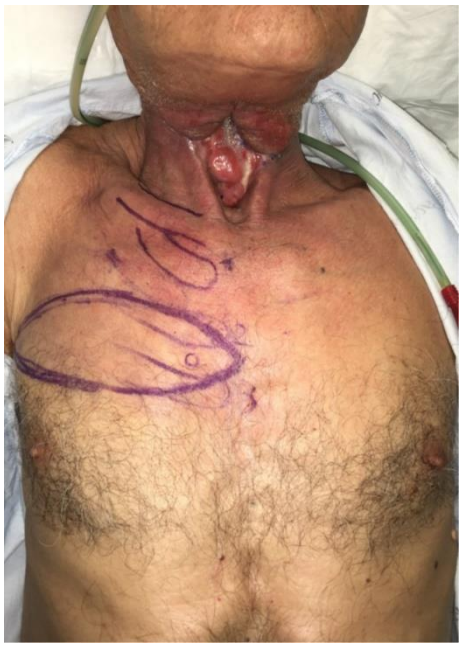

Figure 2

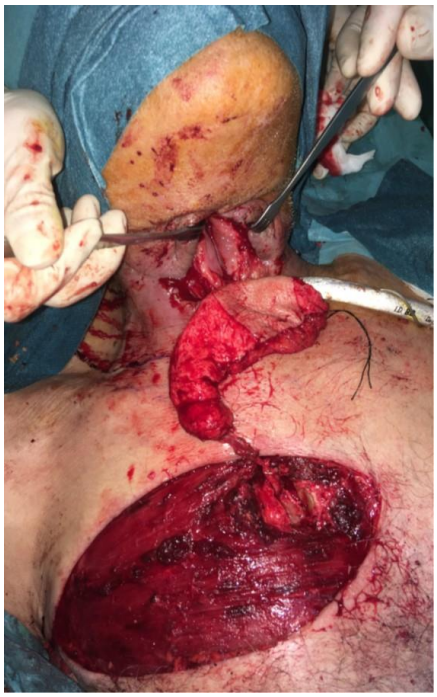

Figure 3

the patient underwent fistulectomy and reconstruction of the defect with the IMAP pediculated flap. A horizontal incision of the skin above the location of the perforator for the fasciocutaneous flap and dissection of the vascular pedicle until its origin in the right internal mammary artery was performed. The flap was brought tension free to the neck through a subcutaneous tunnel. The esophageal mucosal defect was reconstructed with lining of the skin of the flap and the outer side of the defect was covered with a full thickness skin graft harvest from the remaining skin of the flap over its fascia (Figure 3). The donor site was closed without tension and the flap showed no sign of bad perfusion (Figure 4). The immediate postoperative care was in the intensive care unit. Continuous flap observations were maintained during the first 48 hours. The patient was discharged on the 5th day and maintained follow-up in Plastic Surgery (Figure 5), Otorhinolaryngology and Oncology consultations.

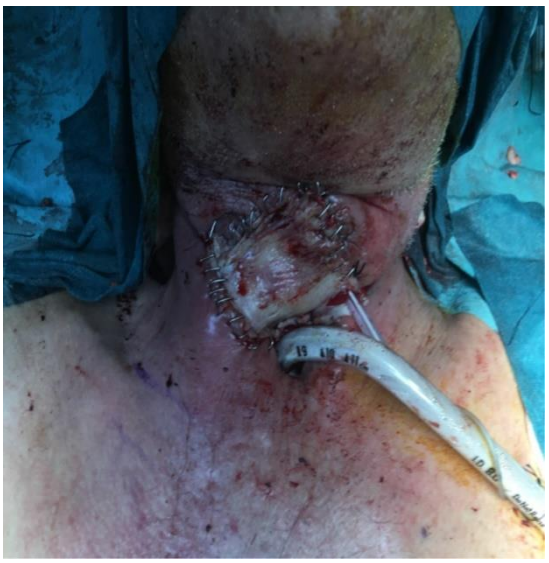

Figure 4

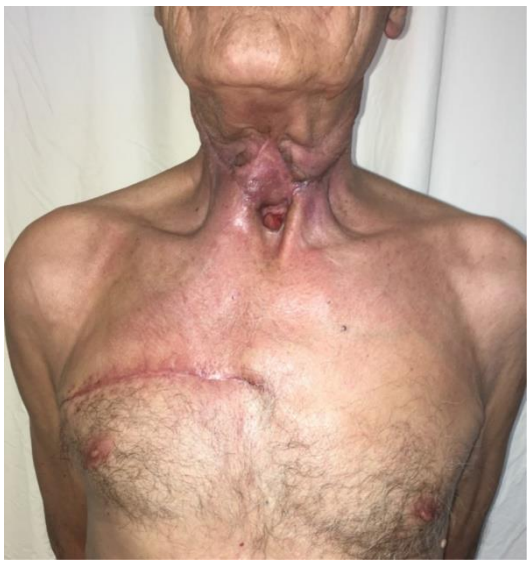

Figure 5

Discussion

Reconstruction of head and neck cancers after oncologic surgical treatment may be challenging. Many reconstruction strategies include regional, microvascularized or perforated flaps, including the deltopectoral and the IMAP flap [5 - 8]. Perforated flaps can either be used as a free flap or a pediculated flap. In head and neck cancers they represent a recent advance in reconstruction. The IMAP pediculated flap is a thin and pliable fasciocutaneous flap that can be used for small to moderate sized defects involving the anterior lower neck, especially in patients that were treated with neoadjuvant radiotherapy making local tissues not suitable for closure. Its use provides a quick and easy coverage [5, 7 – 9]. The skin paddle of the flap can be used both for reconstruction of the mucosal lining of the aerodigestive tract or for external reconstruction [9]. The IMAP flap is an island flap based on a single IMAP vessel, making it more mobile and versatile due to an increased arc of rotation [5, 7, 8]. Cadaver anatomical studies have shown that the IMAP vessels are located about 13-14mm from the lateral border of the sternum. The most reliable perforator was the second IMAP, generally considered the dominant vessel, in the second intercostal space, which allows a skin flap dimension of about 9x16cm. This flap can safely be rotated cranially for anterior neck reconstruction [5, 7, 8, 10]. Preoperative Doppler studies should be performed to confirm the presence of the IMAP vessel and its course. If the Doppler is equivocal, CT angiogram is used to assess the IMAP's size and location. The main advantage is the ability of primary closure of the donor site without excessive tension, allowing less morbidity and superior aesthetic result [5, 7, 8] however the maximum size of the flap should be limited to 6x15cm to allow the closure [7]. The surgical technique involves dissection of the perforator vessels to their origin on the internal mammary artery after excision of the rib cartilage and excising a horizontal fasciocutaneous flap in the direction of the axilla. Some care to the technique should be kept in mind such as precise rising of the flap and careful removal of the cartilage and handling of the vessels [5].

Conclusion

This case illustrates a successful use of the IMAP flap in a complicated esophageal cutaneous fistula after radiation therapy and oncological surgery. The IMAP flap appears to be a reliable surgical option for the treatment of these lower neck defects in an irradiated field as it provides a well-vascularized, thin and pliable tissue with a wide arc of rotation ideal for their reconstruction. Flap harvest and insertion are simple and primary closure of the donor site with minimal morbidity are advantageous.

References

1. Brockstein BE, Stenson KM, Song S. Overview of treatment for head and neck cancer. In: Connor RF, ed., UpToDate. Waltham, MA: UpToDate. https://www.uptodate.com/contents/overview-of-treatment-for-head-and-neck-cancer (accessed on September 2018).

2. Rose-Ped AM, Bellm LA, Epstein JB, Trotti A, Gwede C, Fuchs HJ. Complications of Radiation Therapy for Head and Neck Cancers. The Patient's Perspective. Cancer Nurs. 2002; 25(6): 461-7.

3. Nguyen KT, Iyer NG. Management of post-operative fistula in head and neck surgery: Sweeping it under the carpet? World J Otorhinolaryngol. 2015; 5(4): 93-104.

4. Xiong YJ, Jin RQ, Liu F, Peng SP. Current treatment of pharyngocutaneous fistula after total laryngectomy. Lin Chung Er Bi Yan Hou Tou Jing Wai Ke Za Zhi. 2017; 31(23): 1858-1862.

5. Mirghani H, Leymarie N, Amen F, Qassemyar Q, Leclère FM, Kolb F. Pharyngotracheal fistula closure using the internal mammary artery perforator island flap. Laryngoscope. 2014; 124(5): 1106-11.

6. Patel SA, Chang EI. Principles and practice of reconstructive surgery for head and neck cancer. Surg Oncol Clin N Am. 2015; 24(3): 473-89.

7. Iyer NG, Clark JR, Ashford BG. Internal mammary artery perforator flap for head and neck reconstruction. ANZ J Surg. 2009; 79(11): 799-803.

8. Yu P, Roblin P, Chevray P. Internal mammary artery perforator (IMAP) flap for tracheostoma reconstruction. Head Neck. 2006; 28(8): 723-9.

9. Kannan RY. The internal mammary artery perforator flap and its subtypes in the reconstruction of median sternotomy wounds. J Thorac Cardiovasc Surg. 2016; 152(1): 264-8.

10. Schmidt M, Aszmann OC, Beck H, Frey M. The anatomic basis of the internal mammary artery perforator flap: a cadaver study. J Plast Reconstr Aesthet Surg. 2010; 63(2): 191-6.

Femoral neck fractures following electrical shock injuries

Fracturas do colo do femur após electrocussão

André Mértola Chambel*, Ana Sofia Lima*, Francisco Alves*, João Ricardo Pedro*, João Ribeiras Cabral*, André Spranger*

*Serviço de Ortopedia do Hospital de Santa Maria, CHLN

Abstract

Electrical injuries, although relatively uncommon, are inevitably encountered by most emergency physicians. The spectrum of electrical injury is broad, ranging from minimal injury to severe multiorgan involvement or even death. Following such event, the musculoskeletal system might be involved with rhabdomyolysis or even bone fractures. Femoral neck fractures following an electrical shock injury are very rare and can result due to fall from height or to violent muscle contraction. There are only four published cases of the latter, being our case report the fifth case and the most severe one (Garden type IV). This article combines a case report and a literature review concerning these cases.

Keywords: Electrical shock, bone, femoral neck fracture

Resumo

As eletrocussões, apesar de relativamente raras, são situações inevitavelmente encontradas por médicos no serviço de urgência. A apresentação clínica é variável e pode ir desde uma simples queimadura cutânea até disfunção multiorgânica e mesmo à morte. O envolvimento do sistema musculo-esquelético pode ocorrer, mais frequentemente com rabdomiólise ou mais raramente com envolvimento ósseo. As fraturas do colo do fémur após eletrocussão podem resultar de uma queda ou de contração muscular. Existem apenas quatro casos publicados com este último mecanismo proposto, sendo este o quinto caso e o mais grave, dado tratar-se de uma fractura Garden tipo IV com necessidade de artroplastia total da anca. Este artigo junta um caso clínico e revisão da literatura.

Palavras-chave: choque elétrico, colo do fémur, osso

Introduction

Increased use of electrical-power driven tools in modern human society, as convenient as it is, also presents a constant threat, especially to electricians and construction workers. Nonetheless all the safety precautions, accidents do happen and will continue to happen as probably everyone has, at least once in his or her lifetime, been shocked by electricity [1].

There aren't two identical electrical shock injuries: the type and extent of an electrical injury is determined by voltage, current strength and type, duration of contact with the source, pathway of

flow, body size, position and composition/density (resistance), presence of protective gear and tissue-field interactions.

Different power sources have different voltage (high (>1000V) or low voltage (<500 V)), resistance and type of current (alternating (AC) or direct (DC)). Low voltage AC (the most common type of electricity in homes and offices) shocks usually result in minor peripheral neurological symptoms or, occasionally, skin burns. Nevertheless, AC can cause an electrical-induced muscle spasm that causes a prolonged “non-let-go” phenomenon - the cyclic flow of electrons causes muscle tetany that prolongs victims' exposure to the source.

More complex injuries can occur with higher voltage or DC, which is used mainly in industrial supply, usually causing a single muscle contraction and an explosive thermo-acoustic blast that throws the victim away, resulting in a brief duration of contact with the source flow.

Accidents evolving electrical shock can theoretically injury every human tissue [1]. Electrical current conduction varies depending on the electrolyte and water content of the body tissue through which electricity is being conducted. Blood vessels, muscles, and nerves have high electrolyte and water content, and thus low resistance, therefore are good conductors of electricity–better than fat, skin and lastly bone.

As the human tissue with greater resistance, bone generates heat when conducting an electric current, which can lead to late necrosis and aseptic *sequestra* [2]. Yet, bone injuries following an electrical shock injury are rare and occur more often due to trauma from a fall after consciousness loss or violent muscle contractions rather than necrosis.

The incidence of fractures following an electrical shock varies from 3,3 to 11,1% [3]. Most common on the upper extremities, especially about the shoulder, can also occur in vertebral bodies (compression fractures). Proximal femoral fractures due to muscular spasm following an accidental electrical shock are very rare and literature review revealed only four cases of the latter.

Case Report

This case report concerns an otherwise healthy 30-year old male electrician. He was kneeling working on an electric utility box when his forehead accidentally touched a wire with 340V alternating current for a few seconds, after which he fell onto his left shoulder, with brief consciousness loss. He felt immediate excruciating pain (8/10 VAS) on his left hip and couldn’t bear weight on the affected limb. During transportation and at the emergency department he kept a GCS of 15, with normal blood pressure and slightly elevated heart rate (sinus rhythm between 100 and 110 bpm), most likely because of the pain.

Reanimation room evaluation revealed a slightly shortened ft limb with external rotation, without neurovascular injury. He had a third degree burn on the left side of his forehead with extension to the left superior eyelid which led to an ectropion (point of entry), but without corneal or ocular globe injuries; he also had another small third degree burn on his left shoulder, above the clavicle (point of exit); no other skin injuries were present.

Further evaluation was performed with blood samples, head CT scan, EKG and echocardiogram, which didn’t show relevant abnormalities besides an elevated CK.

Left hip x-ray revealed a subcapital fracture of proximal femur (Garden IV), with severe comminution and extension to greater trochanter; the patient was admitted to the hospital's burn unit awaiting surgery and went through left hip a CT scan. A total hip replacement (non-cemented, direct lateral approach) was performed a few days later without complications. Post-operative period was uneventful and the patient was discharged from the burn unit after two weeks. Outpatient evaluation at 2 weeks post op demonstrated a good result, being the patient walking with the aid of two crutches (50% weight bearing on the affected limb) and minor pain.

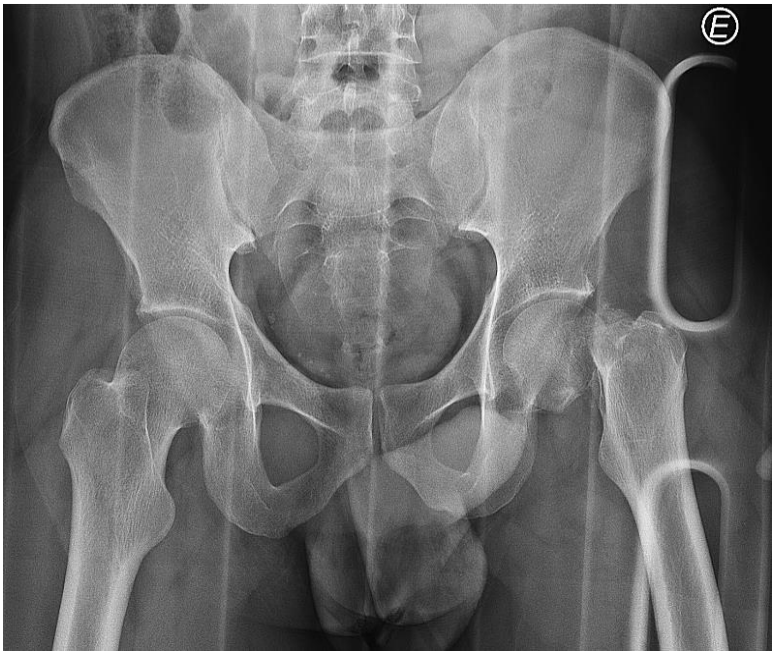

Image 1 - Reanimation room x-ray with left femoral neck fracture

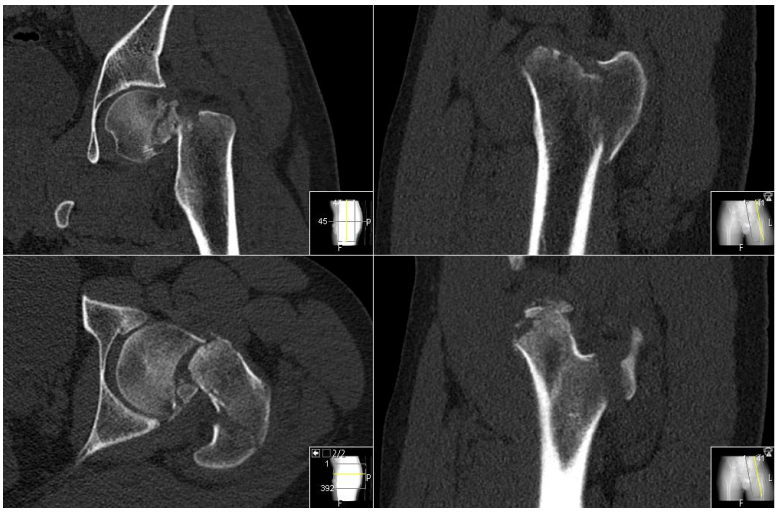

Image 2 - Left hip CT-scan demonstrating a comminuted Garden type IV fracture with extension to greater trochanter

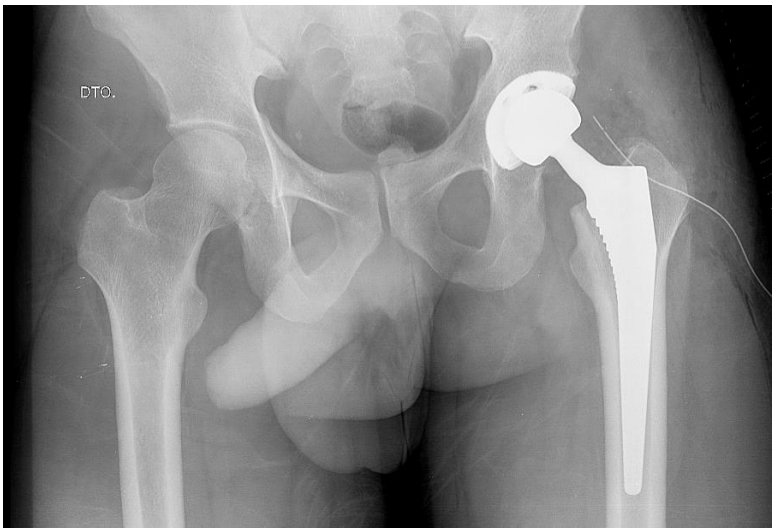

Image 3 - After surgery x ray wit total hip replacement

Discussion

Bone injuries following an electrical discharge can result from a fall from height or violent muscle contraction. Femoral neck fractures after accidental electrical shock are very rare, with a total of nine case reports[4–6]; Most of them describe fractures after significant fall from height or associated with pathological conditions (hipovitaminosis D); only in four of these cases the proposed mechanism is muscular contraction.

Table 1 - Femoral fractures following electrical shock injury

Author	Year	Age	Fracture	Side	Approach	Follow up
Tompkins	1980	40	Subcapital (Garden 2)	Bilateral	Cannulated screws	n.a.
Shaheen	1984	25	Subcapital	Bilateral	Nail and plate	1 year
Gehlen	2010	41	Subcapital (Garden 3)	Left	DHS	1 year
Sohal	2016	20	Subcapital (Garden 3)	Bilateral	Cannulated screws	16 months

We do not believe that the severity of the reported fracture was due to direct impact from the fall from a kneeling position in this otherwise healthy 30-year old man, but otherwise the violent muscular contractions. Being the fifth described case, apparently it is the most severe one due to a Garden type IV fracture with severe comminution and extension to greater trochanter. All the other cases went through osteosynthesis, while we performed a total hip replacement considering the fracture pattern.

Opposite and simultaneous forces from gluteal and adductor group, and in lesser proportion the lateral rotators and the iliopsoas muscle, might cause important tension on the femoral neck, resulting in the shattered pattern observed in our patient.

Being the electric wound injuries and the fracture all on the same side, we believe only the left side of the patient's body was affected by the discharge, the same situation as reported by Gehlen et al [2].

Predisposing factors for minor trauma related femoral neck fracture include irradiation for malignancy, abnormal anatomy, renal osteodystrophy or nutritional osteomalacia [4], none of which were present in our patient.

These fractures were reported only in men, which can be due to professional risk exposure, as men work more often with electricity, or because muscles are stronger and well-toned compared to women [5].

Conclusion

Literature review demonstrated the importance of being aware of this kind of injuries, as in some of the described cases the diagnosis was delayed in up to one week [6]. This is particularly true in unconscious, uncooperative or patients with serious pain associated with other injuries (i.e. skin burns). Electrical shock induced fractures can occur in the vertebral bodies, shoulders and femoral necks, therefore shoulders, spine and pelvis should be assessed via an x-ray. In conscious and cooperative patients with a painless complete ROM, imagiological evaluation is unnecessary [3,7].

We do not yet have a long-term follow-up, but frequent outdoor clinic checkups will be assessed in order to early notice possible complications. Previous cases follow up didn't reveal any particular complication to be aware of in this kind of injury, even though the surgical procedures were different; Good functional outcomes are expected for our patient.

References

1. Lee, R. et al. Biophysical injury mechanisms in electrical shock trauma. *Annu. Rev. Biomed. 2000.* 2**:** 477–509.
2. Gehlen, J, Hoofwijk, G. Femoral neck fracture after electrical shock injury. *Eur. J. Trauma Emerg. Surg.* 2010. 36: 491–493.
3. Tompkins, G. Bilateral simultaneous fractures of the femoral neck: case report. *J. Trauma.* 1990. 30**:** 1415–1416.
4. Sohal, H, Goyal, D. Simultaneous bilateral femoral neck fractures after electrical shock injury: a case report. *Chin. J. Traumatol.* 2013. 16: 126–128.
5. Nekkanti, S., Vijay, C, Theja, J. An unusual case of simultaneous bilateral neck of femur fracture following electrocution injury - A case report and review of literature. *J. Orthop. case reports.* 2016.
6. Atkinson, E, Gregory, J, Arnold, D. Simultaneous fractures of both femoral necks: review of the literature and report of two cases. *Clin. Orthop. Relat. Res.* 1980. 152**:** 284–287.
7. Fish, R. Electric injury, part II: specific injuries. *J. Emerg. Med.* 2000. 4679**:** 27–34

Vermilionectomia num caso de queilite actínica

Vermilionectomy in a case of actinic cheilitis

Alexandra Lóio[1], Miguel Nunes[2], João A. Correia[1], José Ferreira[1], Ivo Álvares Furtado[3], Francisco Salvado[4]

Serviço de Estomatologia, Centro Hospitalar Lisboa Norte; Clínica Universitária de Estomatologia, Faculdade de Medicina da Universidade de Lisboa.

Resumo

A queilite actínica é uma condição potencialmente maligna relacionada com a exposição solar prolongada e repetida, que afeta preferencialmente o lábio inferior. Apresenta uma evolução lenta e pode culminar em carcinoma epidermoide. Apresentamos o caso de um homem de 55 anos, caucasiano, fumador, que exibia uma lesão ulcerada queratinizada, com cerca de 1 cm de diâmetro, no lábio inferior à esquerda, assintomática, com vários meses de evolução, cuja biópsia incisional revelou focos de displasia ligeira a moderada. Realizou-se excisão em cunha do lábio inferior, com vermilionectomia total e vermilioplastia com retalho de avanço da mucosa retrolabial, com bons resultados estético e funcional.

Palavras chave: queilite, vermilionectomia, vermilioplastia.

Abstract

Actinic cheilitis is a potentially malignant condition related to prolonged and repeated sun exposure, which preferentially affects the lower lip. It presents a slow evolution and can culminate in epidermoid carcinoma. We present the case of a 55-year-old caucasian male, with smoking habits, who had a keratinized ulcerated lesion about 1 cm in diameter on the left lower lip, asymptomatic, with several months of evolution, whose incisional biopsy revealed foci of dysplasia mild to moderate. A wedge excision of the lower lip was performed, with total vermilionectomy and vermilioplasty with retrolabial mucosal advancement flap, with good aesthetic and functional results.

Keywords: cheilitis, vermilionectomy, vermilioplasty

Introdução

O lábio inferior é a região anatómica mais frequentemente afetada por queilite actínica, condição potencialmente maligna associada à ação cumulativa da exposição solar e intimamente relacionada com desenvolvimento de leucoplasia e carcinoma epidermoide [1]. Outros carcinogénicos comumente envolvidos são o tabaco e o álcool. São mais propensos a desenvolver queilite actínica homens, leucodérmicos e indivíduos com profissões que impliquem elevada exposição solar, tais como pescadores e agricultores [2]. A progressão de queilite actínica tem um curso lento, que se apresenta, inicialmente, com áreas atróficas no *vermilion* do lábio inferior que

com o tempo se tornam ásperas e escamosas nas regiões externas secas [3]. Estas lesões também podem aparecer na porção mais interna do lábio. Podem surgir úlceras crónicas em um ou mais locais, que podem permanecer durante meses ou anos e evoluir para carcinoma epidermoide. O carcinoma típico do *vermilion* apresenta-se sob a forma de uma lesão rígida, ulcerada, exsudativa com escara, geralmente menor que 1 cm diâmetro e associada a queilite actínica [1].

A reconstrução cirúrgica labial é a principal opção terapêutica e constitui um desafio que impõe dois requisitos principais: função (competência oral – fonação e contenção de saliva e alimentos) e estética labiais [3]. A lesão deve ser definida em termos de profundidade, localização em relação ao *vermilion* e pele normal do lábio, grau de defeito proporcionalmente ao volume total do lábio (regra dos terços) e relação com as comissuras [2].

Antes de qualquer procedimento cirúrgico radical, deve realizar-se a biópsia incisional da lesão, a fim de determinar a morfologia da área e grau de displasia, porque as alterações epiteliais diferem ao longo do bordo *vermilion* [1]. Existem várias opções de tratamento cirúrgico. No caso de lesão superficial que se estende a todo o *vermilion*, a melhor abordagem é a vermilionectomia total, de comissura a comissura, com preservação do músculo orbicular da boca, associada a vermilioplastia com recurso a retalho de avanço da mucosa retrolabial [5]. Caso haja um processo carcinomatoso infiltrativo dentro da zona displásica, a melhor opção é associar à vermilionectomia a ressecção da espessura total do lábio (ressecção cuneiforme V-W ou queiloplastia simples), se a lesão não exceder um terço do comprimento do lábio. Outras modalidades terapêuticas disponíveis para queilite actínica são criocirurgia, eletrocauterização, 5-fluorouracilo tópico e laser CO2 [2].

Caso Clínico

Doente do sexo masculino, de 55 anos, caucasiano, fumador, com antecedentes de porfiria cutânea associada a hepatite C crónica tratada e de toxicodependência para opiáceos e canabinóides, referenciado pelo médico de família à consulta de Medicina Oral do serviço de Estomatologia do Centro Hospitalar Lisboa Norte, em Outubro de 2017, por lesão do lábio inferior esquerdo, com vários meses de evolução.

O doente apresentava uma lesão ulcerada queratinizada, no lábio inferior, à esquerda, sem continuidade com a comissura labial, com aproximadamente 1 cm de maior eixo, assintomática.

Perante o quadro clínico sugestivo de queilite actínica, programou-se biópsia incisional da lesão, sob anestesia local, que se realizou em Dezembro de 2017. O exame anátomo-patológico revelou focos de displasia epitelial ligeira a moderada. O doente não compareceu a várias consultas de seguimento, pelo que só foi observado em Maio de 2018, com agravamento do quadro clínico. Ao exame objetivo o doente apresentava uma lesão ulcerada paramediana esquerda do bordo vermelho do lábio inferior, rígida à palpação e área de hiperqueratose com extensão contralateral. Definiu-se como plano de tratamento, excisão em cunha do lábio inferior à esquerda, com vermilionectomia total, de comissura a comissura, e vermilioplastia com retalho de avanço para reconstrução da mucosa labial, sob anestesia geral, que se realizou em Junho de 2018. O exame anátomo-patológico revelou focos de displasia de ligeira a moderada, com margens livres de lesão.

Na avaliação pós-operatória, o doente apresentava função labial e estética mantidas. Reforçaram-se as recomendações relativas à aplicação diária regular de protetor solar tópico e hidratação labial.

Discussão

A vermilionectomia revela-se o tratamento de eleição da queilite actínica, no caso de presença de displasia moderada a grave, ou como terapêutica profiláctica de carcinoma epidermóide, uma vez que é curativo, de baixo custo e apresenta bons resultados estéticos. É importante excisar todo o vermelhão entre comissuras, não só porque o resultado estético é melhor, como também porque as alterações epiteliais diferem ao longo de toda a extensão da lesão.

Conclusão

Com este caso clínico os autores pretendem rever as abordagens terapêuticas de uma situação potencialmente maligna. É fundamental a vigilância clínica regular.

Referências

1. Cogrel O. Mucosal advancement flap in the repair of vermilionectomy defects of the lower lip. *Ann DermatolVenereol*. 2014 Nov.
2. ShahAY, DohertySD, RosenT. Actiniccheilitis: a treatmentreview. *IntJ Dermatol*. 2010 Nov.
3. Vasconcelos M, Moraes S, Lemos C, et al.Surgical versus non-surgical treatment of actinic cheilitis: a systematic review and meta-analysis. *Oral Dis*. 2018 Jun 16.
4. Rossoe EWT, Tebcherani AJ, Sittart JA, Pires MC. Actinic cheilitis: aesthetic and functional comparative evaluation of vermilionectomy using the classic and W-plasty techniques*. An Bras Dermatol*. 2011; 86 (1):65-73.
5. Barry B, McKenzie J, Berg D, Langtry J. Direct primary closure without undermining in the repair of vermilionectomy defects of the lower lip. *British Association of Dermatologists* 2012 167, pp1092–1097.

A rare biliary cyst – Todani type I

Quisto biliar raro – Todani tipo I

Ana Lontro da Cruz, Ana Canoso, Bernardo Maria, Andreia Barão, Carlos Miranda, João Coutinho
Serviço de Cirurgia Geral, Hospital de Santa Maria, Centro Hospitalar Lisboa Norte

Abstract

We present a surgical management of a rare case of biliary cyst type I (Todani classification) in an adult with recurrent epigastric pain, nausea, vomiting and weight loss. A biliary cyst with fusiform dilation of the entire extrahepatic bile duct and duodenal compression was diagnosed by ultrasound and computed tomography. During surgery we faced another biliary malformation, the sectorial drainage of the hepatic ducts directly onto the hepatic duct. In this case, we performed a resection of the cyst through a right subcostal incision and a Roux-en-Y hepato-jejunostomy leaving a small part of the proximal cyst in place, in order to make the hepatojejunal anastomosis possible. Albeit biliary cyst is a rare, biliary malformations/variations are one of the most common in the human anatomy, with a high probability of one patient having multiple malformations, such as in the present case, requiring slight changes to the usual surgical management.

Keywords: biliary cyst; Todani; biliary ducts malformations

Resumo

Apresentamos a abordagem cirúrgica de um caso raro de quisto biliar tipo I (classificação de Todani) num adulto que apresentava dor epigástrica recorrente, náusea, vómitos, perda de peso e um diagnóstico imagiológico, por ecografia e TC abdominal, de um quisto biliar com dilatação fusiforme do ducto extra-hepático com compressão duodenal. Durante a cirurgia, fomos confrontados com a presença de outra malformação biliar, a drenagem sectorial dos ductos hepáticos diretamente no ducto hepático. A doente foi submetida a ressecção do quisto através de uma incisão subcostal direita com reconstrução com hepatojejunostomia em Roux-en-Y, deixando, no entanto, parte do quisto proximal e tornando assim possível a anastomose hepatojejunal. Apesar dos quistos biliares serem entidades raras, as malformações biliares são das mais comuns na anatomia humana, com grande probabilidade de presença de múltiplas malformações no mesmo doente, como no caso apresentado, exigindo alterações na abordagem cirúrgica habitual.

Palavras-chave: quisto biliar, Todani, malformação dos ductos biliares

Introduction

Biliary cysts are rare congenital cystic dilations that may occur individually or spread throughout the biliary tree. It may affect only the extrahepatic bile duct (type I, II and III), intrahepatic

(type V) or both (type IV [1] The incidence of biliary cysts varies by region, occurring in about 1 per 1000 in Asia but only 1 per 100,000 to 150,000 in the Western world [2] and are more common in women, with a female to male ratio of 3:1 to 4:1 [1,3].

Classically, they are diagnosed in children, though they can be diagnosed in adults [4]. Presentation in adults often includes abdominal pain, nausea, vomiting, cholelithiasis, cholangitis, pancreatitis or malignancy [4,5]. These are vague symptoms that can be misleading in the adult patient.

Biliary cysts are associated with an increased risk of cancer, particularly cholangiocarcinoma [6]. The incidence of malignancy varies with age and with the type of cyst, being the type I and IV the types with the highest risk [7].

Hereby we discuss a rare case of a biliary cyst that presented with recurrent epigastric pain, nausea, vomiting and weight loss. An ultrasound and an abdomen CT scan revealed a biliary cyst with fusiform dilation for the entirety of the extrahepatic bile duct (maximum dilatation of 60,1 mm), type I based on the Todani classification, with duodenal compression.

Case Report

An African, 38-year-old, female patient referred to our institution from Cape-Verde, with the diagnosis of a biliary cyst on an ultrasound and an abdominal CT scan, after multiple episodes of epigastric pain, nausea, vomiting and weight loss. The images were reviewed at our institution and the biliary cyst was classified as a type I of Todani classification, conditioning a molding on the 1st and 2nd portion of the duodenum.

The patient was admitted for surgical management, and was performed cholecystectomy, resection of the cyst and reconstruction with a *roux-en-y* hepaticojejunostomy, through a right subcostal incision.

During the surgery with the opening of the cyst, multiple choledocholithiasis were encountered and another biliary malformation was observed. The hepatic duct was not the result of the confluence of the right and left hepatic ducts, but it had multiple duct openings instead, giving the idea of independent sectorial ducts all ending at the beginning of the common hepatic duct. Due to this abnormal confluence of the hepatic biliary ducts a small part of the proximal cyst was left in place so that the hepaticojejunostomy was possible. No significant blood loss was accounted. The surgery lasted about three hours.

There were no complications, and the patient was discharged on the 6th day *post op*, with resolution of all the symptoms.

Discussion

Five types of biliary cysts are known [1]. According to the literature the ultrasound is an important auxiliary method for the diagnosis of choledochal cyst type I. However, one of its limitations is that it largely depends on the experience of the radiologist. Unlike ultrasound, computed tomography (CT) can detect all types of biliary cysts. It can demonstrate the continuity of the cyst

with the biliary tree, the relationship between the cyst and surrounding structures, and evaluate the presence of malignancy. It is also useful for determining the extent of intrahepatic disease in patients with type IV or V cysts [8,9].

Diagnosis and the surgical management of biliary cysts are important due to its potential to develop cholangiocarcinoma, mainly on type I and type IV biliary cysts, evidence clearly points to a 20- to 30-fold increased risk of cholangiocarcinoma in biliary cysts compared with the general population [10,11]. However, the risk of carcinoma is decreased in patients who have undergone cyst resection, these patients continue to be at an increased risk of carcinoma compared with the general population. Post excisional malignant disease is seen in 0.7 to 6 percent of patients and may be due to remnant cyst tissue or subclinical malignant disease that was not detected prior to cyst excision [12,13]. Malignancy may even develop in portions of cysts that were left behind at surgery, at the anastomotic site, or in the pancreas [14,15].

For patients with type I cysts, complete resection of the cyst was performed together with reconstruction with a hepaticojejunostomy, which is the standard procedure. But rare studies on adults are available. Unfortunately, the management efficiency for the other three types of choledochal cysts is still not well defined [1].

Biliary cysts are a well described, although rare clinical entity. We present the management of a biliary cyst type I in an adult, in which we can also see another biliary malformation – the sectorial drainage of the intrahepatic ducts directly onto the hepatic duct.

In this case, we performed a resection of the cyst through a right subcostal incision and Roux-en-Y hepaticojejunostomy was fashioned. However, we had to leave a small part of the proximal cyst in place so that we could do the hepaticojejunal anastomosis. The rest of the surgery was uneventful, and no recurrence or postoperative complications were reported in the 6 months follow up. There was complete resolution of the symptoms and the patient will be maintained under surveillance.

Conclusion

Biliary cysts are a rare congenital malformation of the biliary ducts. The most common are the type I cysts, according to the Todani Classification. They represent a higher risk of malignancy, so all type I cysts have indication for total resection when possible, even when they are asymptomatic [1].

Biliary malformations/variations are the one of the most common variations in the human anatomy, and usually, when there is one, there is a higher probability of other malformations [2]. We observed this in this patient, whom not only had a biliary cyst but also an abnormal confluence of the biliary ducts which made us slightly change the usual surgical management.

This surgery may be done by laparotomy or laparoscopy, being the laparoscopic approach reserved for high volume centers where there are highly experienced laparoscopic biliary ducts surgeons. Laparotomy is a well-established approach, with almost no disadvantages besides the worse cosmetic outcome and slower return to normal activities [16].

The patient is asymptomatic after 5 months of follow-up and will be kept under surveillance.

References

1. Todani T, Watanabe Y, Narusue M, et al. Congenital bile duct cysts: Classification, operative procedures, and review of thirty-seven cases including cancer arising from choledochal cyst. Am J Surg 1977; 134:263.
2. Keplinger K.M., Bloomston, M.; Anatomy and Embryology of the of biliary tracts; Surg Clin N Am 94 (2014) 203–217
3. Singham J, Yoshida EM, Scudamore CH. Choledochal cysts: part 1 of 3: classification and pathogenesis. Can J Surg 2009; 52:434.
4. Ronnekleiv-Kelly S.M., Soares K.C., Ejaz A., Pawlik T.M. Management of choledochal cysts. Curr. Opin. Gastroenterol. 2016
5. Soares K.C., Kim Y., Spolverato G. Presentation and clinical outcomes of choledochal cysts in children and adults: a multi-institutional analysis. JAMA Surg. 2015;150:577–584.
6. Søreide K, Søreide JA. Bile duct cyst as precursor to biliary tract cancer. Ann Surg Oncol 2007; 14:1200.
7. Todani T, Tabuchi K, Watanabe Y, Kobayashi T. Carcinoma arising in the wall of congenital bile duct cysts. Cancer 1979; 44:1134.
8. Akhan O, Demirkazik FB, Ozmen MN, Ariyürek M. Choledochal cysts: ultrasonographic findings and correlation with other imaging modalities. Abdom Imaging 1994; 19:243.
9. Lam WW, Lam TP, Saing H, et al. MR cholangiography and CT cholangiography of pediatric patients with choledochal cysts. AJR Am J Roentgenol 1999; 173:401.
10. Søreide K, Søreide JA. Bile duct cyst as precursor to biliary tract cancer. Ann Surg Oncol 2007; 14:1200.
11. Todani T, Tabuchi K, Watanabe Y, Kobayashi T. Carcinoma arising in the wall of congenital bile duct cysts. Cancer 1979; 44:1134.
12. Kobayashi S, Asano T, Yamasaki M, et al. Risk of bile duct carcinogenesis after excision of extrahepatic bile ducts in pancreaticobiliary maljunction. Surgery 1999; 126:939.
13. Watanabe Y, Toki A, Todani T. Bile duct cancer developed after cyst excision for choledochal cyst. J Hepatobiliary Pancreat Surg 1999; 6:207.
14. Kurokawa Y, Hasuike Y, Tsujinaka T, et al. Carcinoma of the head of the pancreas after excision of a choledochal cyst. Hepatogastroenterology 2001; 48:578.
15. Tsuchida A, Kasuya K, Endo M, et al. High risk of bile duct carcinogenesis after primary resection of a congenital biliary dilatation. Oncol Rep 2003; 10:1183.
16. Zhen C., Xia Z., Long L., Lishuang M., Pu Y., Wenjuan Z., Xiaofan L. Laparoscopic excision versus open excision for the treatment of choledochal cysts: a systematic review and meta-analysis. Int. Surg. 2015;100:115–122

Imagens

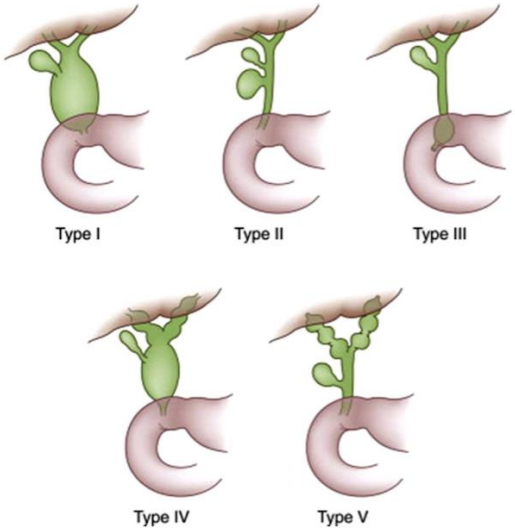

Fig 1: Todani Classification of biliary cysts (From Sabiston DC, Townsend CM. Sabiston textbook of surgery: the biological basis of modern surgical practice. 19th edition. Philadelphia: Elsevier Souders; 2012)

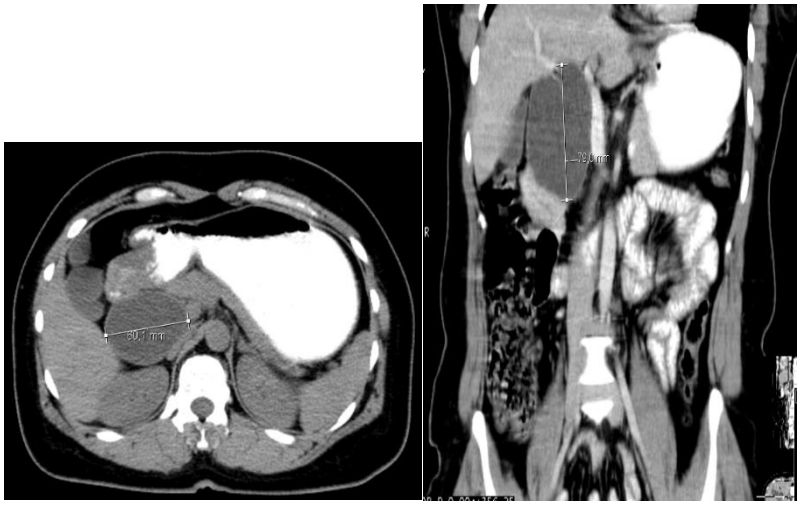

Fig. 2: CT scan: axial view of the biliary cyst in its middle portion – 60,1 mm of diameter; coronal view of the biliary cyst involving the extrahepatic biliary duct, molding the 1st and 2nd portion of the duodenum

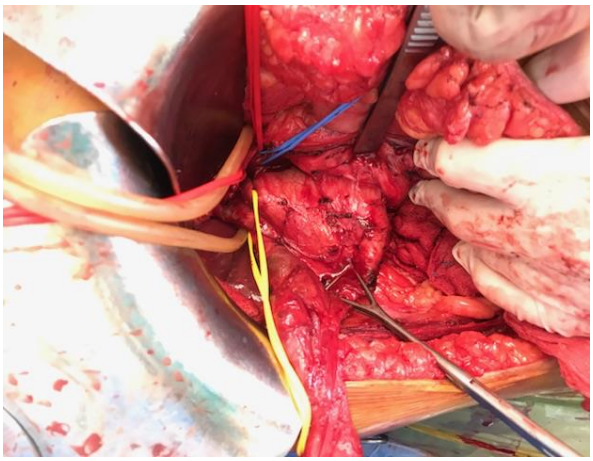

Fig. 3: Intra-operatory view of the biliary cyst

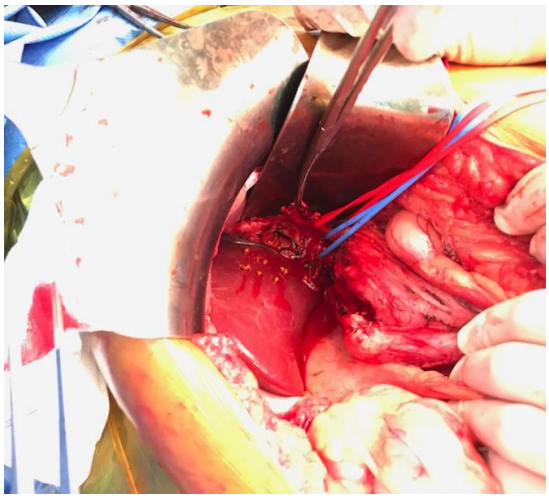

Fig. 4: Intra-operatory view of the resected biliary cyst; choledocholithiasis; hepatic duct opened

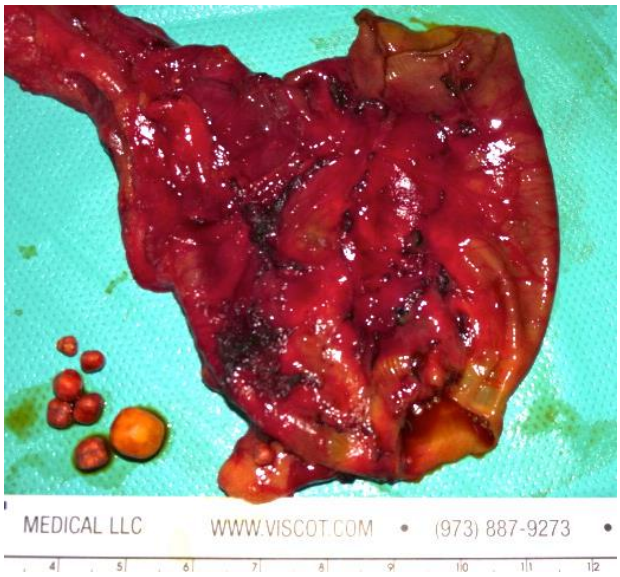

Fig.5: Biliary cyst after resection

Unilateral facial nerve palsy in the setting of Waldenström Macroglobulinemia: an unusual association

Parésia Facial Unilateral no contexto de Macroglobulinémia de Waldenström: uma associação pouco habitual

Marta Leal Bento, Pedro de Vasconcelos M, Daniela Alves, Sara Valle, Helena Martins, João Raposo

Departamento de Hematologia e Transplante de Medula Óssea, Hospital de Santa Maria, Centro Hospitalar Lisboa Norte

Resumo

A Macroglobulinémia de Waldenström é uma doença linfoproliferativa indolente caracterizada por um linfoma linfoplasmocítico com infiltração da medula óssea e produção de IgM monoclonal.

O envolvimento do sistema nervoso ocorre em 22% dos casos e as manifestações típicas incluem polineuropatia sensitiva autoimune e sintomas de hiperviscosidade. Menos frequentemente poderão ocorrer infeções virais, neurolinfomatose, síndrome de Bing-Neel ou neurotoxicidade. A parésia facial periférica é uma manifestação rara, esporadicamente descrita na literatura. O seu aparecimento isolado e unilateral não foi descrito até à data associado à Macroglobulinémia de Waldenström.

Apresentamos o caso de um doente de 57 anos, diagnosticado com Macroglobulinémia de Waldenström, que desenvolveu uma parésia facial unilateral isolada. Na investigação foi detetada replicação de Citomegalovírus, não tendo sido possível excluir o síndrome de Bing-Neel ou neurotoxicidade.

Este caso salienta a raridade desta associação e a incerteza em torno das implicações da parésia facial isolada em doentes com Macroglobulinémia de Waldenström.

Palavras-chave: Macroglobulinemia Waldenstrom, paralisia facial unilateral periférica, Síndrome Bing-Neel, linfoma linfoplasmocitico

Abstract

Waldenström Macroglobulinemia is an indolent B-cell lymphoproliferative disorder characterized by lymphoplasmacytic lymphoma bone marrow infiltration and IgM monoclonal gammopathy.

Nervous system involvement occurs in approximately 22% of the cases and the typical abnormalities include autoimmune sensory polyneuropathy and hyperviscosity symptoms. Less frequently, viral infection, neurolymphomatosis, Bing-Neel syndrome and drug neurotoxicity can occur. Peripheral facial palsy is an unusual manifestation, sporadically described in the literature. The association of Waldenström Macroglobulinemia with isolated unilateral peripheral facial palsy has not been reported so far.

We present the case of a 57-year old patient with the diagnosis of Waldenström Macroglobulinemia, who developed a unilateral facial nerve palsy during hospitalization for progressive disease. Workup detected Cytomegalovirus replication but Bing-Neel syndrome and neurotoxicity could not be excluded.

This case highlights the uniqueness of the association and the uncertain implications that an isolated facial palsy has in the setting of Waldenström Macroglobulinemia.

Key words: Waldenström Macroglobulinemia, unilateral peripheral facial palsy, Bing-Neel syndrome, lymphoplasmocytic lymphoma

Introduction

Waldenström Macroglobulinemia (WM) is an indolent B-cell lymphoproliferative disorder characterized by a lymphoplasmacytic lymphoma (LPL) with at least 10% bone marrow infiltration and an IgM monoclonal gammopathy [1]. Its clinical presentation relates closely with tumorous infiltration and paraproteinemic features.

Nervous system involvement is a well described feature of the disease and most commonly manifests as peripheral neuropathy (PN). In fact, approximately 20% of the patients present with symptoms of PN at diagnosis and up to half are eventually affected during the course of the disease [2]. The WM-associated PN is predominantly sensorial, with distal and symmetric loss of large and small fibers, with vibration sense loss and tandem gait disorder but unaffected strength [3]. Strong evidence suggests that IgM antibodies with neural target antigen, such as the anti-myelin-associated glycoprotein (MAG), are the main culprits of this sensory and ataxic demyelinating neuropathy [4]. Chemotherapy-induced PN, particularly Bortezomib, should also be considered in the cases where neurotoxic therapy has been used. Cranial nerve involvement is considered an atypical neurologic feature and suggests other causes such as central nervous system (CNS) infiltration with meningeal involvement, neurolymphomatosis or infection [5]. Bing-Neel syndrome (BNS) is a rare manifestation of WM, characterized by CNS infiltration by LPL cells, which can be confirmed by biopsy or cerebrospinal fluid (CSF) analysis [6]. According to a multi-institutional retrospective study, approximately 29% of the patients diagnosed with BNS presented cranial nerve symptoms [7]. Another study reported that cranial nerve involvement, with predominance of the facial and oculomotor nerves, was the second most common sign that led to the diagnosis of BNS [8].

After a review of the literature, the authors detected an extreme paucity of reported isolated cranial neuropathies in the setting of WM. To our knowledge, six cases are published but unilateral facial palsy was described only once (in association with a bilateral orbital mass) [9]. Isolated and unilateral facial nerve involvement, with no other neurologic abnormalities, has not been reported so far in the literature.

We present the case of a 57-year old patient, with a known diagnosis of WM, who developed an isolated unilateral facial nerve palsy during hospitalization for progressive disease. This report highlights the complex diagnostic approach and implications of cranial nerve neuropathy in the setting of WM and also the uniqueness of the manifestation.

Clinical case

A 57-year old african man, with a known history of Waldenström macroglobulinemia, was followed by the haematology department.

Initially, the patient presented with pancytopenia, splenomegaly, multiple axillary lymphadenopathies and a large conglomerate of retroperitoneal lymphadenopathies. Investigation revealed a 14,1g/dL gamma spike in the protein electrophoresis and an IgM/kappa immunofixation of 2,88g/dL. Serologic tests were negative for HIV 1-2, HTLV-1, *Toxoplasma gondii*, Hepatitis B, Hepatitis C and Hepatitis E and positive for IgG Epstein-Barr and IgG Hepatitis A. Bone marrow was hypercellular with 82% infiltration by mature B cells. Axillary lymph node biopsy revealed a non-Hodgkin lymphoma with morphology and immunophenotype compatible with LPL. MYD88 (L265P) mutation was absent. Based on these findings, a diagnosis of Waldenstrom's macroglobulinemia was made.

Treatment was started with 8 cycles of the R-CHOP chemotherapy protocol (Rituximab, Cyclophosphamide, Doxorubicin, Vincristine and Prednisone). A partial response was obtained as the retroperitoneal lymphadenopathies remained unchanged and the IgM/kappa immunofixation was still 1,21g/dL.

Two years later, progression was noted by Computed Tomography (CT) that detected an enlargement of the retroperitoneal conglomerate, hepatosplenomegaly and development of a left chylothorax (Figure 1).

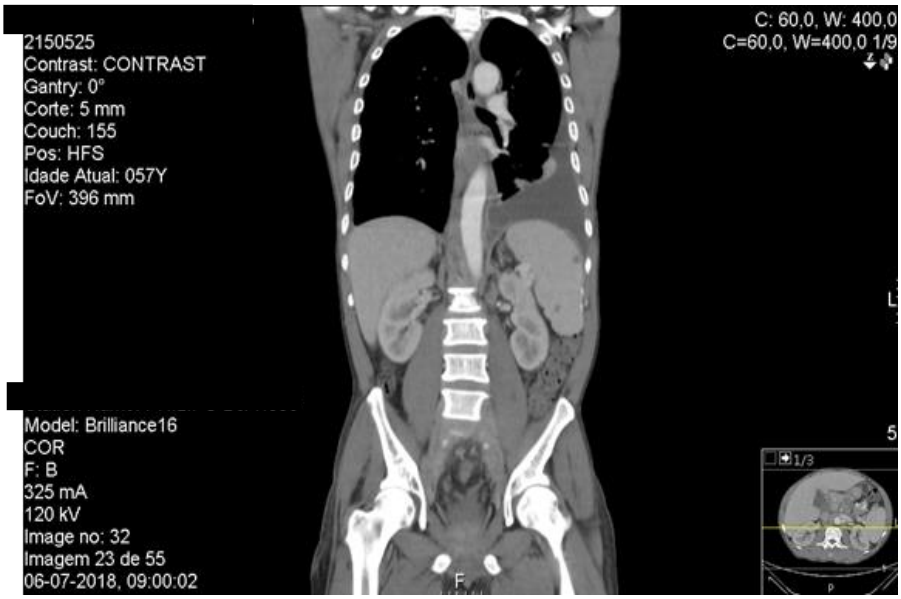

Figure 1. Coronal plane thoraco-abdominal-pelvic CT scan: left chylothorax and hepatosplenomegaly.

Second-line therapy was implemented with Ibrutinib leading to resolution of the chylothorax. However, only a minor response was obtained, as the enlarged lymph nodes persisted for 6 months and the IgM/kappa immunofixation was 1,049mg/dL. No further treatment was proposed because the patient was clinically stable. Progression-free disease lasted for three years.

The patient then presented to follow up consultation with a relapsed left pleural effusion and a slight lymphadenopathy enlargement. Therefore third-line chemotherapy with BRD (Bortezomib

1.3-1.6mg/m^2, Dexamethasone 40mg and Rituximab 375mg/m^2) was started for progressive disease. Soon after the end of the first cycle, there was an increase of the effusion which did not regress with the use of corticosteroids. The patient was then hospitalized in the hematology ward due to development of respiratory failure.

During hospitalization the patient initiated IV antibiotic therapy and thoracentesis was performed. Pleural fluid citology detected an elevated cell count with predominance of lymphocytes (some of them with dysmorphic features). After resolution of the infectious intercurrence, the second cycle of BRD was started. Revaluation thoracic-abdominal-pelvic CT revealed thoracic and supraclavicular lymphadenopathies, enlargement of the retroperitoneal lymphadenopathy conglomerate with extension to the pelvic cavity, large hepatosplenomegaly and bilateral pleural effusion. These findings demonstrated refractory disease to the BRD regimen which was suspended. Fourth line chemotherapy with Cladribine was initiated.

Between the third and fourth line of chemotherapy (and five days after the last Bortezomib administration) the patient complained of progressive left facial paraesthesia and hypoesthesia, left xeropthalmia, bilateral ear fullness and hypogeusia. Neurological examination revealed incomplete left eyelid closure and flattening of the left forehead and nasolabial fold. These signs were most evident when the patient was asked to smile and raise the eyebrows. This clinical picture was highly suggestive of left peripheral facial palsy (Figure 2).

Figure 2. Left facial palsy. Flattening of the left forehead and nasolabial fold is observed.

The remaining neurologic examination revealed tactile and algic hypoesthesia on the left trigeminal nerve territory, right lateralization on the Weber test and a positive bilateral Rinne test. Evaluation was unremarkable for palate elevation, tongue motility, movement coordination, gait, vibratory sensitivity and Barre or Mingazinni tests. No skin lesions were visible on the face or external ears. Otoscopy was not performed. A House-Brackmann grade IV peripheral left facial palsy with auditory neurossensorial impairment was diagnosed.

After consultation with the neurology department, investigation was pursued with Brain Magnetic Ressonance Imaging (MRI) and blood work. MRI T2 images detected bilateral mastoid filling by hyperintense material and a possible air-fluid level in the right mastoid. It was unremarkable

for lesions in the encephalic parenchyma, cephalospinal fluid spaces, cerebellopontine angle cistern or labyrinth. There was no thickening of the leptomeningeal sheaths nor of the seventh cranial nerves (Figure 3).

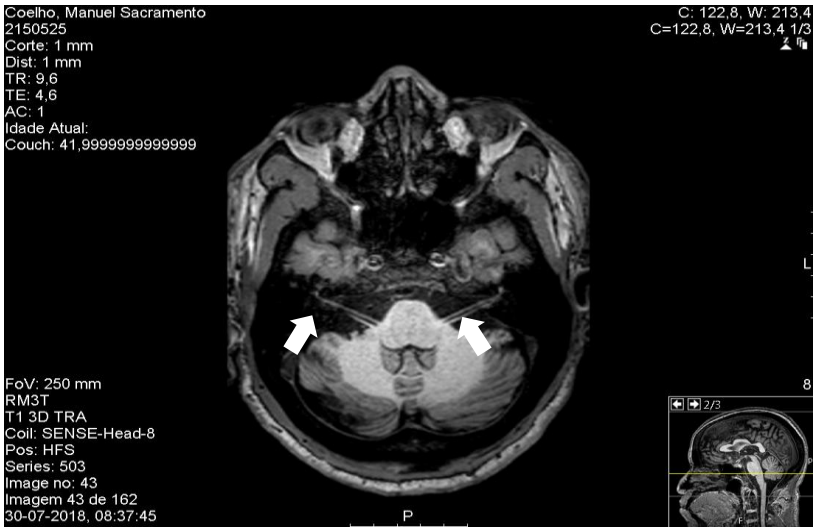

Figure 3. Brain MRI: absence of seventh cranial nerve thickening.

Leptomeningeal or cranial nerve enhancement could not be assessed as gadolinium contrast was not used. CMV DNA, which was previously undetectable, was quantified in the patient's sera at less than 150 copies/mL. Serology and DNA quantification for Herpes Simplex Virus were not performed. The remaining laboratory workup was unremarkable. Lumbar puncture was not performed because viral infection was assumed as the cause of the palsy.

The patient was already on corticosteroids and antiviral therapy with acyclovir, therefore no further pharmacological measures were undertaken. A motor rehabilitation program with localized physical therapy was initiated.

Treatment with Cladribine went through no major toxicities. Seven days later, a slight improvement of the palsy was noted and the patient was discharged to outpatient follow-up.

On short term follow-up, the patient presented with a slight improvement of the facial palsy with maintenance of a mild dysfunction (Grade II on the House-Brackmann scale). CMV DNA was undetectable. The remaining laboratory workup was unremarkable.

The patient's response to Cladribine has not been evaluated so far.

Discussion

Waldenström macroglobulinemia is a rare indolent lymphoproliferative disorder defined by a lymphoplasmacytic lymphoma with bone marrow involvement and an IgM gammopathy [1].

Clinical presentation is related with the degree of hematopoietic and non-hematopoietic LPL infiltration and the behaviour of the IgM paraprotein. A large series reported that approximately 20% of WM patients were asymptomatic at presentation. The most common described abnormalities were

anemia, hyperviscosity, B symptoms, bleeding and neurologic symptoms. Specifically, nervous system involvement occurred in 22% of the patients [2].

Several pathophysiological mechanisms are implicated in the development of the neurologic abnormalities found in WM.

Plasma IgM, with a median concentration of 5000mg/dL, predictably produces hyperviscosity at considerably lower levels than its IgG and IgA counterparts [10]. The classic triad of acute hyperviscosity is composed of mucosal bleeding, visual disturbances and neurological abnormalities. The syndrome occurs in as many as 30% of WM patients [1].

Peripheral neuropathy (PN) is present at diagnosis in 20% of WM patients and up to 50% are affected during the course of the disease [3]. There is strong evidence that this PN results from the paraprotein's antibody activity against neural antigens, especially myelin-associated glycoprotein (MAG) [4]. It usually presents as a distal, chronic, symmetric and sensory polyneuropathy. Atypical presentation such as cranial nerve involvement, asymmetrical distribution or sudden onset should prompt investigation of causes other than autoimmunity [5].

Neurotoxicity should also be taken in consideration in the cases where chemotherapy is used. Chemotherapy-induced polyneuropathy is a common complication of the BRD regimen, mainly due to Bortezomib's toxicity profile. PN is reported in almost half of the WM patients treated with BRD [11]. Bortezomib-induced polyneuropathy usually consists of neuropathic pain and sensory loss of the fingertips and toes [12]. Onset of symptoms is related to the cumulative dose of the drug (at a median concentration of 30mg/m^2) and is usually noted after a few cycles of treatment [13].

Central nervous system infiltration by LPL, also known as Bing-Neel syndrome (BNS), is a rare but serious complication of WM. Although it can occur at first diagnosis, it usually presents as a feature of relapsing disease [14]. In a large retrospective study, cranial nerve involvement, with predominance of facial and oculomotor nerves, was the second most common sign that led to the diagnosis of BNS [8]. Leptomeningeal infiltration may manifest with cranial neuropathy and can be detected by meningeal enhancement on MRI. This finding, although highly suggestive, does not confirm the diagnosis. Likewise, absence of MRI findings does not exclude BNS. Biopsy of the affected structure and/or cephalospinal fluid analysis provide evidence for definitive diagnosis [6]. Peripheral nerve infiltration by lymphoma cells, also known as neurolymphomatosis, is a rare event and published data on its association with WM is scarce.

After review of the literature, isolated cranial neuropathy in association with WM was found in six reports [9, 15-19]. To the best of our knowledge, the present report is the first described case of an isolated and unilateral facial palsy in association with WM.

Regarding our patient, it is clear that his clinical course was mostly defined by LPL infiltration rather than by paraproteinemic features. In theory, the development of the facial nerve palsy should also be related to infiltration. Although definitive aetiology could not be specified, one can speculate on the underlying mechanism.

Given the progressive and refractory course of the patient's disease, it is not possible to exclude BNS or neurolymphomatosis. A diffuse form of central nervous system infiltration with meningeal and/or cranial nerve involvement could explain the development of a facial palsy. However, MRI did not reveal thickened facial nerves or meningeal sheaths and, as the exam was

performed without contrast, structural enhancement could not be assessed. As previously mentioned, the absence of imaging findings does not exclude the diagnosis. Lumbar puncture with CFS analysis or contrasted MRI would provide relevant information.

Hyperviscosity was excluded as a contributing factor because the paraprotein's concentration was never close to 5000mg/dL. Even after Rituximab administration, which is acknowledged to predictably cause symptomatic paraprotein flares [20], there were no suggestive signs.

The classical WM-associated PN affects the extremities and is symmetrical in distribution and chronic in course. Facial nerve involvement, sudden onset and absent distal sensory defects were considered rather atypical features to relate to an eventual anti-MAG neuropathy. From a clinical standpoint, anti-MAG serology was not found to be a justifiable exam as the diagnostic suspicion was very low.

Bortezomib's neurotoxicity may have contributed to the development of the facial palsy, despite the atypical neuropathy location and the low cumulative dose of the drug at the time of onset. One can speculate that the patient's left facial nerve was already susceptible to drug toxicity, thus justifying the tropism.

Detection of CMV DNA (less than 150 copies) initially suggested facial nerve viral infection, however this finding could have only reflected breakthrough subclinical viral replication in the setting of transitory immunodeficiency (iatrogenic and disease-related).

In summary, development of the unilateral facial palsy was probably multifactorial. Firstly, progressive and refractory disease with sudden and asymmetrical cranial nerve involvement suggests possible lymphomatous infiltration that was silent up to that moment. Secondly, filling of the mastoids could explain additional facial nerve susceptibility to injury as a considerable portion of the nerve passes through this bone. Finally, Bortezomib was probably the last trigger that turned a subclinical left facial nerve injury into an overt facial nerve palsy. Regarding CMV, it is rather difficult to assess whether the viral replication led to facial nerve infection or not.

Conclusion

Development of peripheral facial palsy in the setting of Waldenström macroglobulinemia creates a complex diagnostic differential with prognostic implications. Central nervous system infiltration is a rare but serious complication of WM. We highlight the fact that although definitive aetiology of a peripheral facial palsy has always been a challenge to clinicians, its presence in association of WM warrants consideration of Bing-Neel syndrome. Isolated and unilateral facial palsy has uncertain implications in this setting due to its uniqueness. Regardless, neurologic deficit progression and accumulating disabilities should prompt diagnostic and therapeutic measures.

References

1. Swerdlow SH, Campos E, Pileri SA et al. WHO Classification of Tumour of Haematopoietic and Lymphoid Tissues. Lyon, France: IARC Press; 2017

2. García-Sanz R, Montoto S, Torrequebrada A, et al. Waldenström macroglobulinaemia: presenting features and outcome in a series with 217 cases. *Br J Haematol* 2001; 115:575.
3. Levine T, Pestronk A, Florence J, et al. Peripheral neuropathies in Waldenström's macroglobulinaemia. Journal of Neurology, Neurosurgery & Psychiatry 2006;77:224-228.
4. Nobile-Orazio, E., Marmiroli, P., Baldini, L., Spagnol, G., Barbieri, S., Moggio, M., ... & Scarlato, G. (1987). Peripheral neuropathy in macroglobulinemia Incidence and antigen-specificity of M proteins. *Neurology*, *37*(9), 1506-1506
5. D'Sa, S., Kersten, M. J., Castillo, J. J., Dimopoulos, M. , Kastritis, E. , Laane, E. , Leblond, V. , Merlini, G. , Treon, S. P., Vos, J. M. and Lunn, M. P. (2017), Investigation and management of IgM and Waldenström-associated peripheral neuropathies: recommendations from the IWWM-8 consensus panel. Br J Haematol, 176: 728-742.
6. Minnema, M.C., Kimby et al., (2016) Guideline for the diagnosis, treatment and response criteria for Bing Neel syndrome. Haematologica, October 2016
7. Castillo JJ, D'Sa S, Lunn MP, et al. Central nervous system involvement by Waldenström macroglobulinaemia (Bing-Neel syndrome): A multi-institutional retrospective study. *British journal of haematology*. 2016;172(5):709-715.
8. Simon L, Fitsiori A, Lemal R, et al. Bing Neel syndrome: a rare complication of Waldenstrom macroglobulinemia: analysis of 44 cases and review of the literature. A study on behalf of the French Innovative Leukemia Organization (FILO). Haematologica. 2015; 100(12): 1587-1594
9. Kumar S, Das S, Goyal JL, Chauhan D, Sangit V. Bilateral orbital tumor formation and isolated facial palsy in Waldenstrom's Macroglobulinemia. Int Ophthalmol 2005;26(6):235–7.
10. Morie A. Gertz et al. Acute Hyperviscosity: Syndromes and Management. *Blood* 2018
11. Dimopoulos, M. A., García-Sanz, R., Gavriatopoulou, M., Morel, P., Kyrtsonis, M., Michalis, E., Kartasis, Z., Leleu, X., Palladini, G., Tedeschi, A., Gika, D., Merlini, G., Kastritis, E., & Sonneveld, P. (2013). Primary therapy of Waldenström macroglobulinemia (WM) with weekly bortezomib, low-dose dexamethasone, and rituximab (BDR): long-term results of a phase 2 study of the European Myeloma Network (EMN). *Blood,* 122(19), 3276-3282.
12. Argyriou AA, Cavaletti G, Bruna J, Kyritsis AP, Kalofonos HP (2014). Bortezomib-induced peripheral neurotoxicity: an update. Arch Toxicol 88: 1669–1679.
13. Richardson PG, Briemberg H, Jagannath S, et al. Frequency, characteristics, and reversibility of peripheral neuropathy during treatment of advanced multiple myeloma with bortezomib. J Clin Oncol 2006;24:3113-3120.
14. Malkani RG, Tallman M, Gottardi-Littell N et al. Bing-Neel syndrome: an illustrative case and a comprehensive review of the published literature. J Neurooncol. 2010;96(3):301-312.
15. Bhatti MT, Yuan C, Winter W, McSwain AS, Okun MS. Bilateral sixth nerve paresis in the Bing-Neel syndrome. Neurology 2005;64(3):576–7.
16. Lamarca J, Casquero P, Pou A. Mononeuritis multiplex in Waldenström's Macroglobulinemia. Ann Neurol 1987;22(2):268–72.
17. Moulis H, Mamus SW. Isolated trochlear nerve palsy in a patient with Waldenström's Macroglobulinemia: complete recovery with combination therapy. Neurology 1989;39(10):1399.
18. Sánchez-orgaz M, Spiess K, Canales-albendea MA, Arbizu-duralde A, Romeromartín R, Clos PM. Acta Haematologica Polonica Bilateral peripheral facial palsy secondary to Waldenstrom as Macroglobulinemia. A case report and literature review. Acta Haematol Pol 2014;45(4):374–7.
19. Torreabalda-Acosta G, Gashia R, Leslie-Mazwi T,. A rare neurological complication of Waldenstrom's macroglobulinemia. Journal of clinical neuroscience 2018.

20. Noronha V, Fynan TM, Duffy T. Flare in neuropathy following rituximab therapy for Waldenstrom's macroglobulinemia. J Clin Oncol. 2006;24(1):E3

Acknowledgements

We acknowledge the active participation of all the Department of Hematology and Bone Marrow Transplantation, Centro Hospitalar Lisboa Norte in the care for the patient, in particular Sara Valle, Helena Martins and Graça Esteves for in-patient care, diagnosis and treatment. Also, for the careful follow-up in the day-hospital by Daniela Alves.

Also we thank the Department of Neurology for the prompt response when needed in the diagnosis and treatment of Neurological symptoms.

Radiation Recall Dermatitis num Cancro da Mama Localmente Avançado

Radiation Recall Dermatits in Locally Advanced Breast Cancer

Diogo Delgado[1], André Figueiredo[1], Vera Mendonça[1], Marília Jorge[1], Miriam Abdulrehman[1], Pedro Simões[2], Mafalda Casa-Nova[2], Maria Filomena de Pina[1]

1 – Serviço de Radioterapia do Centro Hospitalar Lisboa Norte E.P.E.; 2 – Serviço de Oncologia Médica do Hospital Beatriz Ângelo

Resumo

A *radiation recall dermatitis* é uma reacção cutânea aguda que ocorre numa área previamente irradiada após a administração de fármacos, mais frequentemente de quimioterapia. Apresenta-se um caso de uma doente com tumor da mama localmente avançado, submetida a quimioterapia neo-adjuvante com fraca resposta clínica. Por hemorragia tumoral não controlada, é encaminhada ao Serviço de Radioterapia, onde se opta por realizar tratamento hemostático neo-adjuvante, resultando numa ressecção cirúrgica completa. Ao iniciar quimioterapia adjuvante, desenvolve uma dermatite intensa na área correspondente aos campos de irradiação. Com este caso pretendemos alertar para a presença deste fenómeno e mostrar os resultados de uma abordagem menos frequente numa doente com tumor da mama localmente avançado.

Palavras chave: Radiation Recall Dermatitis, mama, radioterapia, oncologia.

Abstract

Radiation recall dermatitis is an acute skin reaction on a previously irradiated site brought on by the administration of medication, most frequently chemotherapy. Hereby, we present a case of locally advanced breast cancer treated with neoadjuvant chemotherapy and a poor clinical response. Because of uncontrolled tumor bleeding, the patient is referred to the Radiotherapy Department where she is treated with hemostatic and neoadjuvant intent, resulting in a complete resection in surgery. When the patient begins adjuvant chemotherapy, an intense skin rash occurs on the radiation field's site. The goal of this case is to raise awareness to this phenomenon and demonstrate a less frequent approach to locally advanced breast cancer.

Keywords: Radiation Recall Dermatitis, breast, radiotherapy, oncology.

Introdução

A *radiation recall dermatitis* é um fenómeno incomum e imprevisível caracterizado por uma reacção inflamatória aguda, confinada a uma região cutânea previamente irradiada, após a administração de fármacos sistémicos precipitantes [1]. A sua fisiopatologia não é totalmente conhecida, no entanto vários mecanismos foram propostos, nomeadamente, alterações da

vascularização, da reparação de DNA ou da função epitelial das células estaminais [2]. Embora este efeito esteja mais frequentemente associado a fármacos citotóxicos, entre eles a doxorrubicina, docetaxel, paclitaxel, gemcitabina ou capecitabina, pode igualmente ocorrer com a toma de antibióticos, tuberculostáticos, tamoxifeno ou sinvastatina [3].

A incidência deste fenómeno é difícil de estimar, no entanto alguns estudos retrospectivos colocam-na entre os 8,8% e 11% [1].

O caso clínico apresentado em seguida, para além de ilustrar e alertar para a existência do efeito de *radiation recall dermatitis*, mostra uma abordagem menos comum no tratamento do cancro da mama localmente avançado e que conduziu à manifestação deste fenómeno.

Caso clínico

Doente de 62 anos, sexo feminino, que recorre ao Serviço de Urgência por ulceração cutânea e hemorragia activa decorrente de lesão da mama direita com 6 meses de evolução. Ao exame objectivo, apresentava uma mama direita volumosa substituída na quase totalidade por tumor com cerca de 10cm, apresentando nos quadrantes inferiores pele violácea com zonas ulceradas e sangrantes (figura 1). Imagiologicamente era uma lesão sólida com áreas necróticas e espessamento da pele e tecido celular subcutâneo associado (figura 2). Não apresentava adenopatias.

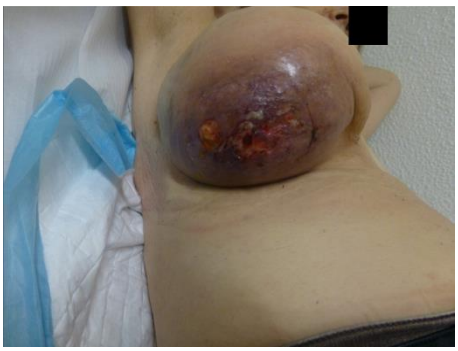

Fig. 1 Tumor à apresentação

Realizou biopsia, com diagnóstico histológico de carcinoma invasivo da mama, triplo negativo. O estadiamento sistémico foi negativo (cT4bN0M0).

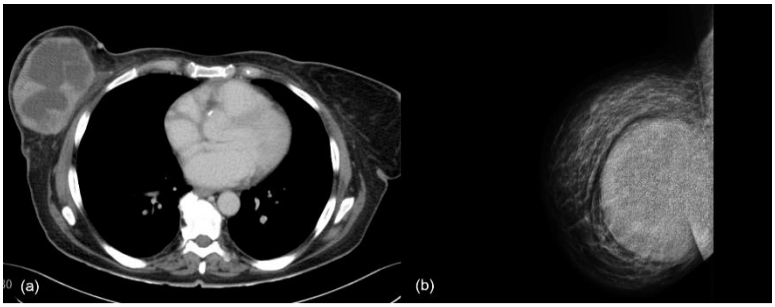

Fig. 2 (a) TC de tórax e (b) mamografia à apresentação

Foi proposta para quimioterapia neo-adjuvante, tendo realizado 12 ciclos de paclitaxel semanal, com fraca resposta clínica.

Por episódio de hemorragia tumoral não controlada, foi encaminhada ao Serviço de Radioterapia.

Realizou radioterapia 3D conformacional urgente com intuito hemostático sobre a mama direita na dose total de 13Gy / 2 fracções em dias alternados. Verificou-se hemóstase eficaz e dado ausência de resposta com o tratamento sistémico previamente instituído, optou-se por prosseguir radioterapia em esquema convencional com intuito neo-adjuvante. Realizou 50Gy / 25 fracções, 2 semanas após conclusão do *flash* hemostático. Durante o tratamento verificou-se redução progressiva do volume da lesão tendo ocorrido aos 40Gy emissão abundante de tecido necrosado dos quadrantes inferiores da mama associado a destacamento tumoral e diminuição substancial do volume da mama (figura 3).

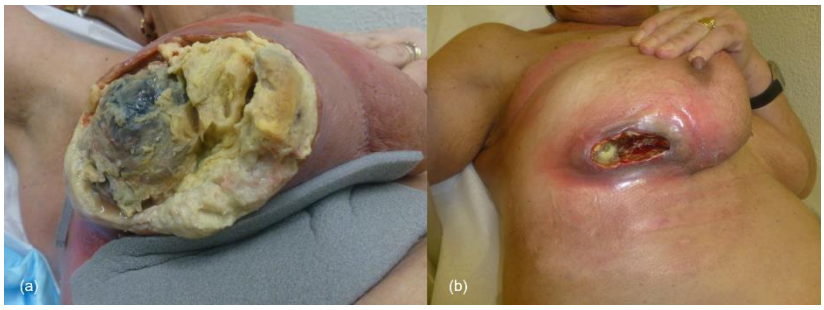

Fig. 3 (a) Destacamento tumoral com (b) redução do volume da mama

Foi posteriormente submetida a mastectomia radical modificada, documentando o exame anatomopatológico resposta patológica completa ypT0N0 (0/20).

Iniciou quimioterapia adjuvante com doxorrubicina e ciclofosmamida cerca de 2 meses após a cirurgia, do qual apenas cumpriu um ciclo, por aparecimento a C1D2 de dermatite (*rash* macular violáceo exuberante) na parede torácica, correspondente à área de irradiação e compatível com *radiation recall (figuras 4 e 5)*. Após suspensão da quimioterapia ocorreu resolução completa das alterações cutâneas em 2 semanas, sem necessidade de terapêutica dirigida.

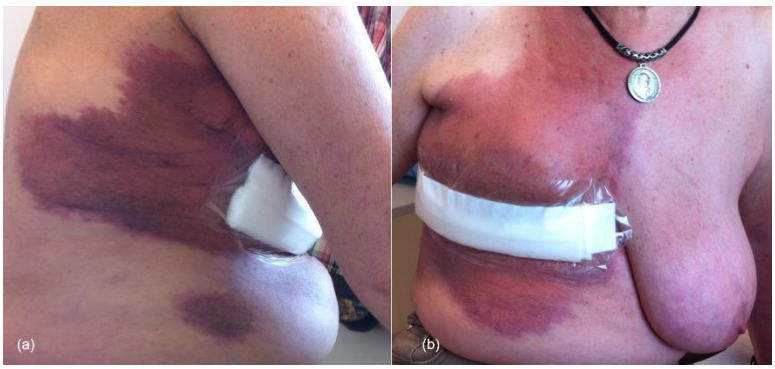

Fig. 4 Dermatite na parede torácica compatível com radiation recall dermatitis

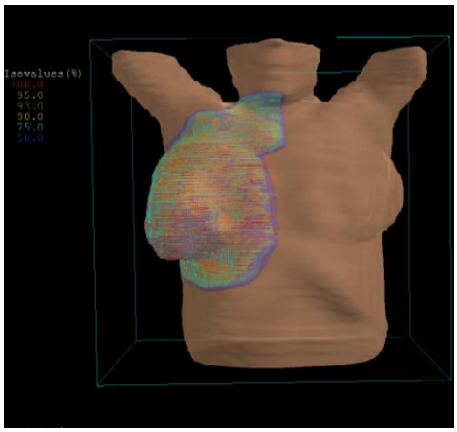

Fig. 5 Reconstrução tridimensional do planeamento dosimétrico do tratamento de radioterapia

Completou 5 ciclos de quimioterapia adjuvante com CMF (ciclofosfamida, metotrexato e 5-fluorouracilo), sem novos eventos cutâneos.

Atualmente encontra-se em *follow-up* de 24 meses, sem evidência de recidiva local e à distância.

Discussão

O tratamento do cancro da mama requer uma abordagem multidisciplinar que engloba a cirurgia, radioterapia e tratamento sistémico.

Na abordagem do cancro da mama localmente avançado ou inoperável, a evidência disponível e as *guidelines* da *National Comprehensive Cancer Network* (NCCN) advogam a abordagem inicial com quimioterapia neo-adjuvante, seguida de cirurgia após resposta clínica e imagiológica e radioterapia adjuvante[4]. No caso infrequente de resposta insuficiente ou nula, poderá estar indicada a realização de radioterapia neo-adjuvante, o que neste caso condicionou uma resposta patológica completa e concomitantemente colocou em evidência a existência de *radiation recall dermatitis*.

Conclusão

Este evento não necessita geralmente de tratamento dirigido e reverte espontaneamente após a suspensão do fármaco desencadeante, no entanto pode em casos mais graves produzir ulceração e necrose cutânea, com risco potencial para a vida[1]. Deve portanto fazer sempre parte do diagnóstico diferencial de dermatites em doentes sob quimioterapia submetidos previamente a tratamentos de radioterapia.

Referências

1. Burris III HA, Hurtig J. *Radiation Recall with Anticancer Agents*. The Oncologist 2010; 15:1227-1237
2. Hird C, Wilson J, Symons S. *Radiation recall dermatitis : case report and review of the literature*. Current Oncology 2008; *15*: 53–62.
3. Zouhair A, Azria D, Magne N, et al.*Radiation recall : A well recognized but neglected phenomenon*. Cancer Treatment Reviews 2010; 31: 555–570.
4. National Comprehensive Cancer Network. Breast Cancer (Version 1.2018). http://www.nccn.org/professionals/physician_gls/pdf/breast.pdf.

Treating inside the womb: a rare case of a fetal arrhythmia

Tratar dentro do útero: um caso raro de arritmia fetal

Catarina Reis de Carvalho, Margarida Cal, Catarina Castro, Nuno Clode

* Departamento de Obstetrícia, Ginecologia e Medicina da Reprodução, Centro Hospitalar Lisboa Norte

Abstract

Fetal supraventricular tachycardia (SVT) is the most common form of fetal tachycardia. It is a well-recognized cause of cardiac failure and non-immune fetal hydrops in utero. The preferred method for the diagnosis is echocardiography, with simultaneous pulsed Doppler recording from the superior vena cava and ascending aorta. There is no clear consensus regarding the best drug-treatment regimens for fetal SVT. However, transplacental treatment of fetal SVT is available with several antiarrhythmic agents. We present a case of fetal SVT detected at 30 weeks of pregnancy, managed with digoxin therapy with success.

Keywords: fetal arrhythmia, heart, pregnancy

Resumo

A taquicardia supraventricular fetal (TSV) é a forma mais comum de taquicardia fetal. É uma causa bem reconhecida de insuficiência cardíaca no útero e de hidrópsia fetal não imune. A ecocardiografia é o método ideal para o diagnóstico da arritmia, através do registro simultâneo de Doppler pulsado da veia cava superior e da aorta ascendente. Não há um consenso claro sobre os melhores esquemas terapêuticos para a TSV fetal. No entanto, o tratamento transplacentário da TSV fetal está descrito através de vários agentes antiarrítmicos. Apresentamos um caso de TSV fetal detetada às 30 semanas de gestação que foi controlada com sucesso através da terapêutica com digoxina.

Palavras-chave: arritmia fetal, coração, gravidez

Introduction

The fetal heart first develops during the third week of gestation, and its conduction system matures by 16 weeks [1]. Fetal tachycardia is defined as a heart rate faster than 160 beats per minute (BPM) [2]. Common causes of fetal tachycardia include infection, hypoxemia, maternal hyperthyroidism, and tachyarrhythmia. Fetal tachyarrhythmia was first described by Hyman using phonocardiography, and the suspicion of this diagnosis increases when the fetal heart rate is over 220 BPM [3].

The most frequent tachyarrhythmias (70-75%) are supraventricular in origin, with sinus and

ventricular tachycardias being much rarer [4]. Sustained tachyarrhythmias, which are often defined as the presence of tachycardia for more than 50% of fetal monitoring time, may cause fetal heart failure, non-immune hydrops, and/or Ballantyne's syndrome, all of which are complications that can lead to fetal death [1]. They are also a significant cause of premature deliveries and perinatal morbidity [1]. Therefore, identification and appropriate management of these cases are essential in an attempt to prevent these adverse outcomes. Hereby, we present a case of a fetus of 30 weeks who developed a sustained tachyarrhythmia of supraventricular origin with an indication of transplacental treatment.

Case Report

A 28-year-old woman, gravida 1, was referred to our hospital from a private clinic because of fetal SVT (>200 bpm) noted in a routine obstetric ultrasound performed at 30 weeks of gestation. There was no history of infectious diseases, thyrotoxicosis, or consumption of any drugs or caffeine. Her medical and obstetric history was unremarkable. The pregnancy course was uneventful.

Ultrasound examination revealed a single live active male fetus appropriate for gestational age. There was no pleural or pericardial effusion with a normal amniotic fluid index. The fetal echocardiogram confirmed the tachycardia with fetal heart rate (HR) ranging from 215 to 239 bpm with 1:1 AV relationship and long VA interval (VA/AV ratio = 3.0; VA interval time = 223 msec). The fetal echocardiogram also showed normal cardiac anatomy and no signs of hydrops. The cardiotocograph, which is a technical mean of recording fetal heartbeats and uterine contractions during pregnancy, showed a persistent fetal tachycardia with a heart rate of 210 bpm (Figure 1).

These features made the diagnosis of fetal supraventricular tachycardia. The condition was fully discussed between the obstetrician and the pediatric cardiology team, and the couple, who agreed to start transplacental antiarrhythmic therapy.

The mother was admitted in our maternal-medicine ward to fetal surveillance and underwent further investigations to ensure the safety of digoxin therapy. Her necessary laboratory investigations, including urea, electrolytes, and creatine, were within the normal range. 12-Lead ECG was reasonable, along with her transthoracic echocardiography. She was started on digoxin 0.25 mg twice a day. During the whole course of treatment, maternal serum digoxin, urea, electrolytes and ECG were monitored. We defined the target maternal serum digoxin as 1,5-2,0 ng/dL.

Two days after the beginning of the antiarrhythmic therapy, short paroxysms of tachycardia at 215/min were noted, alternating with sinus rhythm 130/min (Figure 2). At this time, the maternal serum digoxin was below the target value (0,7 ng/dL). We decided to increase the dose of digoxin to 0.25 mg three times a day.

The conversion to sinus rhythm was achieved 5 days after the start of the digoxin (figure 3). The pregnant woman was discharged at this time, on the same digitalis dosage, with close outpatient follow-ups. The mother did not experience symptoms of digitalis toxicity. The fetal HR remained stable (120-138 bpm) until the end of the pregnancy.

The fetal echocardiograms performed at 33th and 38th weeks were normal. At 39 weeks of pregnancy, the pregnant woman went on spontaneous labor.

There were no specific obstetrical indications for the labor and delivery, that went unremarkably. The male baby was born healthy, weighing 3275 g, with Apgar scores of 9 and 10 at 1 and 5 min, respectively. During his stay, there was no recurrence of SVT. The neonatal electrocardiogram and echocardiogram were normal. His weight increased normally and he was discharged from the hospital after 3 days with digoxin (5 mcg 12/12h) therapy regimen and indication for follow-ups in the pediatric cardiology outpatient department.

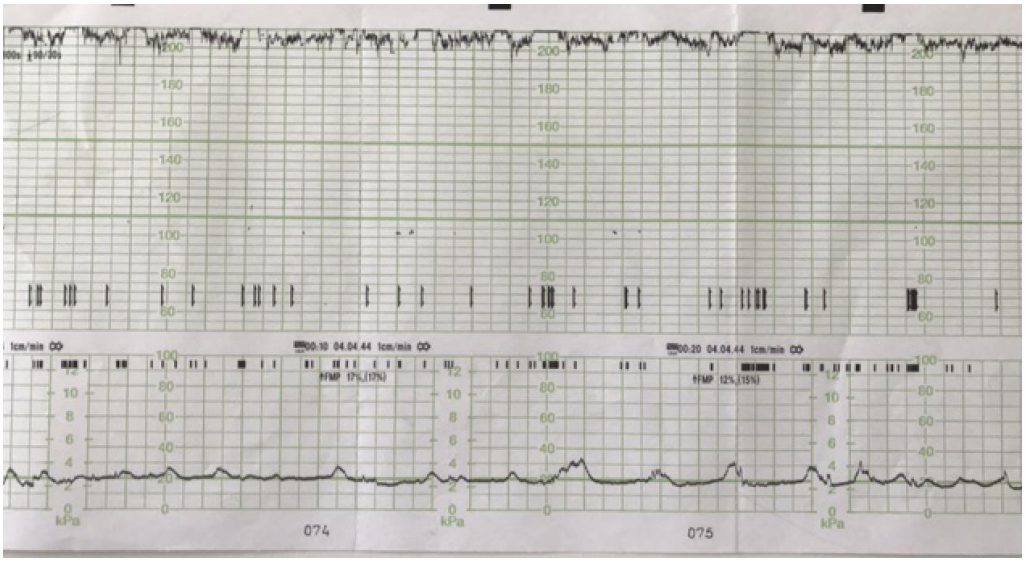

Figura 2

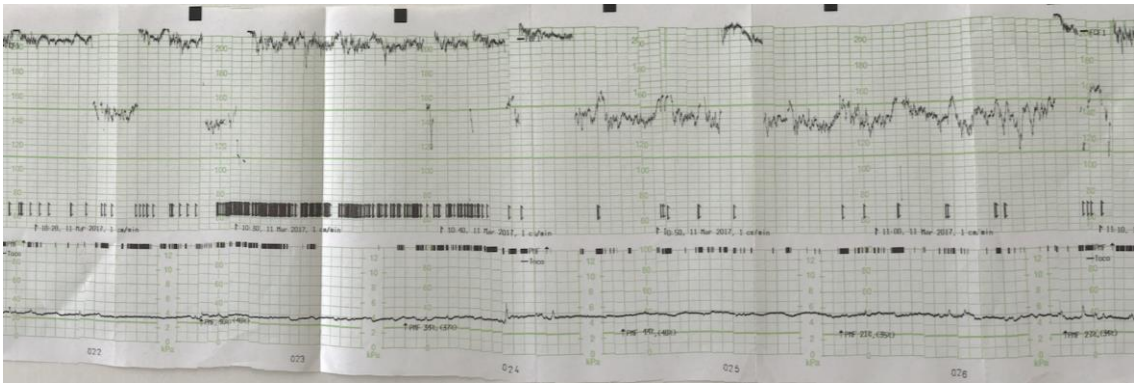

Figura 3

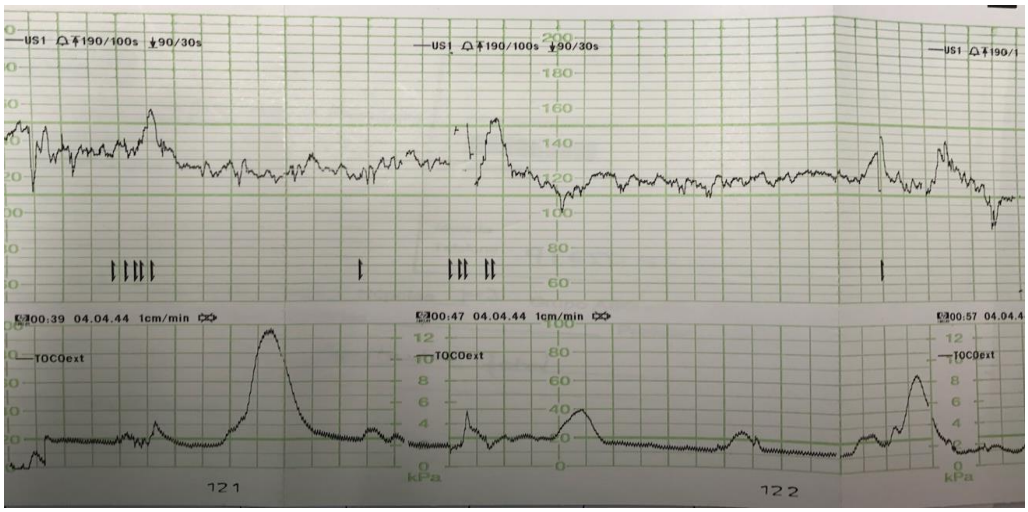

Figura 4

Discussion

We present a case of a fetus with supraventricular tachycardia (SVT) developed in the third-trimester. Rhythm disturbances are diagnosed in less than 2% of pregnancies during routine scanning and account for 10–20% of the referrals to fetal cardiologists [5]. In general, fetal arrhythmias are detected during the second or third-trimester routine obstetric ultrasound. The vast majority of affected pregnancies have innocent isolated premature atrial contractions. Less than 10% of referrals for fetal rhythm abnormalities have a sustained tachyarrhythmia or bradyarrhythmia considered to be of clinical significance [6].

The most common SVT type is related to a fast conducting accessory pathway (reentrant SVT) and, in general, is initiated by an ectopic cardiac beat [7]. In reentrant SVT, the HR usually ranges between 220 and 300 bpm, with a 1:1 AV relationship [7]. Due to the immaturity of the fetal myocardium, accessory pathways occur more frequently *in utero* [6].

The clinical presentation of fetal SVT has a broad spectrum. It can be intermittent with no hemodynamic effects to persistent type with high output cardiac failure leading to hydrops fetalis [8]. The risk of developing hydrops fetalis is related to the age of the fetus (the more premature are more susceptible) and the duration of the SVT [9].

The standard gold diagnosis of tachycardia is made by M-mode and Doppler echocardiography to determine the atrial and ventricular rates and the sequence of AV conduction [10].

Unlike most forms of structural congenital heart disease (CHD), fetal dysrhythmias might require prenatal treatment – either transplacental or given directly to the fetus [10]. A multidisciplinary approach is mandatory between pediatric cardiologist, adult cardiologist, neonatologist, and obstetrician. The goal of treatment of tachyarrhythmia is to restore the normal fetal heart rate and prevent or reverse fetal heart failure and/or non-immune hydrops. Gestational age plays a role in determining the optimal treatment strategy. Treatment is recommended for those fetuses at the highest risk of developing heart failure, specifically those fetuses with sustained tachycardia (persistent tachycardia for greater than 12 hours in 24 hours) and an earlier gestational age at

presentation (because risk of prematurity outweighs the risks of therapy) [11]. If the fetus is mature (>36 weeks), the delivery may be the best option.

Because the fetus of our case report was only 30 weeks, we decided to start a transplacental treatment. There is no consensus on the choice of antiarrhythmic therapy. Treatment decisions should be based on the balance maternal risk and fetal benefits. The method for monitoring mothers during fetal antiarrhythmic treatment is also controversial. Baseline and daily maternal 12-lead ECGs to assess the effect and identify the toxicity of the medication are recommended. The monitoring of serum drug levels can also be helpful.

The experience with transplacental drug therapy started from late 1970s. Digoxin is often used as a first-line agent as it has been well studied and has an acceptable safety profile [12]. However, it is essential to note that digoxin can worsen certain tachyarrhythmias [13]. Digoxin slows conduction through the AV node, and thus can slow ventricular response with atrial fibrillation. However, in a patient with a tachyarrhythmia with WPW, digoxin may cause a paradoxical worsening of tachyarrhythmia by causing preferential conduction over the faster accessory pathway over the slowed AV nodal pathway[13]. After the start of digoxin, conversion to sinus rhythm occurs in 32-71% of nonhydropic fetuses and in 10-41% of hydropic fetuses with SVT [11].

Other first or second-line therapies include flecainide and sotalol. Amiodarone is generally used in refractory cases as it has more risk of toxicity, including hypothyroidism and fetal goiter [14]. Medication failure can occur due to maternal toxicity, increased volume of distribution in pregnancy, and decreased transplacental transfer of drugs in the setting of hydrops. In these cases, directed fetal therapy via an intramuscular or vascular route can be considered depending on the gestational age.

The cardiotocography is an excellent method of follow-up of the fetus after a sinus rhythm is obtained. As shown by our report, delivery can be normal if the fetus is maintained on sinus rhythm, which is the most likely outcome with fetal SVT.

Conclusion

In summary, fetal sustained SVT is rare. Correct identification of the type of tachyarrhythmia is important as it may alter plans for intervention. The goal of treatment in utero is the conversion to sinus rhythm or reduction of the ventricular rate to tolerable levels thereby preventing fetal hydrops. Our case report shows that management of fetal SVT can be challenging but that with successful multidisciplinary treatment, good fetal and neonatal outcomes can be obtained.

Referências

1. Hornberger LK, Sahn DJ. Rhythm abnormalities of the fetus. Heart. 2007.
2. Macones GA, Hankins GDV, Spong CY, Hauth J, Moore T. The 2008 National Institute of Child Health and Human Development Workshop Report on Electronic Fetal Monitoring. Obstet Gynecol [Internet]. 2008;112(3):661–6. Available from: http://content.wkhealth.com/linkback/openurl?sid=WKPTLP:landingpage&an=00006250-200809000-00023

3. Husain A, Hubail Z, Banna R Al. Fetal supraventricular tachycardia , treating the baby by targeting the mother. 2013;1–3.
4. Franklin WJ, Rokey R, Foley MR, Belfort MA. Cardiac disease and pregnancy. In: Critical Care Obstetrics. 2018.
5. Strasburger JF, Wakai RT. Fetal cardiac arrhythmia detection and in utero therapy. Nat Publ Gr [Internet]. 2010;7(5):277–90. Available from: http://dx.doi.org/10.1038/nrcardio.2010.32
6. Schleich JM, Du Haut Cilly FB, Laurent MC, Almange C. Early prenatal management of a fetal ventricular tachycardia treated in utero by amiodarone with long term follow-up. Prenat Diagn. 2000;
7. Christine E, Moisés D, Carvalho SR, Duarte LDB. Arritmias Cardíacas Fetais : Diagnóstico e Tratamento Não-Invasivo Fetal Cardiac Arrhythmias : Diagnostic and Non Invasive Treatment Incidência e Etiologia. 2006;34.
8. Shand AW, Dickinson JE, D'Orsogna L. Refractory fetal supraventricular tachycardia and obstetric cholestasis. Fetal Diagn Ther. 2008;
9. Porat S, Anteby EY, Hamani Y, Yagel S. Fetal supraventricular tachycardia diagnosed and treated at 13 weeks of gestation: A case report. Ultrasound Obstet Gynecol. 2003;
10. Api O. Fetal dysrhythmias. 2008;22(1):31–48.
11. Cuneo BF, Strasburger JF. Management strategy for fetal tachycardia. Obstet Gynecol. 2000;
12. Bircher CW, Farrakh S, Gada R. Supraventricular tachycardia presenting in labour : A case report achieving vaginal birth and review of the literature. 2016;9(2):96–7.
13. Belhassen B, Pauzner D, Blieden L, Sherez J, Zinger A, David M, et al. Intrauterine and postnatal atrial fibrillation in the Wolff-Parkinson-White syndrome. Circulation. 1982;
14. Donofrio MT, Moon-Grady AJ, Hornberger LK, Copel JA, Sklansky MS, Abuhamad A, et al. Diagnosis and Treatment of Fetal Cardiac Disease. Circulation. 2014;

Atypical presentation and clinical course in a rare primary malignant giant cell tumor of bone

Apresentação e evolução clínica atípicas num raro tumor primário maligno de células gigantes do osso

David Gonçalves Ferreira*; Joaquim Soares do Brito*; André Spranger*; Paulo Almeida*; Daniela Macedo**; Dolores Presa***; José Portela*

*Orthopedics Department, University Hospital of Santa Maria, Lisbon, Portugal; **Medical Oncology Department, University Hospital of Santa Maria, Lisbon, Portugal; ***Pathology Department, University Hospital of Santa Maria, Lisbon, Portugal

Resumo

O tumor primário maligno de células gigantes do osso (TPMCGO) é um diagnóstico raro. Apesar desta entidade ter melhor prognóstico, quando comparado com a sua entidade secundária (tumor secundário maligno de células gigantes do osso), apresentamos um caso de uma apresentação clínica extremamente atípica de um TPMCGO da tíbia proximal esquerda, com uma progressão rápida, aparecimento de fratura patológica, ulceração e morte do doente. Este caso clínico representa um exemplo do comportamento biológico mais agressivo, que pode estar na consequência de um TPMCGO, comumente associado a um melhor prognóstico entre os tumores malignos de células gigantes. Além disso, reforça a necessidade para um limiar baixo de suspeita de transformação maligna, quando um tumor de células gigantes apresentas manifestações incomuns.

Palavra-chave: tumor, osso, células gigantes

Abstract

Primary malignant giant cell tumor of bone (PMGCT) is an extremely rare event. Despite this entity seems to present better prognosis when compared with the secondary counterpart (secondary malignant giant cell tumor of bone), we present an extremely atypical clinical presentation for PMGCT of the proximal left tibia, with extremely fast progression, pathological fracture, fungation and patient death. This clinical case represents an example of the most extreme aggressive biological behaviour which could arise with a PMGCT, usually related with better prognosis among malignant giant cell tumors. Additionally, highlights the need for a low threshold to suspect malignant transformation when giant cell tumors have non-usual manifestations.

Keywords: tumor, bone, giant cell

Introduction

Giant cell tumor of bone (GCT) is a well-known but rare benign bone lesion[1,2,3]. Despite its benign biological nature, GCT can demonstrate important local aggressiveness, be misdiagnosed as bone sarcoma and even originate lung metastasis in 2-3% of cases [4]. Additionally, in exceptional occasions, a typical benign giant cell tumor of bone can suffer a malignant transformation becoming a malignant giant cell tumor of bone (MGCT) [4,5].

Most often, a malignant giant cell tumor of bone arises secondarily (SMGCT) after previous treatment such as surgery or radiotherapy [6,7]. Nontheless, primary malignization (PMGCT) can also occur. In plain radiographic studies PMGCT has the typical appearance of giant cell tumor and, in most cases, it is impossible to distinguish between them. On the other hand, SMGCT usually has a more malignant appearance on plain films [6]. Likewise, the clinical presentation of a PMGCT or SMGCT could be comparable to those of classic giant cell tumors and the pathology presents with areas of high grade sarcoma next to areas of benign giant cell tumor, which difficults proper diagnosis[6,7].

In the largest study describing epidemiology of malignancy in GCT in the United States, the average 5-year survival rate was 84.2% and the mean survival time was 11 years and 11 months [8]. Other studies also supported this finding and a high survival rate is expected in patients with malignant giant cell tumors of bone [9]. Nonetheless those reported findings, a good outcome is not always the case. Herein, the authors present an atypical clinical case of an unusual aggressive primary malignant giant cell tumor of the proximal left tibia, which due to extremely fast progression caused a pathological fracture, fungation and the patient death.

Case presentation

A 55-year-old woman was referred to our practice after 3 months of relenting left knee pain without history of trauma. She described the pain as sharp, intense and mechanically related. The pain was aggravated by activity, relieved with rest and managed with acetaminophen and nonsteroidal anti-inflammatory drugs with fair relief. The medical and family histories were unremarkable. She had no other associated symptoms.

Physical examination of the left knee showed no deformities, no leg length discrepancies, no joint fluid or knee instability. The patient presented no muscle atrophy, nonetheless, a mild edema around the knee could be noted. Tenderness was present over the proximal tibia metaphysis but no vascular or neurologic abnormalities were disclosed. Anteroposterior and lateral radiographs showed a lytic metaphyseal lesion involving the proximal aspect of the left tibia (Fig. 1). The CT-scan confirmed a wide osteolytic lesion, with images of mineralization inside, cortical rupture and some soft tissue involvement. The bone scan showed an isolated active lesion suggesting a benign bone tumor in the proximal metaphysis of the left tibia.

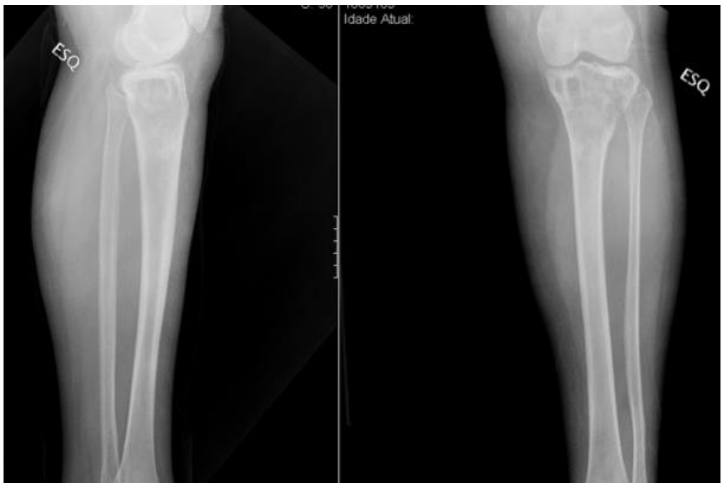

Figure 1. AP and lateral radiographs showing lytic metaphyseal lesion involving the proximal tibia

An image guided percutaneous biopsy failed to identify any abnormality in the histology sample. Nonetheless, the patient returned to the outpatient clinic due to increasing pain in the knee needing walking aids for deambulation. In this scenario we decided to perform an open biopsy to ensure enough sample to allow a proper histological diagnosis. The second biopsy reported the presence of fusiform cells and osteoclast-like giant multinuclear cells, without pleomorphism or mitosis, which allowed the final diagnosis of giant cell tumor of bone. A surgical procedure for resection and arthroplasty reconstruction was proposed, which the patient refused.

After two months the patient returned to the outpatient clinic due to excruciating pain despite the opioid therapy (implemented by the pain management team). The physical examination showed an important knee swelling, with a volumous palpable mass in the supra-patelar recess and a fixed knee deformity in flexion. The new radiographs revealed a pathological fracture in the proximal left tibia (Fig. 2). In this setting and due to the dissociation between histology and biological behaviour of the tumor we decided for a new open biopsy and MRI to acess the soft tissue involvement.

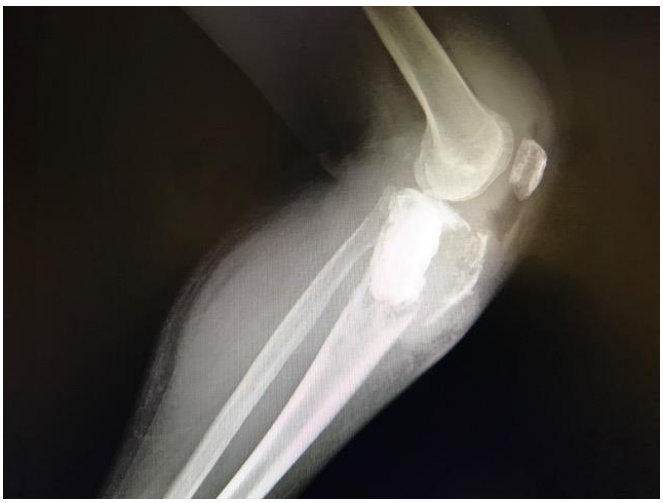

Figure 2. Lateral radiograph revealing a pathological fracture in the proximal tibia

The new biopsy reported the presence of some areas with typical histological findings for a giant cell tumor, but with other areas where pleomorphic hipercelular mononuclear cells with a high

number of atypical mitosis. The final diagnosis for those findings was a malignant giant cell tumor of bone (Fig. 3). The MRI showed a large soft tissue mass in the left proximal tibia invading the adjacent muscles, the knee articulation and all the suprapatelar recess (Fig. 4). During the follow-up after the former biopsy we also documented the breakdown of the surgical incision with progressive fungation of a soft tissue tumoral mass complicated with bacterial superinfection, which needed antibiotic therapy (Fig. 5). A new CT-scan and bone scan additionally showed several lung, vertebral, right iliac bone and right femur metastasis. After discussion in the multidisciplinary meeting the decision was for above knee amputation, chemotherapy and additional radiotherapy for symptomatic bone lesions.

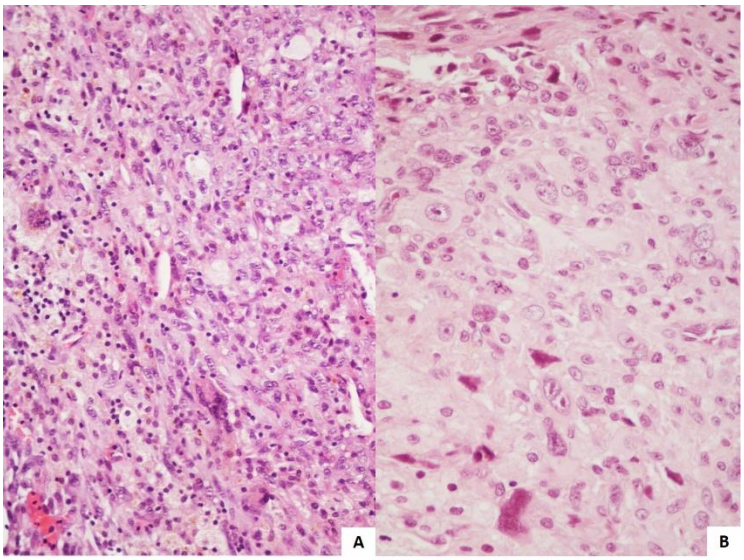

Figure 3. Typical histological findings for a giant cell tumor and other areas with pleomorphic hipercelular mononuclear cells with a high number of atypical mitosis

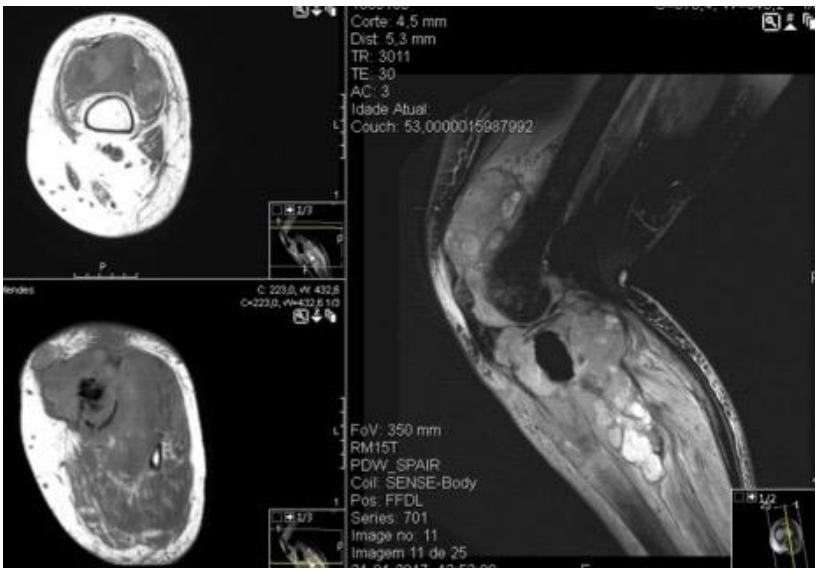

Figure 4. MRI showing a large soft tissue mass in the left proximal tibia invading the adjacent muscles, the knee articulation and the suprapatelar recess

Figure 5. Progressive fungation of a soft tissue tumoral mass bellow the left knee

During the immediate post-operative period after the above knee amputation (with histology showing free margins but tumoral vascular invasion), the patient sustained an acute intense dorsal pain. No neurological complains were disclosed. The spine CT-scan showed a D8 pathological fracture. In this setting the patient returned to the operating theatre for termoablation of D8 metastasis, vertebroplasty and a D6-D10 posterior pedicular percutaneous fixation, followed by local radiotherapy (30 Gy). The transpedicular biopsy perfomed previously to the spinal surgery confirmed a metastasis from the malignant giant cell tumor of the left tibia. In addition to surgery, the patient underwent chemotherapy with doxorrubicin and cisplatin, nonetheless, the disease kept progressing as showed by the follow-up CT and bone scan.

Shortly after chemotherapy the patient presented with right iliac pain and irradiation to the ipsilateral lower limb. In the follow-up CT and bone scan was already visible a new metastatic mass occupying the right iliac bone and sacrum with probable sacral roots involvement. The patient was again proposed for palliative radiotherapy nonetheless, she sustained a right femur pathological fracture for which she had to return to the theatre for a long cephalomedular nailing. Radiotherapy was also offered for the right iliac mass and all right femur (total 20 Gy), and a second line chemotherapy cycle was proposed. Unfortunately, and only 16 months after the initial evaluation in the outpatient clinic for a left knee pain, the patient suffered a fast clinical deterioration and eventually died.

Discussion

Giant cell tumor of bone is a rare benign tumor accounting for only 5% of all bone neoplasms, originally described by Jaffe *et al* [8,10]. Primary malignancy in giant cell tumors of bone is an extremely rare subtype of these tumors, which can arise in 1-2% of all reported cases [5]. In fact, Beebe-Dimmer *et al* estimated in their recent populational study an annual incidence of 1.6 per 10,000,000 persons per year in the United States, which confirmed the rarity of these neoplasms [8].

The literature concerning malignancies in giant cell tumors is often confusing due to the lack of clear definitions. In 1970, Dahlin *et al* considered MGCT a malignant tumor with histologic evidence

of benign counterpart features or in material previously removed from the same area [7]. If the tumor presented malignant stromal cells throughout, Dahlin considered it should be classified has other malignant tumor accordingly with proper classification, despite containing multinucleated benign cells, as does a giant cell tumor[7,11]. Furthermore, the presence of metastasis in the onset of GCT should not be held as an automatic hallmark for the malignization of the tumor, but instead as an unusual feature for a borderline benign tumor as GCT [12-15]. To clarify the study of MGCT it is crucial to use clear definitions and separate primary from secondary malignant giant cell tumor of bone: PMGCT is a lesion in which there are areas of synchronous high grade sarcoma next to areas of benign typical GCT; SMGCT is a metachronous high grade sarcomatous growth which arises on a previous benign GCT that has been treated by either surgery or radiotherapy[5,6]. In this setting and as reported by Bertoni *et al*, PMGCT is much rarer than SMGCT[6].

Like classic GCT, the malignant version of the disease preferentially invade the ends of long bones including distal femur, proximal tibia and distal tibia [4,5,6,7,16,17,18]. Most often, the clinical presentation for a PMGCT is nonspecific, with pain and swelling as common symptoms [6]. Additionally, radiological findings are very similar to those of GCT, which makes extremely difficult to distinguish malignancies from the benign ones even when the former has a metastasis or soft tissue invasion. We should not forget that typical GCT has the capacity to promote aggressive bone destruction, local invasion and metastasize [1,19,20].

While GCT is typically associated with a favorable prognosis, the long-term prognosis for malignant transformation seems to be poor. Bertoni *et al* reported a high mortality rate, especially with SMGCT[6]. Anract *et al* also reported poor prognosis for MGCTB with a 5-year survival of only 50%, despite the combination of surgery and chemotherapy [18]. Nontheless, more recent reports from Beebe-Dimmer *et al* showed a mean survival time of 11 years and 11 months, with a 5-year relative survival of 84.2%[8]. Domovitov *et al* also found a 16% mortality rate for patients with MGCT, both suggesting a low grade malignancy [9]. In this setting, and due to unclear and sometimes contradictory reports in the literature, Gong *et al* considered that the prognosis of MGCTB is still indefinite, mainly because of its rareness and short follow-up [5].

Considering all MGCT, PMGCT seems to have a better prognosis compared with SMGCT as pointed by Gong *et al* [5]. Nascimento *et al* also found a better outcome for PMGCT, but Anract *et al* observed equally poor outcomes between PMGCTB and SMGCTB [17,18]. In the report by Bertoni *et al*, and despite the poor outcomes for all MGCT (most patients died due to lung metastatic disease), SMGCT had again a much worst prognosis, highlighting what it seems to be a less aggressive nature for PMGCT[6].

There are some identified risk factors associated with poor outcomes regarding MGCT. Beebe-Dimmer *et al* found in their study a relation between older age and a more advance stage disease with an increased risk for death[8]. More specifically, for each 5-year increase in age at diagnosis, the risk of death increased by 41% and for patients with distant metastases detected at the time of diagnosis, the risk of death was 5.2 times higher compared to those diagnosed with tumor confined to the bone[8].

We herein reported a 55-year-old women in which the PMGCT diagnosis was difficult and required three biopsies (1 imaging percutaneous biopsy without malignancy and two surgical

biopsies which finally allowed the proper diagnosis). When the diagnosis for a PMGCT was made the patient already sustained a pathological fracture and presented a fungated lesion due to an extremely fast tumor growing. Furthermore, the disease was already metastasized to the lungs and bone as identified in the CT and bone scan. Despite the surgical treatment, chemotherapy and radiotherapy the disease kept progressing and the patient died less than one year after the diagnosis.

Conclusion

This clinical case describes a very rare and aggressive presentation, even for a malignant giant cell tumor. It represents an example of the most extreme aggressive biological behavior which could arise with a PMGCT, usually related with better prognosis. Indeed, this report has the merit of highlighting the need for a low threshold of suspicion for malignancy in case of GCT with non-usual manifestations and a dissociation between histology and clinical behavior.

We can also conclude that PMGCT is a confusing disease, since its clinical presentation and initial radiologic findings were nonspecific and similar to any GCTB, which evolved towards an overflowing and shocking outcome. Even histological examination, as the gold standard for diagnosis, had serious difficulties to deliver the final result. Unfortunately, the delay on diagnosing such unusual aggressive PMGCT prevented a better and more efficient management of the disease.

References

1. Mendenhall WM, Zlotecki RA, Scarborough MT, Gibbs CP, Mendenhall NP. Giant cell tumor of bone. American journal of clinical oncology. 2006; 29.1:96-99
2. Werner M. Giant cell tumour of bone: morphological, biological and histogenetical aspects. Int Orthop. 2006 Dec; 30(6):484-9
3. Dahlin DC. Caldwell Lecture. Giant cell tumor of bone: highlights of 407 cases. AJR Am J Roentgenol. 1985 May;144(5):955-60
4. Alberghini M, Kliskey K, Krenacs T, *et al*. Morphological and immunophenotypic features of primary and metastatic giant cell tumour of bone. Virchows Archiv. 2010; 456.1: 97-103
5. Gong L, Liu W, Sun X, *et al*. Histological and clinical characteristics of malignant giant cell tumor of bone. Virchows Archiv. 2012; 460.3: 327-334
6. Bertoni, F, Bacchini P, Staals, EL. Malignancy in giant cell tumor of bone. Cancer. 2003; 97(10); 2520-2529
7. Dahlin DC, Cupps RE, Johnson EW Jr. Giant-cell tumor: a study of 195 cases. Cancer. 1970; 25:1061-70
8. Beebe-Dimmer J, Cetin K, Fryzek JP, Schuetze S, Schwartz K. The epidemiology of malignant giant cell tumors of bone: an analysis of data from the Surveillance, Epidemiology and End Results Program (1975–2004). Rare tumors. 2009; 1.2: 159-163.
9. Dewan V, Darbyshire A, Sumathi V, Jeys L, Grimer R. Primary malignant giant-cell tumor of bone has high survival rate. Annals of surgical oncology. 2010; 17.3: 694-701
10. Jaffe HL, Lichtenstein L, Portis RB. Giant cell tumor of bone. Its pathologic appearance, grading, supposed variants and treatment. Arch Pathol. 1940; 30:993–1031
11. Troup J, Dahlin D, Coventry M. The significance of giant cells in osteogenic sarcoma: do they indicate a relationship between osteogenic sarcoma and giant cell tumor of bone? Proc. Stafl Meet. Mayo Clin. 1960; 35:179-186

12. Pan P, Dahlin D, Lipscomb P, Bernatz P. “Benign” giant cell tumor of the radius with pulmonary metastasis. Mayo Clin. Proc. 1964; 39344-349
13. Bertoni F, Present D, Enneking WS. Giant cell tumour of bone with pulmonary metastases. J Bone Joint Surg [Am]. 1985; 67: 890±900
14. Bertoni F, Present D, Sudanese A, Bacchini P, Campanacci M. Giant cell tumour of bone with pulmonary metastases: six case reports and a review of the literature. Clin Orthop. 1988; 237: 275±285
15. Maloney WJ, Vaughan LM, Jones HH, Ross J, Nagel DA. Benign metastasing giant cell tumour of bone: re- port of three cases and review of the literature. Clin Orthop. 1989; 243: 208±215
16. Hutter RVP, Worcester JN, Francis KC, Foote FW, Stewart FW. Benign and malignant giant cell tumors of bone. A clinicopathological analysis of the natural history of the disease. Cancer. 1962; 15:653–690
17. Nascimento NG, Huvos AG, Marcove RC. Primary malignant giant cell tumor of bone: a study of 8 cases and review of the literature. Cancer. 1979; 44:1393–1402
18. Anract P, Pinieux G, Cottias P, Pouillart P, Forest M, Tomeno B. Malignant giant-cell tumours of bone. Clinicopathological types and prognosis: a review of 29 cases. Int Orthop. 1998; 22:19–26
19. Enneking WF. A system of staging musculoskeletal neoplasms. Clin Orthop Relat Res. 1986; 204:9-24
20. Campanacci M, Baldini N, Boriani S, Sudanese A. Giant-cell tumor of bone. J Bone Joint Surg Am. 1987; 69:106-14

Colangite Esclerosante Associada a IgG4

IgG4-Related Sclerosing Cholangitis

Cátia Caniço Felício, Sara Fernandes[1], António Santos Ruivo[1], Manuel Ferreira Gomes[2], João Coutinho[1]

[1]Departamento de Cirurgia Geral, Hospital de Santa Maria, Centro Hospitalar Universitário Lisboa Norte; [2]Serviço de Medicina I – Sector B, Hospital de Santa Maria, Centro Hospitalar Universitário Lisboa Norte

Resumo

A colangite esclerosante associada a IgG4+ é rara e integra a doença sistémica associada a IgG4+. O diagnóstico diferencial desta entidade com a neoplasia maligna biliar é difícil na ausência de outras doenças associadas a IgG4. Apresenta-se um caso de colangite esclerosante associada a IgG4+ que mimetiza um colangiocarcinoma. Descreve-se o quadro de um homem, 71anos, diabético, hipertenso, com icterícia obstrutiva cuja investigação imagiológica foi sugestiva de colangiocarcinoma multicêntrico. Realizou-se duodeno-pancreatectomia cefálica e hepatectomia esquerda alargada ao segmento I. O exame histológico revelou colangite esclerosante associada a IgG4+. Após resolução de foco séptico no pós-operatório foi iniciada corticoterapia. O diagnóstico atempado é possível com base nos níveis séricos de IgG4, presença de doença associada a IgG4 noutros órgãos, colangiograma e achados histológicos característicos. Com este caso alerta-se para a existência desta entidade multissistémica que deve ser considerada no diagnóstico diferencial e tem como terapêutica de primeira linha a corticoterapia.

Palavras-chave: Imunoglobulinas G4; Colangite esclerosante associada a IgG4; Colangiocarcinoma

Abstract

IgG4-related sclerosing cholangitis is rare and is a manifestation of IgG4 systemic disease on the biliary tract. Distinguishing this disease from malignant tumors of the biliary tract is challenging in the absence of another IgG4-associated organ manifestation. We present a case of IgG4-related sclerosing cholangitis that mimics a cholangiocarcinoma. A 71-year-old diabetic man with hypertension was admitted by obstructive jaundice. Imagiologic examination showed compatible findings with multicentric cholangiocarcinoma. A cephalic pancreaticoduodenectomy and left hepatectomy extended to segment I was performed. The histological examination revealed IgG4-related sclerosing cholangitis. Steroid therapy was started after resolution of septic complication in postoperative period. An early and correct diagnosis is possible based on serum IgG4 levels, organ manifestation pattern of IgG4-related disease, cholangiogram and characteristic histological findings. With this case we draw attention to this systemic disease that must be part of the differential diagnosis and wich first-line therapy is based in corticosteroids.

Keywords: G4 imunoglobulins, Sclerosing Cholangitis, colangiocarcinoma

Introdução

A colangite esclerosante associada a IgG4+ (IgG4-SC) é rara e integra a doença sistémica associada a IgG4+ cujo conceito foi apresentado em 2003 [1, 2, 3].

Clinicamente, a IgG4-SC manifesta-se frequentemente com icterícia obstrutiva resultante da exuberante estenose concêntrica da parede das vias biliares, perda ponderal e, ocasionalmente, desconforto abdominal [4].

Trata-se de uma patologia que atinge predominantemente homens (rácio homem: mulher 4:1) com idade média de 62±10,7 anos, cujo diagnóstico se baseia em 4 critérios que incluem a presença de achados imagiológicos característicos, elevação da concentração sérica de IgG4, coexistência de doenças relacionadas com as imunoglobulinas G4 (IgG4-RD) e achados histopatológicos específicos [4, 5, 6, 7, 8].

A destacar contudo que os achados imagiológicos característicos da IgG4-SC (4 tipos diferentes definidos por colangiografia de acordo com a localização da estenose nas vias biliares) não são específicos desta doença benigna e implicam a realização de diagnóstico diferencial (Figura 1), nem sempre exequível, com entidades como o colangiocarcinoma. Relativamente a este último, a abordagem terapêutica é a ressecção cirúrgica major quando ressecável (sendo realizada em até 50% dos casos sob diagnóstico apenas imagiológico) e não se coaduna com o ensaio de corticoterapia advogado como terapêutica de primeira linha para a IgG4-SC [2, 3, 4, 5, 9].

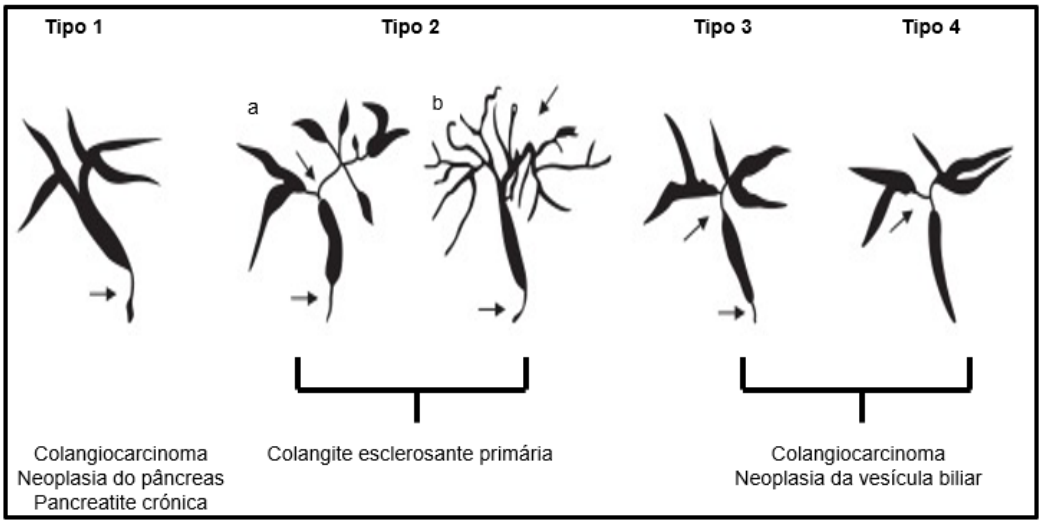

Figura 1 – Classificação colangiográfica da colangite esclerosante associada a IgG4 (Tipo 1; Tipo 2 – subtipo 2a e 2b; Tipo 3 e Tipo 4) e diagnóstico diferencial a ter em consideração; setas: zona de estenose na via biliar. Adaptado de [4] – vide referência bibliográfica.

Face ao anteriormente referido, é compreensível que segundo alguns estudos até um terço dos doentes com IgG4-SC tenha o diagnóstico apenas após abordagem cirúrgica, a qual foi realizada sob o diagnóstico pré-operatório de colangiocarcinoma [10, 11, 12].

De referir que nos doentes com IgG4-SC submetidos a ressecção cirúrgica, a abordagem cirúrgica não tem impacto positivo no curso da doença (a qual permanece ativa nos ductos biliares remanescentes, bem como noutros órgãos) implicando, adicionalmente, potenciais complicações resultantes do procedimento cirúrgico e o atraso no início da terapêutica imunossupressora adequada [13].

Os autores apresentam um caso clínico de colangite esclerosante associada a IgG4+ que mimetiza um colangiocarcinoma multicêntrico.

Caso Clínico

Descreve-se o caso clínico de um homem, 71 anos de idade, ancestralidade europeia, autónomo nas atividades de vida diária que recorreu ao Serviço de Urgência Central (SUC) do Hospital de Santa Maria (HSM) por um quadro de icterícia, colúria e acolia com cerca de 1 semana de evolução. Adicionalmente, mencionava uma perda ponderal involuntária de 8 Kg em 6 meses que associou à diabetes. Negava febre, náuseas, vómitos ou dor abdominal, bem como qualquer outra sintomatologia constitucional. Como antecedentes pessoais a destacar hipertensão arterial sistémica, diabetes tipo 2 não insulino-dependente diagnosticada há 10 anos e estado pós-resseção vesical transuretral de carcinoma urotelial papilar não invasivo de baixo grau há 5 anos. O doente, mecânico de profissão, referia hábitos alcoólicos esporádicos e negava hábitos toxicofílicos ou tabágicos. Encontrava-se medicado com vildagliptina e cloridrato de metformina, enalapril, hidroclorotiazida e esomeprazol. Sem alergias medicamentosas conhecidas.

À observação no SUC, o doente encontrava-se vígil e orientado no tempo e espaço, a destacar no exame objetivo apenas a pele e escleróticas ictéricas. Laboratorialmente, salientava-se anemia normocítica normocrómica (Hb 11,8g/dL) e elevação dos parâmetros de citocolestase (bilirrubina total (BT) 9,9 mg/dL, gama glutamiltansferase (GGT) 1330 U/L, aspartato aminotransferase (AST) 122 U/L e alanina aminotransferase (ALT) 116 U/L. Electrocardiograma e radiografia do tórax sem alterações.

A ecografia abdominal (Figura 2) demonstrou dilatação das vias biliares intra-hepáticas (VBIH) e do segmento proximal da via biliar principal (VBP), visualizando-se uma área de espessamento parietal no segmento distal da VBP; evidenciava, ainda, atrofia do parênquima pancreático com ligeira ectasia do Wirsung.

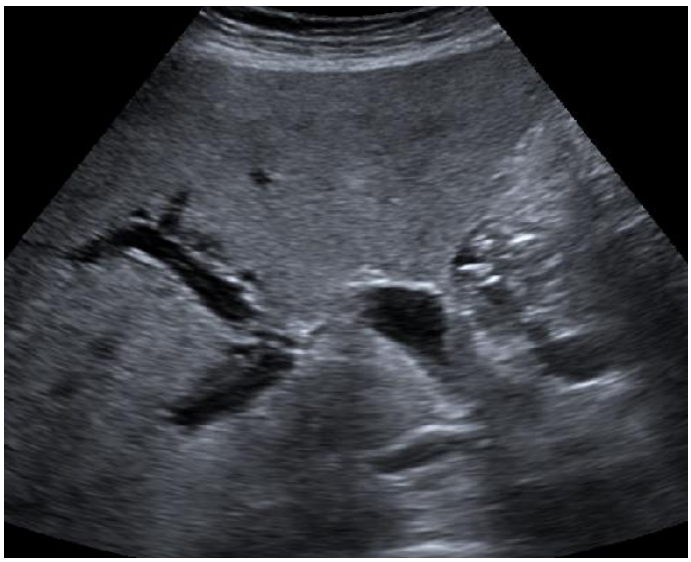

Figura 2: Imagem ecográfica da dilatação da VBIH e segmento proximal da VBP visualizando-se área de espessamento parietal do segmento distal da VBP.

Face aos achados previamente referidos o doente foi admitido no serviço de Gastrenterologia para esclarecimento etiológico do quadro clínico, onde permaneceu dois dias sendo posteriormente transferido para o Serviço de Cirurgia ao cuidado da equipa de cirurgia hepato-bílio-pancreática face ao diagnóstico provável de colangiocarcinoma.

Durante o internamento doente com agravamento do quadro de icterícia obstrutiva com elevação dos parâmetros de colestase (BT 29,41mg/dL, bilirrubina directa (BD) 22.68 mg/dL, GGT 280 U/L, fosfatase alcalina (FA) 513 U/L) e sem alteração do doseamento dos marcadores tumorais (CEA 1,6ng/mL e CA 19,9 10.0 U/mL).

Realizou tomografia computorizada (TC) toraco-abdomino-pélvica da qual se destacavam numerosas formações ganglionares nas cadeias mediastínicas; micro nódulo calcificado no segmento apical do lobo inferior direito (cerca de 3 mm); VBP com franco espessamento distal e obliteração do lúmen associado a moderada dilatação das VBIH e da VBP a montante da lesão (calibre de 19mm) salientando-se o aparecimento de "novo" das alterações descritas comparativamente ao exame de referência; pâncreas com parênquima atrófico e ligeira ectasia do canal de Wirsung (calibre de 4-5mm). Não foi possível a realização de colangiopancreatografia retrógrada endoscópica (CPRE) com citologia da lesão, tendo o doente realizado colangiopancreatografia por ressonância magnética (CPRM) para melhor caracterização dos achados prévios, a qual mostrou lobo hepático esquerdo atrófico com alteração de sinal comparativamente ao contralateral; dilatação bilateral das VBIH com ausência de sinal nos ramos intra-hepáticos esquerdos, com dilatação distal mais marcada; VBP com dilatação no terço proximal; ausência de sinal no terço médio, e espessamento circunferencial da parede; canal pancreático com contornos irregulares (sugestivo de processo inflamatório crónico); estes achados seriam compatíveis com lesão multicêntrica primitiva das vias biliares (Figura 3).

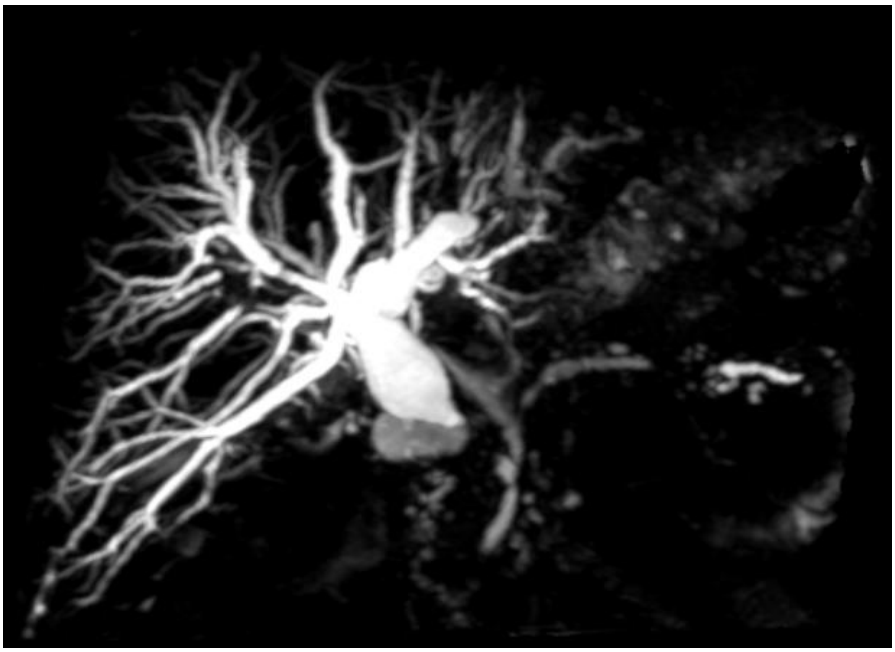

Figura 3 – CPRM com dilatação das VBIH, ausência de sinal nos ramos intra-hepáticos esquerdos; dilatação do segmento proximal da VBP por espessamento parietal concêntrico do seu terço médio.

Perante a evolução clínico-laboratorial e hipótese diagnóstica de colangiocarcinoma multicêntrico, o doente foi proposto para abordagem cirúrgica a qual incluiu a realização de duodeno-pancreatectomia cefálica e hepatectomia esquerda alargada ao segmento I, com exame extemporâneo (Wirsung e margem pâncreas, VBP) negativo, cirurgia com recurso a ecografia e colangioscopia (Figuras 4 e 5). O pós-operatório imediato foi realizado no Serviço de Medicina Intensiva tendo o doente uma evolução favorável com transferência para o Serviço de Cirurgia no terceiro dia de pós-operatório. Como intercorrências no pós-operatório a destacar derrame pleural, para o qual realizou toracocentese evacuadora, e fístula pancreática com coleção associada a qual foi drenada por via percutânea. O doente teve alta hospitalar, ao 16º dia de pós-operatório, clínica e laboratorialmente melhorado, sendo referenciado à Consulta Externa de Cirurgia Geral.

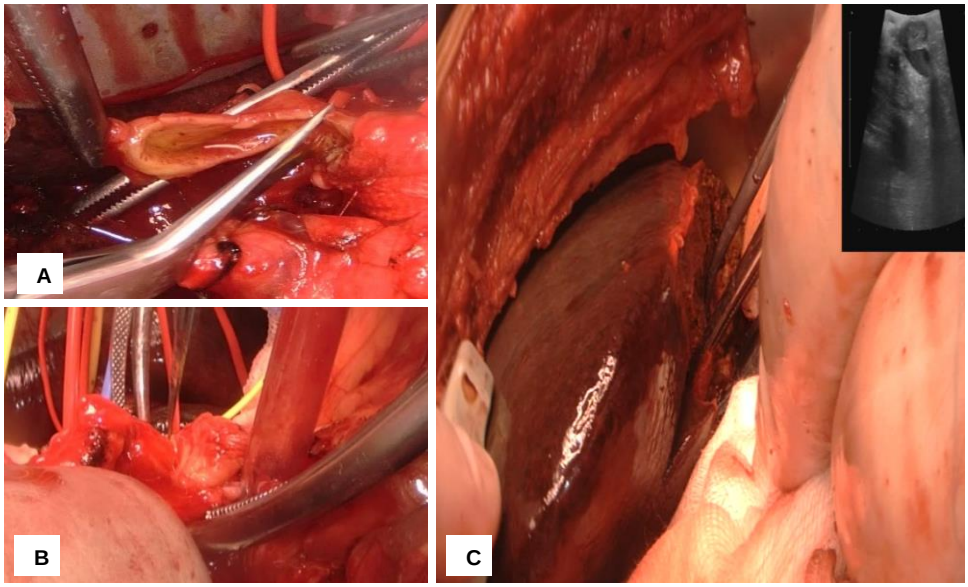

Figura 4 – Imagem intra-operatória: A) secção da VBP; B) secção do pâncreas; C) avaliação ecográfica do lobo hepático direito pós-hepatectomia esquerda alargada ao segmento I.

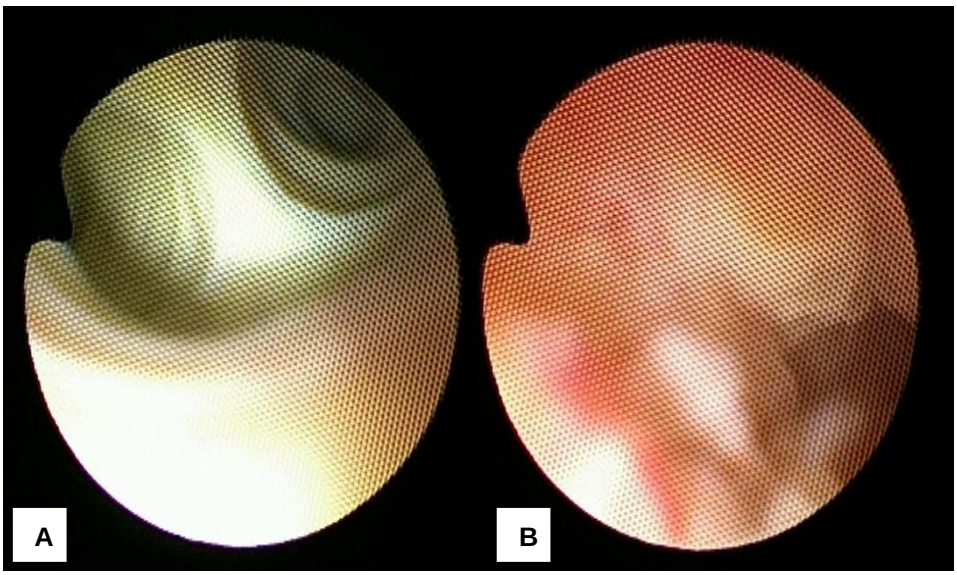

Figura 5 – Colangioscopia intra-operatória: A) ductos biliares sem alterações; B) ducto biliar patológico, com espessamento parietal.

O relatório anatomopatológico da peça operatória revelou lesão fibro-inflamatória com aspetos morfológicos e imunohistoquimícos compatíveis com colangite esclerosante associada a IgG4.

Perante o resultado anatomopatológico foi discutido o caso clínico em reunião multidisciplinar (cirurgia e medicina interna - doenças autoimunes) tendo-se optado pela realização de estudo laboratorial e imagiológico complementar para decisão de abordagem terapêutica a adotar.

Laboratorialmente a destacar na electroforese de proteínas uma hipergamaglobulinémia (35.3 g/dL), com perfil oligoclonal; imunoquímica revelou elevação marcada das IgG (2160 mg/dL), nomeadamente da subclasse das IgG4 (595 mg/dL); verificou-se ainda consumo da fracção C3 do complemento (80 mg/dL) e beta 2 microglobulina aumentada (4,52 mg/dL).

Imagiologicamente, o doente realizou tomografia computadorizada (TC) do pescoço, tórax, abdómen e pélvis a qual mostrou múltiplas pequenas adenopatias nas cadeias mediastínicas, pré-vasculares e no mediastino médio (paratraqueais inferiores direitas e esquerdas e janela aorto-pulmonar); pequena adenopatia na cadeia mamária interna esquerda; espessamento irregular difuso da pleura à esquerda, especialmente na metade superior, com densificação nodular na pleura mediastínica anterior e superior heterogénea com área hipodensa no seu interior; moderado derrame pleural à esquerda, predominantemente inferior e sub-pulmonar com áreas de loculação; pequeno derrame pleural à direita, aparentemente livre com envolvimento ligeiro da asa superior da grande cisura do mesmo lado. Presença de coleção septada de contornos anfractuosos entre o fígado e a anastomose pancreatoentérica; irregularidade do contorno hepático esquerdo, bem como heterogeneidade do parênquima com pequenas áreas hipodensas no segmento VIa.

Após discussão com a imagiologia, a imagem nodular pulmonar foi interpretada como sendo de etiologia inflamatória/infeciosa, sem indicação para biopsia. A coleção intra-abdominal foi drenada percutaneamente e o estudo microbiológico do exsudado drenado revelou ser negativo.

O doente passou a fazer seguimento na consulta de doenças autoimunes, com indicação para esquema de corticoterapia, o qual foi inicialmente protelado por intercorrências infeciosas (supuração da ferida operatória e posteriormente erisipela do membro inferior esquerdo). Após resolução do quadro infecioso, o doente iniciou esquema de corticoterapia com prednisolona 40 mg/dia, cuja dosagem foi reduzida para 20mg/dia após sete semanas dada a melhoria clínica e laboratorial, incluindo das provas hepáticas. Durante o seguimento o doente realizou reavaliação laboratorial e imagiológica com TC do tórax, abdómen e pélvis nas quais se verificou evolução favorável e teve indicação para realização de CPRM de controlo, a qual não realizou por episódio de insuficiência cardíaca aguda, não especificada, que implicou internamento noutra instituição de saúde e culminou no seu óbito cerca de um ano após a admissão inicial no SUC do Hospital de Santa Maria.

Discussão

No caso clínico apresentado o estabelecimento do diagnóstico pré-operatório, de colangiocarcinoma multicêntrico, foi suportado pelos resultados da avaliação clínica, laboratorial e imagiológica disponível (TC abdomino-pélvica e CPRM). Numa avaliação retrospetiva estes achados enquadram-se num quadro de IgG4-SC de tipo 3/4 cujo diagnóstico diferencial inclui o

colangiocarcinoma. Admite-se que a realização pré-operatória de CPRE com citologia pudesse ter impacto no processo diagnóstico e secundariamente na abordagem terapêutica adotada [5].

Apesar de não se encontrarem características clínicas e imagiológicas que permitam de forma precisa distinguir lesões benignas das lesões malignas nas vias biliares, a presença de achados sugestivos doença sistémica como pancreatite crónica e as numerosas adenopatias mediastínicas presentes na TC de estadiamento do doente apresentado, enquadram-se à data no espectro da doença sistémica associada a IgG4, assim como o espessamento concêntrico da parede das vias biliares em vez do espessamento assimétrico mais característico do colangiocarcinoma mas cuja avaliação nem sempre é fácil de definir [4, 13].

Com este caso clínico aumentamos a suspeição para esta entidade patológica aquando da investigação etiológica de doentes com icterícia obstrutiva não litiásica e de comportamento relativamente indolente. Nomeadamente, com a pesquisa de sinais extrabiliares de doença sistémica associada a IgG4, como o envolvimento do pâncreas, rins e retroperitoneu, a realização de CPRE com citologia e o doseamento sérico de IgG4 (tendo contudo, em consideração as suas limitações) [13, 14, 15, 16].

Têm sido realizados esforços no desenvolvimento de testes diagnósticos mais discriminativos para a doença associada a IgG4 como a razão entre RNA IgG4/IgG no sangue periférico. À data, na prática clínica exames endoscópicos como a ultrassonografia endoscópica alta e a colangioscopia, em situações específicas, têm aumentado a sensibilidade e especificidade no diagnóstico, permitindo iniciar a terapêutica adequada que implica imunossupressão [14, 17, 18, 19, 20].

A abordagem da doença associada a IgG4, desde o seu diagnóstico até instituição da terapêutica e seguimento implica, dadas as suas características, uma abordagem multidisciplinar.

Conclusão

O diagnóstico atempado é possível com base nos níveis séricos de IgG4, presença de doença associada à IgG4 noutros órgãos, colangiograma e achados histológicos característicos, contudo implica uma elevada suspeição. Serve este caso para alertar para a existência desta entidade que tem um envolvimento multissistémico e resolve na maioria das vezes com corticosteroides, pelo que a sua inclusão no diagnóstico diferencial e confirmação do diagnóstico pode evitar a realização de cirurgias major desnecessárias que implicam uma morbimortalidade não desprezível.

Referências

1. Kamisawa T, Funata N, Hayashi Y, et al. A new clinicopathological entity of IgG4-related autoimmune disease. J Gastroenterol. 2003; 38:982-984.
2. Kamisawa T, Zen Y, Pillai S, Stone J. IgG4-related disease. Lancet. 2015; 385: 1460-71.
3. Hubers L, Wenniger L, Doorenspleet M, et al. IgG4-associated cholangitis: a comprehensive review. Clin Rev Allergy Immunol. 2015; 48: 198-206.
4. Nakazawa T, Ando T, Hayashi K, Naitoh I, Ohara H, Joh T. Diagnostic procedures for IgG4-related sclerosing cholangitis. J Hepatobiliary Pancreat Sci. 2011; 18: 127–136.

5. Engelbrecht M, Katz S, van Gulik, T, Laméris, J, van Delden O. Imaging of Perihilar Cholangiocarcinoma. American Journal of Roentgenology. 2015; 204(4): 782–791.
6. Ohara H, Okazaki K, Tsubouchi H, et al. Clinical diagnostic criteria of IgG4-related sclerosing cholangitis 2012. Journal of Hepato-Biliary-Pancreatic Sciences. 2012; 19(5): 536–542.
7. Zen Y, Fujii T, Sato Y, Masuda S, Nakanuma Y. Pathological classification of hepatic inflammatory pseudotumor with respect to IgG4-related disease. Modern Pathology. 2007; 20(8): 884–894.
8. Deshpande V, Zen Y, Chan J, et al. Consensus statement on the pathology of IgG4-related disease. Modern Pathology. 2012; 25(9): 1181–1192.
9. Kloek J, van Delden O, Erdogan D, et al. Differentiation of malignant and benign proximal bile duct strictures: The diagnostic dilemma. World J Gastroenterol. 2008; 14: 5032–8.
10. Fujita T, Kojima M, Gotohda N, at al. Incidence, clinical presentation and pathological features of benign sclerosing cholangitis of unknown origin masquerading as biliary carcinoma. Journal of Hepato-Biliary-Pancreatic Sciences. 2009; 17(2): 139–146.
11. Erdogan D, Kloek J, ten Kate F, et al. Immunoglobulin G4-related sclerosing cholangitis in patients resected for presumed malignant bile duct strictures. British Journal of Surgery. 2008; 95(6): 727–734.
12. Ghazale A, Chari S, Zhang L, et al. Immunoglobulin G4–Associated Cholangitis: Clinical Profile and Response to Therapy. Gastroenterology. 2008; 134(3): 706–715.
13. Roos E, Hubers L, Coelen R, et al. IgG4-Associated Cholangitis in Patients Resected for Presumed Perihilar Cholangiocarcinoma: a 30-Year Tertiary Care Experience. The American Journal of Gastroenterology. 2018: 113(5): 765–772.
14. Navaneethan U, Njei B, Venkatesh P, Lourdusamy V, Sanaka, M. Endoscopic ultrasound in the diagnosis of cholangiocarcinoma as the etiology of biliary strictures: a systematic review and meta-analysis. Gastroenterology Report. 2014; 3(3): 209–215.
15. Navaneethan U, Njei B, Lourdusamy V, Konjeti R, Vargo J, Parsi M. Comparative effectiveness of biliary brush cytology and intraductal biopsy for detection of malignant biliary strictures: a systematic review and meta-analysis. Gastrointestinal Endoscopy. 2015; 81(1): 168–176.
16. Oseini A, Chaiteerakij R, Shire A, et al. Utility of serum immunoglobulin G4 in distinguishing immunoglobulin G4-associated cholangitis from cholangiocarcinoma. Hepatology. 2011; 54(3): 940–948.
17. Doorenspleet M, Hubers L, Culver E, et al. Immunoglobulin G4+B-cell receptor clones distinguish immunoglobulin G 4-related disease from primary sclerosing cholangitis and biliary/pancreatic malignancies. Hepatology. 2016; 64(2): 501–507.
18. Tabibian J, Lindor K. Distinguishing immunoglobulin G4-related disease from its pancreatobiliary mimics: Are we there now? Hepatology. 2016; 64(2): 340–343.
19. Tsuyuguchi T, Fukuda Y, Saisho H. Peroral cholangioscopy for the diagnosis and treatment of biliary diseases. Journal of Hepato-Biliary-Pancreatic Surgery. 2006; 13(2): 94–99.
20. Beuers U, Wenniger L, Doorenspleet M, et al. IgG4-Associated Cholangitis. Digestive Diseases. 2014; 32(5): 605–608.

Surgery for a large pelvic chondrosarcoma: pearls and pitfalls of a complex clinical case

Tratamento cirúrgico de um volumoso condrossarcoma pélvico: aspetos preponderantes e complicações de um caso clínico complexo

Francisco Serra Alves, André Chambel; Rita S. Henriques; André Spranger; Paulo Almeida; Joaquim Soares do Brito; José Portela

University Hospital of Santa Maria, Lisbon, Portugal. Orthopedics and Trauma Department. Hip, Pelvis and Musculoskeletal Oncology Unit
Departamento de Ortopedia e Trama, Hospital de Santa Maria, Centro Hospitalar Universitário Lisboa Norte

Resumo

Os autores apresentam o caso de uma doente de 29 anos que recorreu à consulta com uma massa de crescimento indolente, com cerca de três anos de evolução, na região glútea. A biópsia e estudo imagiológico foram compatíveis com condrosarcoma pélvico grau I (secundário periférico). Assim, a doente foi submetida a uma ressecção P1 alargada da pélvis, sem registo de complicações major. No pós-operatório a doente teve uma necrose cutânea complicada com uma infeção superficial da ferida cirúrgica. A ferida foi desbridada e depois de várias semanas de vacuoterapia e antibioticoterapia dirigida foi feito um retalho cutâneo para cobertura da área necrótica. Não foram registadas mais complicações.

Este caso pretende evidenciar a complexidade cirúrgica dos sarcomas pélvicos, em particular quando são de grandes dimensões.

Palavras chave: condrosarcoma pélvico; cirúrgica; preservação do membro; complicações

Abstract

The authors present a case of a 29-year-old female patient who presented in our department with a growing tumor mass on her right gluteal area for about three years. The biopsy and imaging studies were consistent with a grade 1 (secundary peripheral) pelvic chodrosarcoma. In this scenario, a wide pelvic P1 ressection was performed without major complications. Post-operatively the patient had a skin necrosis associated with a superficial wound infection. The wound was debrided and after several weeks on negative wound pressure treatment and antibiotics, a skin flap was performed to cover the necrotic area. No further complications were disclosed.

This case highlights the challenges and complexity of pelvic sarcomas surgery, especially when dealing with large tumors.

Key-words: Pelvic chondrosarcoma; surgery; limb sparing; complications

Introduction

Chondrosarcoma is a cartilage matrix producing malignant tumor that accounts for approximately 20% of bone sarcomas [1]. The pelvis is one of the most frequent anatomic locations for chondrosarcoma, and the ilium is more often involved, followed by the pubis and ischium [2]. While primary conventional central chondrosarcoma predominates in the pelvis, secondary peripheral chondrosarcoma can also occur [2]. Secondary peripheral chondrosarcomas arise in the cartilaginous cap of a pre-existing osteochondroma, but less than 1% of patients with sporadic osteochondromas and only 1-3% of patients with multiple osteochondromas will eventually suffer a sarcomatous transformation [3,4]. Most chondrosarcomas are not sensitive to chemotherapy or irradiation, so surgery is the most important treatment option [5].

Pelvic sarcoma's surgery remains a challenge for orthopedic oncology surgeons due to the proximity of vital structures and complex local anatomy. With modern preoperative imaging and multimodality treatment, limb sparing surgery has become a feasible option in these patients, nonetheless, a high complication rate, poor functional results, and an important tumor recurrence rate have been reported in several occasions [6,7,8]. Herein, the authors present the clinical case of a young female patient with a unusually large pelvic secondary peripheral chondrosarcoma, in which a wide resection was performed. Despite keeping the surgical complexity to a minimum, post-operative complications still happened, which illustrates the permanent challenge associated with pelvic sarcomas surgical treatment.

Case Report

A 29-year-old female patient was referred to our practice with complains of a growing mass in the right gluteal area with three years of evolution. No other associated symptoms were disclosed, such as pain or neurological complaints. Physical examination showed an increased volume in the right gluteal region, but despite this deformity no limitations were present in the hip range of motion neither during gait. Palpation showed a huge hard mass occupying all the right gluteal anatomy, starting above the iliac crest and going all away below the great trochanter. Palpation also did not reveled any tenderness. The initial x-ray showed a huge cloud-like calcified mass in relation with the right iliac bone. The CT-scan (Figure 1) confirmed the large volume of the mass, which seems to start in previous osteochondroma located in the iliac wing. These aspects raised the suspicion of a secondary peripheral pelvic P1 chondrosarcoma and a pelvic MRI, a staging thoraco-abdomino-pelvic CT-scan, a bone scan and an image guided biopsy were requested. The MRI findings were consistent with the chondrosarcoma diagnosis (Fig. 2). The bone scan and staging CT-scan exclude metastatic disease. The biopsy was consistent with a grade one chondrosarcoma.

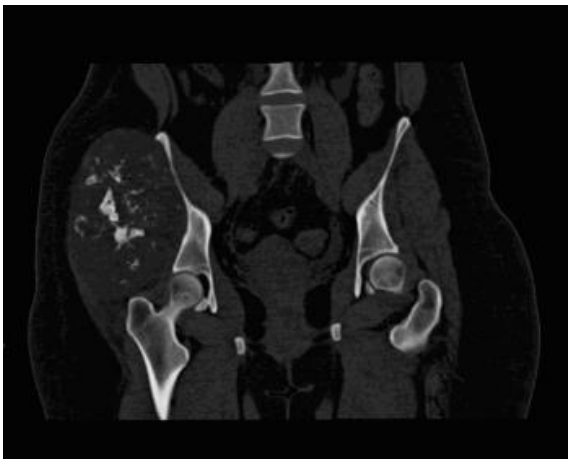

Figure 1 – Pelvic CT-Scan

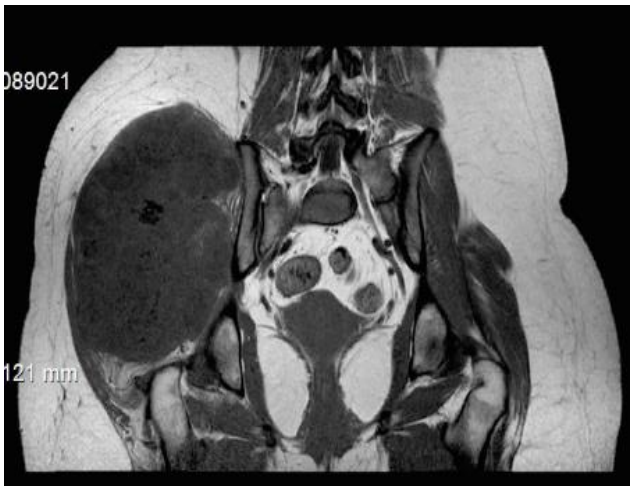

Figure 2 – Pelvic

After discussion in the multidisciplinary sarcoma meeting, a decision to perform a wide excision was made. At this point the main questions were related to the possibility to save the acetabulum and also the gluteus maximus. Given the large volume of the tumor and its location, all the other abdutor muscles could not be preserved. In order to keep the resection and the need for reconstruction to a minimum, we made the decision to try to save the acetabulum and go for a P1 pelvic resection. After the initial and extensive dissection using a utilitarian incision, we performed an anterior-posterior supra-acetabular osteotomy, which was associated with a posterior pre sacro-iliac vertical osteotomy, in order to also keep the sacro-iliac articulation. This strategy avoided the need to reconstruct the acetabulum and the sacro-iliac articulation, ensuring the pelvic ring stability (Fig. 3). The remaining muscles were re-inserted in the remaining pelvic bone with anchors and heavy sutures, and a primary skin closing was performed. Standard drains were also in place and compressive dressings were used.

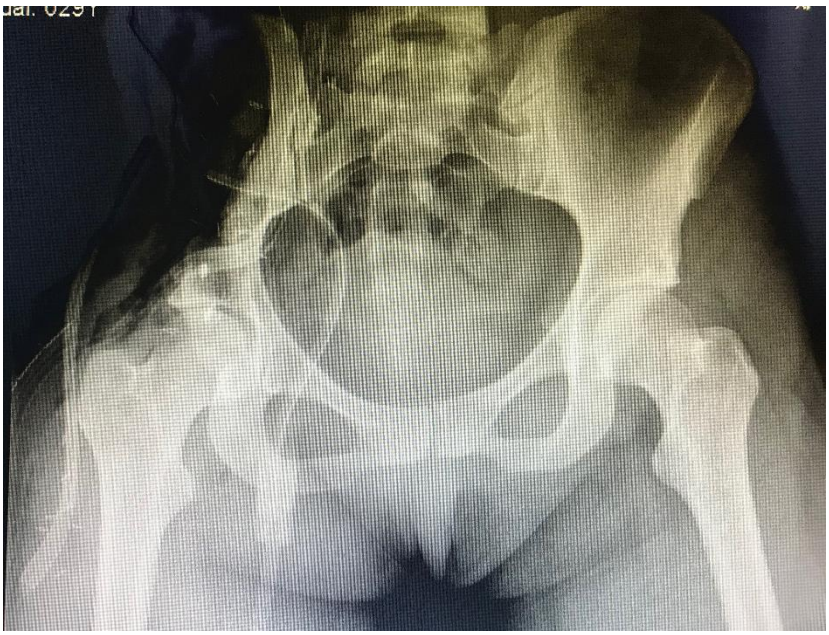

Figure 3 – Post operatively X-Ray

One week after the procedure the patient developed an extensive skin necrosis near the suture (Figure 4). Eventually, the necrotic skin allowed a bacterial super-infection with *Escherichia coli* in the surgical wound, which needed to be debrided, and a negative wound pressure treatment with antibiotics (cefuroxime) were initiated. During follow-up, other bacteria was found (*Pseudomonas aeruginosa*), and the antibiotic was updated to cotrimoxazol, for a total six weeks time. Eventually, the infection was solved and the skin closure achieved. No further complications were disclosed.

The functional outcome was affected by the gluteal mass resection, nonetheless, the patient had the ability to stand alone, walk with one walking aid and was capable of going up and down the stairs just after hospital discharge.

The surgical specimen (Figure 5) was reported as with clear margins and the biopsy diagnosis was confirmed.

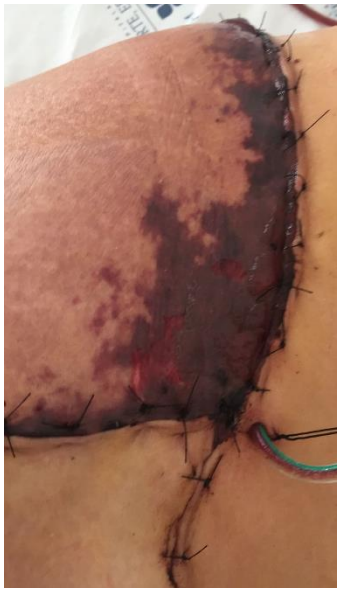

Figure 4 – Skin Necrosis

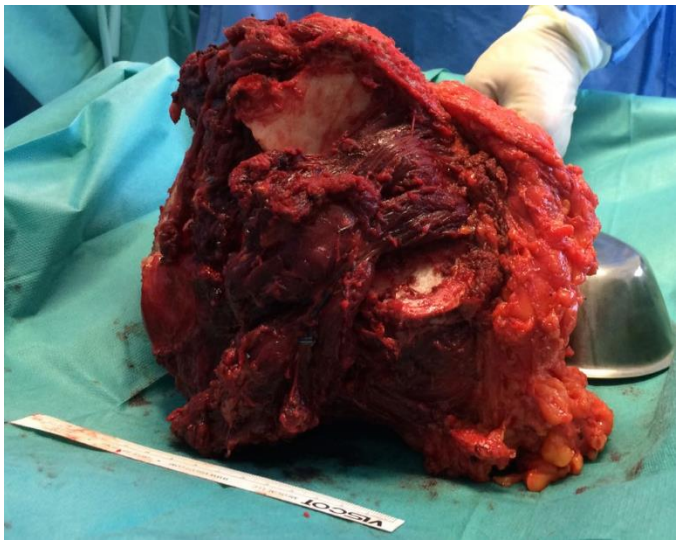

Figure 5 – Ressected Specimen

Discussion

Secondary chondrosarcoma is a tumor that arises from a preexisting cartilaginous lesion. Most commonly, it is associated with solitary or multiple osteochondromas [9]. A sudden increase in the size of the cartilaginous cap of an osteochondroma is a sign of malignant transformation to secondary chondrosarcoma [9]. Most cases of secondary chondrosarcoma are low to intermediate grade, meaning that distant metastasis are uncommon, and the prognosis is good for most patients [9,10].

The exact incidence of chondrosarcoma arising in osteochondroma is not known. Many authors agree that the incidence is between 0.4% and 2% in patients with solitary osteochondroma and between 5% and 25% in patients with multiple osteochondroma [10,11,12]. Nonetheless, the arising of a secondary chondrosarcoma is always a rare event.

In pelvic sarcomas, tumor grade is the most important predictor of the survival of the patients. While dedifferentiation is associated with a lower overall survival, low grade tumors had a higher

survival rate and lower metastatic probability [13]. On the other hand, surgical margins are the most important aspect to predict local recurrence, and in turn, local recurrence compromises the overall survival [13]. In the low-grade secondary chondrosarcomas, mean survival at 5 years is approximately 90% [9]. Surgical resection with wide margins is the best treatment option for palvic chondrosarcomas, nonetheless, local recurrence remains a problem because in many cases is difficult to obtain adequate surgical margins [14]. These issues are related to pelvic anatomy and the large volume that pelvic chondrosarcoma usually have at the time of diagnosis.

Since chondrosarcoma is not sensitive to radiotherapy or chemotherapy, extensive surgical resection is the most effective treatment. Aggressive surgical resection of pelvic chondrosarcoma results in long-term survival for the majority of patients [15].

Since the imaging studies of this particular clinical case showed no neurovascular, hip or sacro-iliac articulation, a limb sparing surgery maintaining the acetabulum and the sacro-iliac articulation, presented as a possibility and best treatment option. Avoid a post-surgery pelvic reconstruction is crucial, since surgery in these patients remains prone to complications. As an example, in one study, endoprosthetic reconstruction significantly increased the risk for developing complications [16]. Despite this aspect, a competing risk model in this same paper showed that the development of complications does not have a negative influence on overall survival [16,17,18,19].

Our goal for our patient was to achieve a wide resection minimizing the operative risks and the post-operative complications, avoiding reconstructions of the pelvic ring and/or hip articulation. In order to achieve this purpose, after a careful dissection and tumor exposure, we performed an anterior to posterior supra-acetabular osteotomy, which was associated with a posterior pre sacro-iliac vertical osteotomy, which was achieved without violation of the tumoral mass. With this procedure, we avoid the need for complex pelvic reconstruction. Nonetheless, in the pos-operative period, we still had a skin necrosis and bacterial super-infection as a complication, highlighting the high complication rates related to this kind of surgery, despite a careful planning and surgical execution.

Limb sparing surgery for pelvic tumors entails prolonged surgical time with exposure of the surgical field to the external environment, and risk for surgical wound infection is directly correlated with the duration of that exposure. Infection has been reported to be as high as 30% in some series [18]. The deavascularization of soft tissue flaps is a constant threat in large and complex dissection. This may lead to skin necrosis and dehiscence of the wound. Careful dissection and preservation of muscle vascularization, avoiding narrow soft tissue flaps and skin islands, minimizing tension across wounds during closure, judious use of soft tissue transfers to obliterate dead spaces after surgery and using drains to avoid deep hematomas are ways of protecting soft tissue necrosis. In our particular case, the huge resection performed led to a significant dead space, which further increased the risk of infection.

Conclusion

The case herein presented represents an example of a rare tumor with an unusual size which represents a truly challenge to achieve treatment. A proper diagnosis, surgical planning and surgical execution, developed by a multidisciplinary team, are mandatory to ensure a good oncologic

outcome with the less amount of complication. Nonetheless, complications are a possibility, which the multidisciplinary team needs to be ready to deal with.

References

1. de Andrea CE, Reijnders CM, Kroon HM, et al. Secondary peripheral chondrosarcoma evolving from osteochondroma as a result of outgrowth of cells with functional EXT. Oncogene. 2012 Mar;31(9):1095.
2. Donati D, Ghoneimy AE, Bertoni F, Di Bella C, Mercuri M. Surgical treatment and outcome of conventional pelvic chondrosarcoma. The Journal of bone and joint surgery. British volume. 2005 Nov; 87(11):1527-30.
3. PCW BF. Chondrosarcoma. World Health Organisation classification of tumours. In: Fletcher CDM Unni KK Mertens F, editors. Pathology and genetics of tumours of soft tissue and bone. Lyon, France: IARC Press. 2002:247-51.
4. Dorfman HD, Czerniak B, Kotz R, Vanel D, Park YK, Unni KK. WHO classification of tumours of bone: Introduction. World Health Organization classification of tumors. pathology and genetics of tumors of soft tissue and bone. IARC, Lyon. 2002:226-32.
5. Ozaki T, Hillmann A, Lindner N, Blasius S, Winkelmann W. Chondrosarcoma of the pelvis. Clinical Orthopaedics and Related Research®. 1997 Apr 1;337:226-39.
6. Capanna R, Van Horn JR, Guernelli N, Briccoli A, Ruggieri P, Biagini R, Bettellini G, Campanacci M. Complications of pelvic resections. Archives of orthopaedic and traumatic surgery. 1987 Feb 1;106(2):71-7.
7. Angelini A, Drago G, Trovarelli G, Calabrò T, Ruggieri P. Infection after surgical resection for pelvic bone tumors: an analysis of 270 patients from one institution. Clinical Orthopaedics and Related Research®. 2014 Jan 1;472(1):349-59.
8. Weber KL, Pring ME, Sim FH. Treatment and outcome of recurrent pelvic chondrosarcoma. Clinical Orthopaedics and Related Research (1976-2007). 2002 Apr 1;397:19-28.
9. Lin PP, Moussallem CD, Deavers MT. Secondary chondrosarcoma. JAAOS-Journal of the American Academy of Orthopaedic Surgeons. 2010 Oct 1;18(10):608-15.
10. Ahmed AR, Tan TS, Unni KK, Collins MS, Wenger DE, Sim FH. Secondary chondrosarcoma in osteochondroma: report of 107 patients. Clinical Orthopaedics and Related Research (1976-2007). 2003 Jun 1;411:193-206.
11. Garrison RC, Unni KK, McLeod RA, Pritchard DJ, Dahlin DC. Chondrosarcoma arising in osteochondroma. Cancer. 1982 May 1;49(9):1890-7.
12. Sheth DS, Yasko AW, Johnson ME, Ayala AG, Murray JA, Romsdahl MM. Chondrosarcoma of the pelvis: prognostic factors for 67 patients treated with definitive surgery. Cancer: Interdisciplinary International Journal of the American Cancer Society. 1996 Aug 15;78(4):745-50.
13. Mavrogenis AF, Angelini A, Drago G, Merlino B, Ruggieri P. Survival analysis of patients with chondrosarcomas of the pelvis. Journal of surgical oncology. 2013 Jul;108(1):19-27.
14. Ozaki T, Lindner N, Hillmann A, Rödl R, Blasius S, Winkelmann W. Influence of intralesional surgery on treatment outcome of chondrosarcoma. Cancer: Interdisciplinary International Journal of the American Cancer Society. 1996 Apr 1;77(7):1292-7.
15. Pring ME, Weber KL, Unni KK, Sim FH. Chondrosarcoma of the pelvis: a review of sixty-four cases. JBJS. 2001 Nov 1;83(11):1630-42.
16. Stihsen C, Panotopoulos J, Puchner SE, Sevelda F, Kaider A, Windhager R, Funovics PT. The outcome of the surgical treatment of pelvic chondrosarcomas: a competing risk analysis of 58 tumours from a single centre. The bone & joint journal. 2017 May;99(5):686-96.

17. Wilson RJ, Freeman Jr TH, Halpern JL, Schwartz HS, Holt GE. Surgical Outcomes After Limb-Sparing Resection and Reconstruction for Pelvic Sarcoma: A Systematic Review. JBJS reviews. 2018 Apr 1;6(4):e10.
18. Severyns M, Briand S, Waast D, Touchais S, Hamel A, Gouin F. Postoperative infections after limb-sparing surgery for primary bone tumors of the pelvis: Incidence, characterization and functional impact. Surgical oncology. 2017 Jun 1;26(2):171-7.
19. Puchner SE, Funovics PT, Böhler C, Kaider A, Stihsen C, Hobusch GM, Panotopoulos J, Windhager R. Oncological and surgical outcome after treatment of pelvic sarcomas. PloS one. 2017 Feb 15;12(2):e0172203.

Posterior Reversible Encephalopathy Syndrome- An Atypical Imaging Pattern

Síndrome De Encefalopatia Posterior Reversível - Um Padrão Imagiológico Atípico

Francisco Ornelas Raposo[1], Manuel Amorim Correia[1], Sofia Rodrigues[2], Isabel Amorim[3], Luísa Albuquerque[3], Filipa Falcão[3], Rita Sousa[1], Graça Sá[1]

1- Serviço de Imagiologia Neurológica do Centro Hospitalar Lisboa Norte; 2- Serviço de Neurologia do Hospital da Luz, Lisboa; 3- Serviço de Neurologia do Centro Hospitalar Lisboa Norte

Resumo

A síndrome de encefalopatia posterior reversível caracteriza-se por um quadro neurológico de instalação aguda/subaguda de alterações visuais, cefaleias, crises ou alteração do estado de consciência associado, na maioria dos casos, a valores elevados de tensão arterial sistémica. Caracteriza-se, do ponto de vista imagiológico, pelo aparecimento de áreas de edema vasogénico tipicamente nos lobos parietais e occipitais de modo simétrico, no território das artérias cerebrais posteriores reconhecendo-se, contudo, a existência de outros padrões topográficos de envolvimento do sistema nervoso central.

Reportamos o caso de um doente do sexo masculino com 43 anos, referenciado ao serviço de urgência por quadro de diminuição da acuidade visual e papiledema bilateral e simétrico, associado a valores de tensão arterial muito elevados. O estudo imagiológico conduziu à identificação de múltiplas lesões edematosas a interessar o tronco cerebral e núcleos da base, compatível com um padrão atípico de síndrome de encefalopatia posterior reversível. A investigação realizada durante o internamento permitiu a identificação de lesões de órgão-alvo secundárias à hipertensão arterial, nomeadamente retinopatia, cardiomiopatia e nefropatia.

Palavras-chave: Síndrome de encefalopatia posterior reversível, hipertensão arterial, imagiologia, atípico.

Abstract

Posterior reversible encephalopathy syndrome is characterized by an acute/subacute onset of neurological alterations including visual impairment, headache, seizures or altered mental status associated, in most cases, with elevated values of systemic blood pressure.

It is characterized, imagiologically, by the development of areas of vasogenic edema, typically affecting parietal and occipital lobes symmetrically, in the territory of posterior cerebral arteries, being also recognized other topographic patterns of central nervous system involvement.

We report the case of a 43-year-old male sent to the emergency department after onset of visual impairment and bilateral symmetrical papilledema, associated with very high blood pressure. The imaging investigation led to the identification of multiple edematous lesions affecting the brainstem

and basal ganglia, compatible with an atypical imaging presentation of posterior reversible encephalopathy syndrome. Clinical and laboratorial investigation allowed the identification of target organ damage secondary to the hypertension, namely retinopathy, cardiomyopathy and nephropathy.
Keywords: Posterior reversible encephalopathy syndrome, arterial hypertension, atypical, radiology

Introdução:

A síndrome de encefalopatia posterior reversível (PRES) é caracterizada por um quadro neurológico de instalação aguda ou subaguda, incluindo alterações visuais, cefaleias, crises ou alteração do estado de consciência associado, na maioria dos casos, a valores de tensão arterial sistémica elevados, nomeadamente com valores de tensão arterial sistólica geralmente superiores a 170mmHg. Contudo, reconhece-se que cerca de 10-30% dos doentes apresentam valores de tensão arterial normais ou apenas ligeiramente elevados. As causas mais comuns de hipertensão nos doentes com PRES são a lesão renal aguda e a pré-eclampsia/eclampsia, podendo também surgir associado a alterações disautonómicas, a doenças auto-imunes, a sépsis ou em reação a fármacos [1,2,3].

Do ponto de vista fisiopatológico, a teoria mais aceite explica o PRES como consequência da perda de auto-regulação do fluxo sanguíneo cerebral, normalmente preservado para tensões arteriais médias inferiores a 150mmHg, com consequente lesão vascular, que se traduz por edema vasogénico secundário à transudação de proteínas e fluidos para o espaço intersticial. Dada a heterogeneidade dos casos, outras teorias têm sido desenvolvidas para explicar esta patologia, nomeadamente apontando a disfunção endotelial e perda da integridade da barreira hemato-encefálica como principal mecanismo fisiopatológico, dada a sua ocorrência em doentes com valores de tensão arterial normais ou apenas ligeiramente elevada, em casos de síndrome de resposta inflamatória sistémica ou sépsis [1,2,3].

As lesões são mais prevalentemente encontradas nos lobos parietais e occipitais de modo simétrico, no território das artérias cerebrais posteriores, justificando a designação da síndrome como “posterior”. No entanto, pode envolver topografias distintas, reconhecendo-se como principais padrões o parieto-occipital, holohemisférico, em território de barragem e o sulcal frontal superior. Em menos de 5% dos casos, pode ocorrer envolvimento exclusivo do tronco cerebral ou dos núcleos da base [2,3].

No que toca à investigação imagiológica, a tomografia computorizada (TC) crânio-encefálica é habitualmente o primeiro exame realizado, permitindo excluir outras etiologias, nomeadamente hematomas, ou adivinhar sinais de lesões ocupando espaço, lesões isquémicas recentes ou tromboses venosas. A ressonância magnética (RM) crânio encefálica permite identificar a presença de edema vasogénico, com áreas de hipossinal T1, hipersinal T2/FLAIR, estudo de difusão normal ou facilitada. Pode observar-se restrição à difusão, sendo este um sinal de potencial irreversibilidade das lesões. Identificam-se, em até metade dos casos, microhemorragias em estudo de susceptibilidade magnética (SWI) [1,3,4]. Existem o entanto quadros atípicos em que o diagnóstico

é apenas confirmado com a reversibilidade das alterações imagiológicas após correção do fator precipitante.

Os controlos dos factores de risco identificados, nomeadamente da hipertensão arterial, são geralmente suficientes para atingir resolução do quadro clínico em alguns dias. As alterações imagiológicas são, também, na maioria dos casos, reversíveis, podendo persistir até cerca de 4 semanas após normalização do quadro clínico. A eficácia dos corticoesteróides sistémicos não está comprovada. A ausência de controlo e normalização dos factores identificados como etiológicos conduz, numa significativa percentagem dos casos, ao estabelecimento de lesões irreversíveis [1,2,3].

Caso Clínico

Doente do sexo masculino, 43 anos de idade, leucodérmico, militar da Guarda Nacional Republicana, com antecedentes pessoais de dislipidémia, medicada em ambulatório com atorvastatina, e hipertensão arterial crónica não medicada. Recorreu ao serviço de urgência (SU) do Hospital de Santa Maria (HSM) encaminhado de uma consulta privada de Oftalmologia, à qual tinha recorrido por quadro de diminuição da acuidade visual do olho direito com cerca de quinze dias de evolução, sem outra sintomatologia acompanhante. No SU foi observado por oftalmologista que identificou, à avaliação do fundo ocular, papiledema bilateral, com hemorragias e exsudatos moles peripapilares. Face às alterações encontradas, foi pedida observação pela Neurologia. Ao exame neurológico, o doente apresentava-se vígil, colaborante, sem sinais focais. Salientava-se a presença de valores de pressão arterial marcadamente elevados, com pressão arterial sistólica superior a 220mmHg e pressão arterial diastólica superior a 180mmHg. Não apresentava alterações à auscultação cardíaca ou pulmonar. No SU, a TA foi controlada com recurso a múltiplas terapêuticas anti-hipertensoras, nomeadamente perfusão endovenosa de labetalol. Neste contexto, realizou tomografia computorizada (TC) crânio-encefálica, onde se evidenciava a presença de hipodensidade difusa e aspetto insuflado do mesencéfalo e da ponte, aspettos que colocavam como diagnóstico diferencial lesão neoplásica (e.g. glioma do tronco), vascular ou inflamatória/infecciosa. Para melhor esclarecimento destes achados, foi realizada uma ressonância magnética (RM) crânio-encefálica, onde se observava a presença da mesma lesão ponto-mesencefálica insuflativa com extensão aos pedúnculos cerebelosos médios e à vertente ântero-superior da medula alongada, com limites mal definidos, iso/hipointensa em T1, hiperintensa nas sequências T2 FLAIR, sem restrição à difusão das moléculas de água e sem realce após administração endovenosa de gadolínio, com modesto efeito de massa a condicionar redução da amplitude dos espaços de líquor cisternais adjacentes. Adicionalmente, identificavam-se lesões intra-axiais com semelhante comportamento de sinal, mas de menores dimensões, em ambos os hemisférios cerebelosos, tálamos, cápsulas internas, coroas radiárias e centros semi-ovais, achados que mantinham diagnóstico diferencial entre lesões inflamatórias (e.g. encefalomielite aguda disseminada, esclerose múltipla, neuro-Behçet) e lesões de natureza vascular, (e.g. síndrome de encefalopatia posterior reversível). Em T2* identificavam-se ainda focos milimétricos de hipossinal, traduzindo sequelas de micro hemorragias núcleo-basais, frequentes na microangipatia hipertensiva por rotura de microaneurismas de Charcot-Bouchard. A multifocalidade das lesões tornava menos provável a

hipótese de glioma do tronco e, a ausência de realce após administração de gadolínio, de se tratarem de metástases. O estudo analítico evidenciava lesão renal aguda, com valores de creatinina séria de 1,4mg/dL por provável nefropatia hipertensiva, o que também se enquadrava no achado das micro hemorragias sequelares.

O doente foi internado no serviço de Neurologia para investigação etiológica, onde se manteve durante 17 dias. Ao longo de todo o internamento, manteve-se estável, sem alterações "de novo" no exame neurológico. Durante a primeira semana de internamento, manteve valores de pressão arterial elevados, com necessidade de otimização da terapêutica anti-hipertensora, atingindo finalmente valores de tensão arterial sistólica entre 120-130mmHg e diastólica entre 60-95 mmHg.

Realizou punção lombar com estudo citoquímico normal e exame bacteriológico, micológico, serologias para criptococos, sífilis, citomegalovirus, vírus Epstein-Barr, *Borrelia burgdoferi*, pesquisa de vírus herpes e pesquisa de células neoplásicas negativos. Fez ainda estudo com doppler dos vasos do pescoço, bem como Doppler transcraniano, que não revelaram alterações.

Analiticamente, o valor de proBNP e creatinina sérica encontravam-se alterados (NT proBNP 2169 pg/mL, Creatinina 1,40 mg/dL). Não foram detetadas outras alterações no estudo da hipertensão secundária, nomeadamente com função tiroideia e eixo hipotálamo/hipófise/supra-renal preservados. O ecodoppler das artérias renais não identificou alterações patológicas das mesmas. A investigação adicional para pesquisa de lesão de órgão-alvo permitiu identificação de retinopatia hipertensiva por retinografia, dilatação e hipertrofia do ventrículo lateral esquerdo e compromisso generalizado da fração de ejeção ventricular no estudo ecocardiográfico, bem como lesão isquémica renal esquerda na TC abdominal superior.

Tendo em conta o quadro clínico, nomeadamente os valores tensionais elevados e lesão de órgão-alvo, (retina, coração e rim), o envolvimento do sistema nervoso central com os achados imagiológicos supramencionados aponta para uma mais provável etiologia vascular. O doente teve alta hospitalar mantendo-se assintomático com esquema terapêutico anti-hipertensor optimizado, aguardando por repetição de RM crânio-encefálica às quatro semanas após a apresentação. No controlo imagiológico confirmou-se a resolução da maioria das lesões previamente observadas, achados que suportam o diagnóstico de Síndrome de Encefalopatia Posterior Reversível (PRES), com envolvimento isolado atípico do tronco cerebral e dos núcleos da base.

Discussão

As alterações neurológicas fazem parte de um grupo significativo de queixas que conduzem a população aos serviços de urgência hospitalares. As alterações visuais, as cefaleias ou mesmo as alterações do estado de consciência representam uma parcela importante destas. Síndromes como o PRES relembram os clínicos para a importância da compreensão do doente como um todo e da multi-organicidade de um elevado número de patologias que, muitas vezes, são estudadas de modo fracionado pelas especialidades médicas ou cirúrgicas a quem os sintomas podem dizer respeito, sem a procura por um elo de ligação. O caso por nós descrito representa uma

apresentação atípica do ponto de vista imagiológico, por se evidenciar um padrão raro de distribuição das lesões. No entanto, apesar da apresentação imagiológica atípica, a co-existencia de micro hemorragias sequelares núcleo-basais num adulto jovem, com valores tensionais elevados, favorecem a hipótese de PRES em detrimento das restantes etiologias. A resolução do quadro imagiológico com o controlo da pressão arterial corrobora o diagnóstico.

Apesar de permanecer mal-esclarecido, a integridade e dinâmica vasculares desempenham um papel central na fisiopatologia da doença, apresentando-se a hipertensão arterial como o fator mais prevalentemente associado a estas alterações.

Conclusão

Este caso constituiu um desafio diagnóstico para o neurorradiologista, requerendo conhecimentos avançados, domínio clínico das patologias que se apresentam com as alterações neurológicas e imagiológicas enunciadas, bem como capacidade de integração de informação clínica multidisciplinar. A possibilidade de reverter na totalidade o quadro clínico salienta a importância de considerar esta hipótese diagnóstica e de reunir dados que apoiem a sua identificação.

Referências

1. Hobson EV, Craven I, Blank SC. Posterior Reversible Encephalopathy Syndrome: A Truly Treatable Neurologic Illness. *Peritoneal Dialysis International : Journal of the International Society for Peritoneal Dialysis*. 2012;32(6):590-594.
2. Sudulagunta SR, Sodalagunta MB, Kumbhat M, Settikere Nataraju A. Posterior reversible encephalopathy syndrome(PRES). *Oxford Medical Case Reports*. 2017;2017(4).
3. Bartynski WR. Posterior Reversible Encephalopathy Syndrome, Part 1: Fundamental Imaging and Clinical Features. *American Journal of Neuroradiology*. 2018; 29(6); 1036-1042.
4. Bartynski WS and Boardman JF. Distinct Imaging Patterns and Lesion Distribution in Posterior Reversible Encephalopathy Syndrome. *American Journal of Neuroradiology*. 2007; 28(7); 1320-1327.

Schizoaffective disorder: how long does it takes to diagnose?

Perturbação esquizoafectiva: quanto tempo demora para o diagnóstico?

Maria João Gonçalves[1]; Marta Croca[1];Rodrigo Saraiva[1]; Carla Ferreira[1]; Carolina Sereijo[1]; Custódio Rodrigues[1]

Department of Psychiatry and Mental Health, Centro Hospitalar Lisboa Norte, EPE

Resumo

O diagnóstico psiquiátrico está sujeito a variabilidade e subjetividade inerentes à evolução da patologia em causa. É relatado o caso de uma mulher de 57 anos com múltiplas hospitalizações psiquiátricas (2010-2018), durante as quais diferentes hipóteses diagnosticas e terapêuticas associadas foram propostas. Após análise dos registos clínicos e discussão com a equipa de internamento, foi proposto o diagnóstico de Perturbação Esquizoafetiva (PE). A PE apresenta um elevado risco de re-internamento, para além do custo associado ao abandono de seguimento clinico e terapêutico. Porém, não existem dados suficientes que avaliem os períodos críticos pós-alta. Portanto, torna-se necessária uma pesquisa mais ampla nesta área, no sentido de adotar estratégias e intervenções psicoterapêuticas eficazes de modo a reduzir a probabilidade de internamento hospitalar e, deste modo, melhorar o prognóstico, minimizando os custos associados.

Palavras-chave: variabilidade, subjetividade, diferentes diagnósticos, Perturbação Esquizoafetiva, re-internamento, prognóstico.

Abstract

Psychiatric diagnosis faces the challenge of variability and subjectivity associated with the evolution of the psychiatric illness. It is reported a case of a 57-year-old woman with multiple psychiatric hospitalizations (2010-2018), during which different diagnostic hypotheses and therapeutic were proposed. After analyzing the patients clinical records, the hospital's psychiatric medical team proposed the diagnosis of Schizoaffective Disorder (SD). SD presents a high risk of recurrent hospitalizations and high costs associated with therapeutic and follow-up withdrawal, but there is limited data to assess the post-discharge critical periods.Further research in this area is required in order to adopt effective psychotherapeutic strategies and interventions in order to reduce the probability of hospital admissions and improve prognosis, reducing associated costs.

Keywords: variability, subjectivity, different diagnoses, Schizoaffective Disorder, re-hospitalization, prognosis

Introduction

Jacob Kasanin (1933) introduced the term schizoaffective psychosis to capture the co-occurrence of both schizophrenia and affective symptoms [1]. The diagnosis of schizoaffective disorder (SD) was associated with better premorbid functioning, less severe symptomatology, overall shorter duration of illness and improved recovery as compared to patients with schizophrenia [2]. The diagnosis of SD remains controversial because of poor reliability, low stability and weak validity [3]. SD is not a rare diagnosis in psychiatry. An European epidemiological study reported a prevalence of schizoaffective disorder of 1.1%, and in the Suffolk County Mental Health Project (New York, USA), 4.8% of first admission patients with psychosis were diagnosed as schizoaffective [4].

Case Report

We present the case of a 57-year-old caucasian Portuguese woman, single, with a son. The patient completed the 9th grade and is retired for more than 5 years, apparently due to psychiatric illness (she worked as a cleaning maid in her last job). The patient is currently living in Lisbon, at a friend's house.

The patient has a medical history of chronic obstructive pulmonary disease (emphysema) since 2010 and hypothyroidism since 2013; consumes tobacco (36 pack-years), and has no history of other substance abuse. There is no history of mental disorders in the patient´s family. The patient´s psychiatric follow-up started at 49 years old (2009), with multiple associated psychiatric hospitalizations, all of them at our inpatient psychiatric unit, which we will briefly describe (Table 1).

Table 1: *Summary of hospitalizations and respective diagnostic hypotheses*

First hospitalization **2010**	*PAB type III and secondary hypomanic episode*
Second hospitalization **2011**	*Undifferentiated Somatoform Disorder and Personality Disorder NOS*,
Third hospitalization **2013**	*Schizoaffective Disorder (depressive type)*
Fourth hospitalization **2014**	*Depressive episode with psychotic symptoms (hypochondriacal delusion)*
Fifth hospitalization **2016**	*Schizoaffective Disorder (bipolar)*
Sixth hospitalization **2016**	*Recurrent major depressive disorder*
Seventh hospitalization 2018	*Schizoaffective Disorder (depressive type)*

- First hospitalization (2010), due to depression with somatic complaints (low back pain). After treatment with antidepressants she presented with a manic episode. On discharge, she was stable, euthymic, with regularization of the sleep-wake cycle, but with residual overvalued hypochondriacal ideas. The diagnosis of A*ffective Bipolar Disorder type III and Secondary Hypomanic Episode* was proposed and the following therapy was prescribed: Valproate sodium (VPA) 1000mg 2id; Olanzapine 20mg and Lorazepam 1mg.

The follow-up was made by a psychiatrist from our hospital (2011), who described several visits to the Emergency Department of Curry Cabral Hospital with "dyspnea and anxiety" as well as an episode of voluntary drug intoxication (VDI), "without intention of dying ".The patient abandoned the treatment of VPA on her own initiative, which was reintroduced (300mg 2id) and added Sertraline 50mg id. At that time the patient retired for "psychiatric illness" by the attending physician.

- Second hospitalization (2011) due to depressed mood, anhedonia, almost total insomnia, anorexia, refusal of medication intake and odynophagia. On discharge, residual overvalued hypochondriac ideas persisted. A diagnosis of *Undifferentiated Somatoform Disorder and Personality Disorder NOS* was made, and the following therapy was prescribed: Sertraline 100mg 2id; VPA 750mg 2id; Quetiapine 300mg id and Alprazolam 0.5mg 3id. At this time the patient was proposed to attend an Outpatient Day Program, which the patient ended up leaving 2 months later. She also abandoned the follow-up with her psychiatrist in 2012.
- Third hospitalization (2013) characterized by psychotic symptomatology (auditory hallucination in the 3rd person, delusions of self-reference, persecutory ideation, social isolation and behavioral disorganization. She was discharged after the remission of the psychotic symptoms, but with feelings of hopelessness, irritability and depressive mood. The diagnosis of SD *(depressive type)* was proposed and the following therapy was prescribed: Risperidone 1mg 2id, Sertraline 50mg 2id, Mirtazapine 30mg, Trazodone 100mg, VPA 500mg 2id and, Oxazepam 15mg 3id. The patient was referred to a socio-occupational group (which abandoned). In February 2014, the patient presented with asthenic complaints, abuse of BZD's, poor adherence to therapy and hypochondriacal concerns. The patient also neglected her hygiene and was taking medication on an irregular basis.
- Fourth hospitalization (2014) due to depressed mood, food and medication refusal associated with odynophagia ("she thought she had esophageal cancer"). At discharge the patient was euthymic, with improvement of the hypochondriacal delusion. The diagnosis of *Depressive episode with psychotic symptoms (hypochondriacal delusion)* was assumed, and the following therapy was prescribed: Risperidone 2mg id, VPA 500mg 2id; Oxazepam 15; Trazodone 100mg; Sertraline 100mg; Mirtazapine 15mg.
- Fifth hospitalization (2016) due to depressed mood, anhedonia and reduction of vital energy, the patient was diagnosed with *SD (bipolar)* and was discharged with the following medication: VPA 1000 id, quetiapine 25mg id, risperidone 2mg id and, sertraline 100mg id.

The patient had multiple visits to the emergency department with somatic complaints and was hospitalized in an Internal Medicine department in order to study the dysphagia's etiology. During that time, the patient was observed by the liaison psychiatry that described "diffuse and poorly structured somatic symptomatology, placing the hypothesis of dramatization of complaints to maintain hospital admission".

At the sixth hospitalization (2016) she presented with multiple somatic complaints (lower back pain, limb paresthesia, dysphagia and generalized non-specific pain), prostration, clinophilia,

anhedonia, hygiene neglect and hypochondriac ideas. The diagnose of *Recurrent Major Depressive Disorder* was made and the following therapy was prescribed: venlafaxine 150 mg, olanzapine 10mg and bromazepam 3mg.

For several times the patient left the proposed therapy and refused ambulatory help (outpatient day program) and was stable until November 2017, when after the interruption of the prescribed therapy, initiated depressed mood, clinophilia, anorexia, self-care carelessness and suicidal ideation, referred pain in the lumbar spine and in the joints (knees, shoulders). This clinical condition led to another hospitalization in 2018 (the seventh hospitalization).

During the first days of the hospitalization the affective and somatoform complaints were maintaiened (clinofilia, reduced collaboration in the service activities and clinical interviews). The medical team prescribed a mood stabilizer (VPA at a dose of 600mg id), an antidepressant (switch from Venlafaxine to Clomipramine titrated up to a dose of 100mg) and an antipsychotic (switch from Olanzapine to Haloperidol initially titrated up to a dose of 15mg and then reduced to 5mg id).

Both physical and neurological examination, complete blood analysis and search for toxics showed no relevant results, the same for other complementary diagnostic exams (electrocardiogram, renal ultrasound and a cranial magnetic resonance). Neuropsychological assessment was performed and reported moderate to severe changes in executive functions, moderate changes in immediate verbal learning and associative learning, and slight changes in episodic memory and visual-perceptual abilities. Compared to the previous evaluation period (2010-03-29), there was a deterioration of performance in executive functions.

At the discharge the patient had a clear improvement from both the affective and behavioral perspective. The patient also had a decrease of the pain complaints. The diagnosis of *SD of the depressive type* was established and the following therapy was prescribed: VPA 600mg, haloperidol 5mg, amitriptyline 100mg and oxazepam 15mg. The patient returned to her friend's house and accepted house support. (Figure 1: Biopatography)

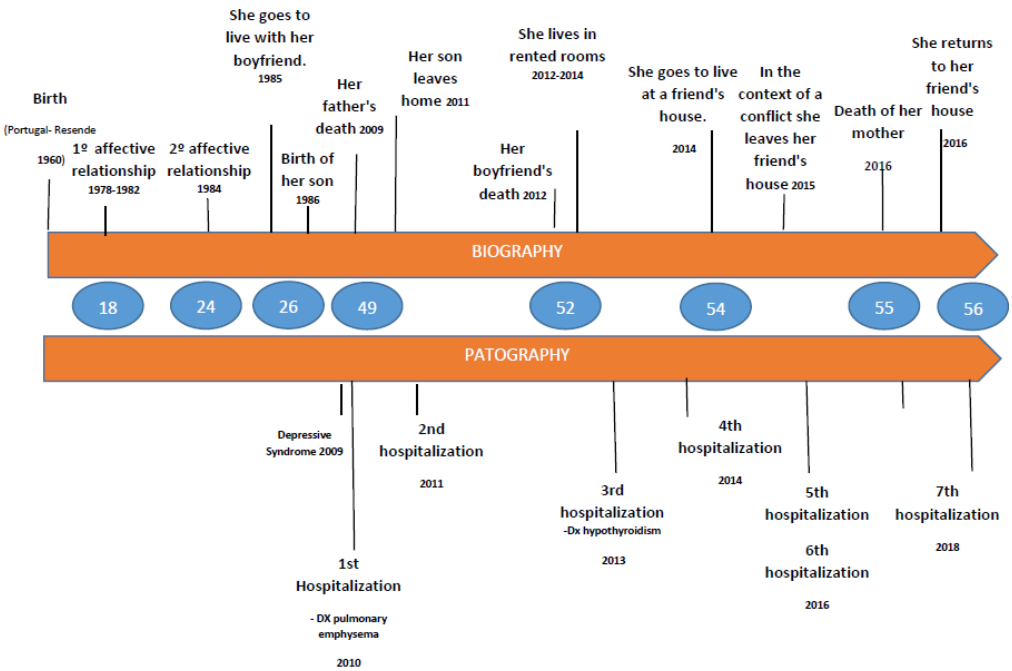

Figure 1: Biopatography

Discussion

We presented a case of a 57-year-old woman with multiple psychiatric hospitalizations (between 2010 and 2018), during which different diagnostic hypotheses and therapeutics were proposed.

Based on the clinical evolution of the patient we proposed the diagnose of SD. This disorder has undergone shifting conceptualizations in the different Diagnostic and Statistical Manual (DSM) editions. Up until the most recent edition, the DSM-5 (table 2), the most influential historical perspective was that of Kraepelin (1920) who proposed that there is a dichotomy between the diagnoses of Schizophrenia (dementia praecox) versus psychotic Mood Disorders (manic-depressive insanity). According to this dichotomous perspective, avolition, decreased emotional expression, cognitive deterioration and a poor outcome are associated with Schizophrenia, whereas the psychoses associated with depression or mania have a better outcome and an expectation of inter-episode recovery. This dichotomous view sits uneasily with the observation that a substantial portion of cases meeting the criteria for Schizophrenia experience episodes of Mood Disorder as well as having periods of non-affective psychosis [3].

Table 2: DSM-V criteria: Schizoaffective Disorder *(3)*

A. An uninterrupted period of illness during which there is a major mood episode (major depressive or manic) concurrent with Criterion A of schizophrenia. Note: The major depressive episode must include Criterion A1: Depressed mood.

B. Delusions or hallucinations for 2 or more weeks in the absence of a major mood episode (depressive or manic) during the lifetime duration of the illness.

C. Symptoms that meet criteria for a major mood episode are present for the majority of the total duration of the active and residual portions of the illness. D. The disturbance is not attributable to the effects of a substance (e.g., drug of abuse, medication) or another medical condition.

Specify whether:

Bipolar type: This subtype applies if a manic episode is part of the presentation. Major depressive episodes may also occur.

Depressive type: This subtype applies if only major depressive episodes are part of the presentation.

With catatonia: This specifier, which applies to both 295.70(F25.1)Schizoaffective Disorder, with prominent depressive symptoms, and 295.70 (F25.0) Schizoaffective Disorder, with prominent Manic Symptoms, may be used to specify a current episode with at least three of the following: catalepsy, waxy flexibility, stupor, agitation, mutism, negativism, posturing, mannerisms, stereotypies, grimacing, echolalia, and echopraxia.

Overall, the overlap of symptoms of SD with those of schizophrenia and bipolar disorder makes the clinical diagnosis difficult [5] and the complex interplay of symptoms poses challenges to treatment which are frequently managed by polypharmacy. This increases the complexity of treatment with higher probability of treatment non-adherence, drug interactions, and higher cost of therapy. As a chronic condition, SD requires long-term pharmacologic treatment that includes acute treatment, to manage symptom exacerbations and maintenance therapy, to lower the risk of relapse. Pharmacologic treatment generally includes antipsychotics used in combination with mood

stabilizers or antidepressants [6]. Given that pharmacological treatment plays a key role in SD management, it is important that patients receive continuous effective coverage with them. Patients with schizophrenia or SD who use medication irregularly are approximately twice as likely to be recurrently hospitalized and have 12 % higher inpatient costs than patients who use their medication regularly [7]. Additionally, hospitalized patients with SD have an increased likelihood of relapse and rehospitalization immediately following hospital discharge. The risk is even greater for patients with schizophrenia [6]. As mentioned in the "case report" section, in the present case the patient has abandoned for several times the proposed therapy and refused ambulatory help, which led to the need for new hospitalizations (seven hospitalizations between 2010 and 2018).

In short-term and long-term outcome studies, SD had a significantly better prognosis than schizophrenia. Long-term outcome for patients diagnosed with SD paralleled that of affective disorder patients [2].

Conclusion

The psychiatric diagnosis faces the challenge of subjectivity and variability among clinicians according to the evolution pattern of the disease over the years. In fact, a single patient may have different diagnoses made and different therapeutics initiated. Patients with hospital discharge and SD present a high risk of re-hospitalization. However, there is limited data to assess the post-discharge critical periods, during which the risk of re-hospitalization is significant. Thus, further research in this area is required in order to adopt effective psychotherapeutic strategies and interventions to reduce the probability of hospital admissions and improve prognosis, reducing the associated costs of SD.

References

1. Kasanin J. The acute schizoaffective psychoses. 1933. The American journal of psychiatry. 1994;151(6 Suppl):144-54.
2. Wilson JE, Nian H, Heckers S. The schizoaffective disorder diagnosis: a conundrum in the clinical setting. European archives of psychiatry and clinical neuroscience. 2014;264(1):29-34.
3. Malaspina D, Owen MJ, Heckers S, Tandon R, Bustillo J, Schultz S, et al. Schizoaffective Disorder in the DSM-5. Schizophrenia research. 2013;150(1):21-5.
4. Scully PJ, Owens JM, Kinsella A, Waddington JL. Schizophrenia, schizoaffective and bipolar disorder within an epidemiologically complete, homogeneous population in rural Ireland: small area variation in rate. Schizophrenia research. 2004;67(2-3):143-55.
5. Malhi GS, Green M, Fagiolini A, Peselow ED, Kumari V. Schizoaffective disorder: diagnostic issues and future recommendations. Bipolar disorders. 2008;10(1 Pt 2):215-30.
6. Murru A, Pacchiarotti I, Nivoli AM, Grande I, Colom F, Vieta E. What we know and what we don't know about the treatment of schizoaffective disorder. European neuropsychopharmacology : the journal of the European College of Neuropsychopharmacology. 2011;21(9):680-90.
7. Svarstad BL, Shireman TI, Sweeney JK. Using drug claims data to assess the relationship of medication adherence with hospitalization and costs. Psychiatric services (Washington, DC). 2001;52(6):805-11.

Cistinose: Descrição de dois Casos Clínicos

Cystinosis: Two case reports

Nuno Gaibino (1), Inês Leal (2), Joana Santos (1), Daniel Gomes (1), Anabela Oliveira (1)

(1) Serviço de Medicina I CHLN - Clínica Universitária de Medicina I FMUL; (2) Serviço de Oftalmologia CHLN-Clínica Universitária de Oftalmologia FMUL

Resumo

A **Cistinose** é uma doença metabólica autossómica recessiva, caracterizada pela acumulação de cistina, devido a uma deficiência no transporte de cistina para o exterior dos lisossomas. A **cistinose clássica ou infantil**, apresenta-se precocemente, normalmente com doença renal tubular - *Síndrome de Fanconi*, disfunção glomerular progressiva, atraso no crescimento e fotofobia precoce por depósito de cristais de cistina na córnea. A **cistinose juvenil**, é outra das formas da doença, sendo a sua manifestação mais tardia. A **cistinose não nefropática** é uma entidade rara, apresentando-se apenas com sintomas oftalmológicos. Da nossa casuística destacamos 2 casos clínicos: **Cistinose Infantil -** mulher de 43 anos, com diagnóstico aos 18 meses, que apresenta doença renal crónica, atraso no crescimento, baixa acuidade visual bilateral e patologia endocrinológica múltipla. **Cistinose Juvenil -** Homem de 40 anos, com diagnóstico de cistinose juvenil aos 18 anos. Status pós transplante renal, défice no crescimento, hipotiroidimso, hiperparatiroidismo e envolvimento querático bilateral importante.

Palavras-Chave: cistinose; cistina; cisteamina, lisossoma, doenças metabólicas hereditárias.

Introdução

As doenças metabólicas hereditárias são defeitos bioquímicos geneticamente determinados, cujo efeito está na gênese de uma determinada patologia. Todas as doenças metabólicas hereditárias apresentam uma baixa incidência no adulto, sendo as mesmas consideradas doenças raras.

A cistinose é uma doença metabólica autossómica recessiva, caracterizada pela acumulação de cistina em diferentes tecidos, devido a uma deficiência no transporte de cistina para o exterior dos lisossomas. A cistina provem da degradação proteica, sendo normalmente transportada do lisossoma, local de degradação, para o citoplasma celular, sendo ai transformado em cisteína. Na cistinose a acumulação deste metabolico ocorre ao nível lisossomal, dado o defeito genético que codfifica a cistinosina que é uma proteina da membrana lisossomal responsável pelo seu transporte. A sua prevalência é de aproximadamente de 1:100000 a 1:200000 [1-3]. O gene responsável pela doença - CTNS, está localizado no cromossoma 17.

A **cistinose clássica ou infantil**, apresenta-se precocemente, nos primeiros 6 a 16 meses de vida. Normalmente caracteriza-se como uma doença renal tubular - *Síndrome de Fanconi (*poliúria, polidípsia, desidratação e acidose), disfunção glomerular progressiva, atraso no

crescimento e fotofobia precoce por depósito de cristais de cistina na córnea. Concomitantemente a patologia endocrinológica é uma das formas de apresentação frequente, nomeadamente hipertiroidismo, hipogonadismo e diabetes insulino-dependente [4].

A **cistinose juvenil ou intermédia**, é outra das formas da doença, sendo a sua manifestação mais tardia, entre os 12 e 28 anos [5,7].

A **cistinose não nefropática ou ocular** é uma entidade rara, apresentando-se apenas com sintomas oftalmológicos [6].

O diagnóstico é efectuado através da determinação intraleucocitária de cística, identificação de depositos de cística na córnea ou através do teste genético com identificação do gene CTNS.

A terapêutica cursa com um regime alimentar personalizado, tratamento das manifestações secundárias, frequentemente endocrinológicas, e terapêutica dirigida à deplecção de cística - cisteamina [8-10]. Esta inovação terapêutica foi fundamental para a melhoria substancial do prognóstico funcional e vital dos doentes.

Caso 1 - Cistinose Infantil

Doente de 43 anos, género feminino, com diagnóstico de cistinose aos 18 meses de idade. Do acompanhamento clinico desta-se seguimento em múltiplos centros, nacionais e internacionais, contudo sem terapêutica dirigida e apresentando a evolução natural da doença. O quadro clínico foi carcateriza-se por uma lesão renal crónica progressiva, sendo instituída técnica de substituição renal. Submetida a transplante renal em 1981, com disfunção do enxerto documentada em 2009, tendo retornado a técnica de substituição renal. Concomitantemente apresentou um envolvimento sistémico extenso com endocrinopatia múltipla com diabetes insulino-tratada, hipotiroidismo, insuficiência supra-renal, menopausa precoce e osteoporose. Destaca-se ainda um atraso no crescimento com baixa estatura. O desenvolvimento nos últimos anos pautou-se pela diminuição da acuidade visual progressiva. Por tal motivo, a doente foi encaminhada para o centro de referência de doenças metabólicas hereditárias do adulto, retomando acompanhamento médico multidisciplinar permanente.

Da avaliação laboratorial destaca-se uma determinação 7,31 µmol/g proteína de cística intra-leucocitária (Valores normais <0,3 µmol/g proteína). Da avaliação oftalmológica destaca-se uma diminuição grave da acuidade visual bilateral, com percepção apenas de vultos. Confirmada queratopatia em banda com calcificação e panos vascular da córnea bilateralmente (Figura 1).

Apesar do envolvimento sistémico múltiplo da doença, foi decidido a instituição de terapêutica de depleção de cística com cisteamina tópica, com o intuito de evitar a maior progressão da doença.

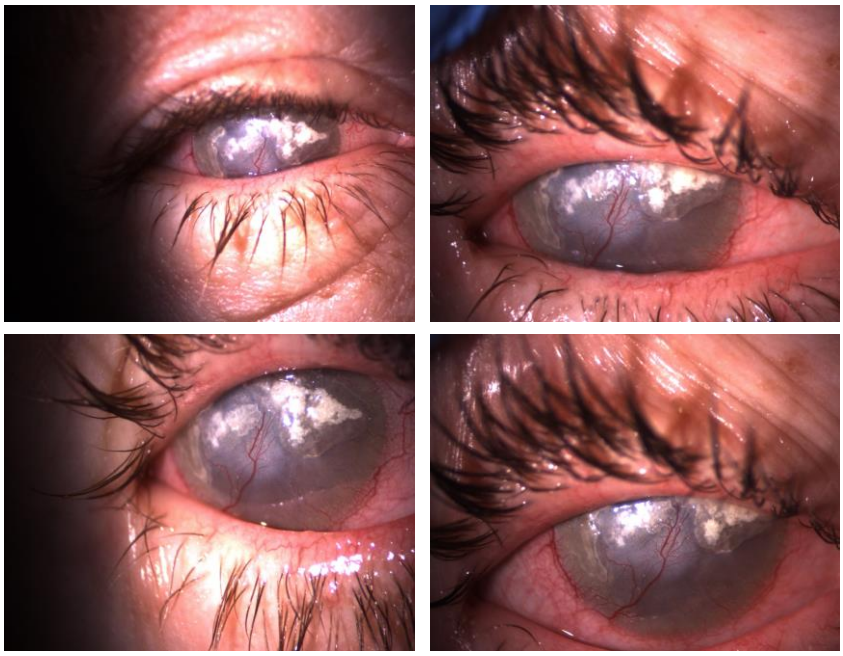

Figura 1

Caso 2 - Cistinose Juvenil

Doente de 40 anos, género masculino, com diagnóstico de cistinose juvenil aos 18 anos de idade. Da história pregressa do doente destaca-se uma doença renal crónica progressiva, necessitando de início de técnica de substituição renal. Em 1996 submetido a transplante renal de dador cadáver, complicado com rejeição aguda. Transitoriamente retomou técnica de substituição renal, sendo submetido a novo transplante, dador vivo, em 2006, mantendo-se desde então sob imunosupressão e com enxerto funcionante. Durante a puberdade foi verificada um défice do crescimento marcado, apresentando uma baixa estatura, em média com menos cerca de 15cm do que os seus 3 irmãos. A endocrinopatia múltipla também foi uma das apresentações da doença metabólica, diagnosticando-se um hipotiroidismo e hiperparatiroidismo.

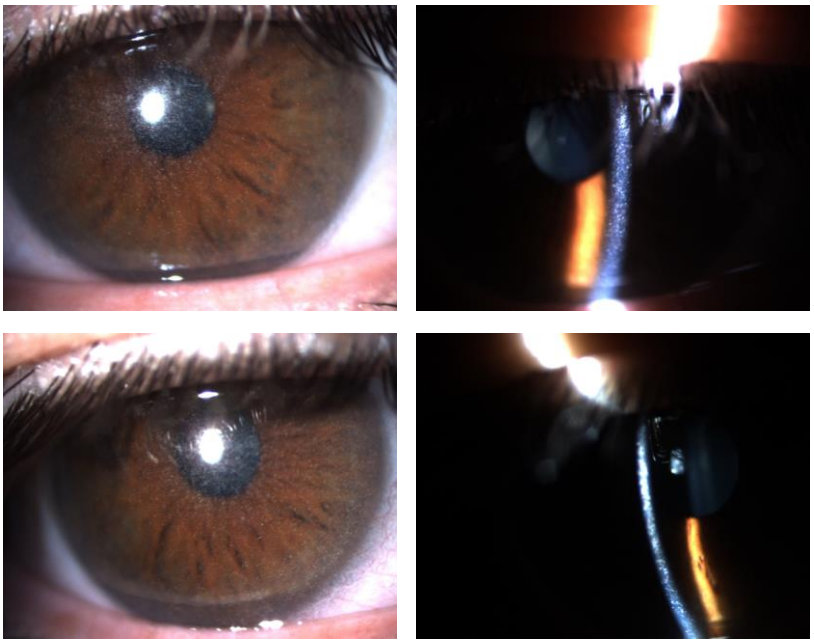

Figura 2

O diagnóstico de cistinose foi consubstanciado após referenciação à consulta de doenças metabólicas hereditárias do adulto, com uma determinação de cístina intraleucocitária de 3,6 µmol/g proteína, bem como com um estudo genético positivo. Outro motivo de referenciação à consulta foi a diminuição da acuidade visual progressiva. Após observarão oftalmológica, foi verificado depósito de cística na córnea (Figura 2) - com uma observação patognomónica.

Após discussão multidisciplinar, o doente iniciou terapêutica com cisteamina, inicialmente tópica e posteriormente sistémica, com o intuído de parar a progressão da doença. A terapêutica de deplecção de cístina apresenta uma forte influência prognóstica neste caso, dado o controlo metabólico, num doente submetido a transplante renal, com enxerto funcionante e sem outra descompensação da doençaa de base. Aos 3 meses de terapêutica o doente apresentou uma diminuição de 75% do valor de cistina intraleucocitária.

Discussão

Os dois casos clínicos traduzem a complexidade associada à maioria das doenças metabólicas hereditárias do adulto. Estas representam doenças raras, que abrangem um conjunto de patologias multisistémicas, cuja abordagem deve ser multidisciplinar e com acompanhamento em centros de referência a nível nacional. Apesar de ser uma doença rara, a Cistinose deve ser um diagnóstico a considerar perante quadros de doença renal, atraso no crescimento e alterações oftalmológicas. O tratamento cursa com um regime alimentar personalizado, com acompanhamento nutricional adequado. Por outro lado, o tratamento consiste ainda na prevenção e seguimento das manifestações secundárias, frequentemente endocrinológicas. Nos últimos anos, foi desenvolvida uma terapêutica dirigida à deplecção de cístina - cisteamina [93-95]. Esta inovação terapêutica foi fundamental para a melhoria substancial do prognóstico funcional e vital dos doentes, tendo como principal objectivo o impedimento da progressão da doença.

Conclusões

Em conclusão, dado o envolvimento sistémico da doença, bem como a diferenciação e complexidade clinica da mesma, os centros de referência devem acompanhar de forma integral e holística todos os doentes com doenças metabólicas hereditárias.

Referências Bibliográficas

1. Manz F, Gretz N. Cystinosis in the Federal Republic of Germany. Coordination and analysis of the data. J Inherit Metab Dis 1985; 8:2.
2. Meikle PJ, Hopwood JJ, Clague AE, Carey WF. Prevalence of lysosomal storage disorders. JAMA 1999; 281:249.
3. Gahl WA, Thoene JG, Schneider JA. Cystinosis. N Engl J Med 2002; 347:111.
4. Forestier L, Jean G, Attard M, et al. Molecular characterization of CTNS deletions in nephropathic cystinosis: development of a PCR-based detection assay. Am J Hum Genet 1999; 65:353.

5. Attard M, Jean G, Forestier L, et al. Severity of phenotype in cystinosis varies with mutations in the CTNS gene: predicted effect on the model of cystinosin. Hum Mol Genet 1999; 8:2507.
6. Anikster Y, Lucero C, Guo J, et al. Ocular nonnephropathic cystinosis: clinical, biochemical, and molecular correlations. Pediatr Res 2000; 47:17.
7. Thoene J, Lemons R, Anikster Y, et al. Mutations of CTNS causing intermediate cystinosis. Mol Genet Metab 1999; 67:283.
8. Markello TC, Bernardini IM, Gahl WA. Improved renal function in children with cystinosis treated with cysteamine. N Engl J Med 1993; 328:1157.
9. Kimonis VE, Troendle J, Rose SR, et al. Effects of early cysteamine therapy on thyroid function and growth in nephropathic cystinosis. J Clin Endocrinol Metab 1995; 80:3257.
10. Nesterova G, Williams C, Bernardini I, Gahl WA. Cystinosis: renal glomerular and renal tubular function in relation to compliance with cystine-depleting therapy. Pediatr Nephrol 2015; 30:945.

Back pain in cancer patients –they are not always metastasis

Dorsalgia em doente oncológico - nem sempre são metástases

João Ulrich[1], André Florindo[1], Diogo Mendes Pedro[2], André Abrunhosa-Branquinho[1], Sérgio Paulo[2], Tiago[2] Marques, Filomena Pina[1].

[1] Serviço de Radioterapia, Hospital de Santa Maria, Centro Hospitalar Universitário Lisboa Norte, [2] Serviço de Doenças Infeciosas, Hospital de Santa Maria, Centro Hospitalar Universitário Lisboa Norte

Resumo

Doente de 64 anos e género masculino, diagnosticado com adenocarcinoma da próstata, PSA inicial de 5,16ng/mL, Gleason Score de 8 (4+4), submetido a prostatectomia radical cuja anatomia patológica revelou pT3b N0 M0 com margem cirúrgica positiva (R1). No período pós-cirúrgico surge um quadro de infeção do trato urinário com isolamento de *Klebsiela pneumoniae* multirresistente tendo resolução total do quadro com antibioterapia. Após subida dos valores de PSA optou-se por iniciar tratamento de radioterapia adjuvante pélvica. Durante os tratamentos apresenta um quadro de febre de 38ºC persistente que não cede ao paracetamol. Iniciou, em ambulatório, investigação para síndrome febril indeterminado durante a qual há um agravamento da dorsalgia em intensidade e frequência com fraca resposta à medicação opioide. Faz TC toraco-abdomino-pélvica e é detetada lesão compatível com espondilodiscite. O doente foi internado no Serviço de Doenças Infeciosas tendo cumprido antibioterapia com evolução favorável.

Palavras chave: Espondilodiscite, dorsalgia, próstata, radioterapia.

Abstract

64-year-old male patient diagnosed with adenocarcinoma of the prostate, initial PSA of 5.16ng / mL, Gleason Score of 8 (4 + 4), underwent radical prostatectomy whose histology revealed pT3b N0 M0 with positive surgical margin (R1). In the post-surgical period, there was a urinary tract infection with a multiresistant *Klebsiella pneumoniae* isolate having a total resolution of symptoms after antibiotic therapy. After ascending PSA values, it was decided to start pelvic adjuvant radiotherapy. During the treatments, there is a persistent 38ºC fever resistant to paracetamol. A clinical research for undetermined febrile syndrome was started during the treatments of radiotherapy when a worsening of back pain in intensity and frequency with poor response to opioid medication emerged. The patient does a thoraco-abomino-pelvic CT-scan and a lesion compatible with spondylodiscitis is detected. The patient was then admitted to the Infectious Diseases Ward where he underwent antibiotic therapy with clear clinical improvement.

Key words: Spondylodiscitis, back pain, prostate, radiotherapy.

Introdução

A espondilodiscite corresponde a um processo infecioso que atinge o disco intervertebral e corpos vertebrais contíguos, afetando regra geral dois corpos vertebrais e o disco intervertebral adjacente. É uma doença pouco frequente e com dificuldade diagnóstica que levam a uma morbilidade elevada [1].

Em relação às manifestações clínicas, a dor na coluna, conforme a localização da infeção, é o sintoma mais frequente (97,6%), seguida pelos sintomas constitucionais (51,2%) e a febre (43,9%) [1].

A evolução insidiosa leva a um diagnóstico baseado sobretudo num elevado índice de suspeição.

Sendo o osso o principal órgão de metastização à distância do adenocarcinoma da próstata, é de esperar que a dorsalgia num doente oncológico se pudesse dever a metastização óssea.

Os autores apresentem um caso de espondilodiscite num doente de adenocarcinoma da próstata sob radioterapia em que o *timing* dos sintomas e a presença no serviço de Radioterapia diariamente contribuíram para um rápido diagnóstico em articulação com outras especialidades.

Caso Clínico

Doente de 64 anos, género masculino, natural e residente em Lisboa, casado, reformado (mecânico de automóveis/estofador). Tem como antecedentes pessoais: bronquiectasias; litíase renal; colecistectomia laparoscópica (2007); cirurgia a coluna cervical (2013); cicatriz imunitária de contato com vírus da hepatite B. Sem medicação habitual. Sem alergias medicamentosas conhecidas. Relativamente aos antecedentes familiares, refere um tio materno com adenocarcinoma da próstata diagnosticado aos 60 anos.

Doente assintomático, tendo sido detetado em exame de rotina PSA sérico elevado [PSA =5.16 ng/mL]. Diagnóstico de adenocarcinoma da próstata posteriormente confirmado por biópsia (sextante) transretal, categorizado como Gleason score de 8 (4+4) e presença de doença bilateralmente. TC tóraco-abdomino-pélvica e cintigrafia óssea sem evidência de adenopatias pélvicas nem metastização à distância, descrevendo alterações inflamatórias/degenerativa na 2ª articulação esterno costal direita e L5 S1, degenerativas. A ressonância magnética pélvica descreve lesão suspeita na zona periférica e da transição direitas (ápex, terço médio e base), não se estendendo além do ápex, mas em contacto com a cápsula numa área >3cm, compatível com invasão da mesma. Sem evidência de invasão do feixe vasculo-nervoso ou da vesicula seminal à direita. Adenopatia ilíaca interna à direita, com 7x 6mm, assim como outra obturadora interna esquerda, suspeitas.

O doente foi submetido a prostatectomia radical com linfadenectomia pélvica. A peça operatória confirmou que a lesão da próstata era um adenocarcinoma, Gleason score 8 (4+4), ocupando 35% do volume da glândula, com localização do ápex à base, em 30% à direita e em 5% à esquerda, invadia a vesicula seminal direita, os tecidos moles periprostáticos e margem direita com margem cirúrgica positiva para tumor (R1). Também apresentava linfangiose carcinomatosa e numerosas invasões perineurais. Não apresentava doença nos sete gânglios isolados na peça.

A doença foi estadiada em pT3b pN0 R1 e considerada de alto risco.

O doente apresentou como complicação pós-operatória uma infeção do trato urinário nosocomial por *Klebsiella pneumoniae,* produtora de beta-lactamases de espectro alargado (sensível a amicacina, fosfomicina e ertapenem), tratada com 4 doses de fosfomicina 3000mg. Manteve, temporariamente, algaliação em ambulatório.

A avaliação do PSA no pós-operatório foi de 0.53ng/mL, com aumento gradual nos 2 meses seguintes (0,64ng/mL - 0,75ng/mL). Por esse motivo, foi proposto para radioterapia adjuvante sobre áreas ganglionares pélvicas (46 Gy em 23 frações) e posterior sobreimpressão sobre loca cirúrgica (até 66 Gy em 33 frações), técnica de radioterapia externa conformacional 3D com 1 arco, que iniciou a 5 meses após a prostatectomia.

Ao 23º dia de tratamento com 46 Gy de dose acumulada, o doente apresentou um quadro de febre de 38ºC persistente que não cedia ao paracetamol e ibuprofeno, associada a sudorese, calafrios, a tosse seca, mialgia com maior desconforto a nível dorsal e disúria. Sem alterações ao exame objetivo, com a exceção de febre (38ºC), sudorese e desconforto à percussão da região dorsal.

O doente foi enviado para o Serviço de Urgência tendo realizado urocultura que foi negativa, sem alterações na telerradiografia torácica ou aumento dos parâmetros laboratoriais inflamatórios. Foi diagnosticado para traqueobronquite aguda e medicado com cefuroxima durante 1 semana, com melhoria das queixas respiratórias e urinárias, mas mantendo febre de 38ºC, mialgia e desconforto a nível dorsal.

O doente manteve os tratamentos de radioterapia e iniciou, em ambulatório, investigação da síndrome febril de causa indeterminada. Foram colocadas as hipóteses iniciais de mieloma múltiplo, espondilodiscite ou infeção de ponto partida indeterminado com metastastização óssea. Foram pedidos os seguintes exames: hemoculturas, painel de serologias de doenças auto-imunes e de agentes infeciosos (incluindo febre Q), ecocardiograma, TC toráco-abdmino-pélvica (TAP),ci ntigrafia óssea, eletroforese de proteínas séricas e urinárias e microglobulinas, e provas de função hepática e renal. Também realizou prova terapêutica com naproxeno (500 mg 2id) durante 3 semanas e iniciou doxiciclina (200 mg de carga seguido de 100 mg de 12 em 12 horas durante 21 dias).

As hemoculturas e as serologias para agentes infeciosos foram negativas (excetuando cicatriz imunitária para VHB). A destacar aumento do valor da gama GT e fosfatase alcalina de 132 e 203 U/L respectivamente.

Nos últimos dias de tratamento, o doente apresentou agravamento gradual da dorsalgia em intensidade e frequência com fraca resposta a medicação opioide, impossibilitando as atividades da vida diária (AVD) e sem outras alterações neurológicas associadas (negava alterações da força muscular segmentar, parestesias ou incontinência de esfíncteres). Realizou TC toraco-abdomino-pélvica, onde foi detetada lesão com epicentro no disco entre D7 e D8 com invasão do corpo vertebral de D7, compatível com espondilodiscite.

O doente foi assim observado no serviço de urgência pela Neurocirurgia, que não considerou apresentar instabilidade da coluna e foi internado no serviço de Doenças Infeciosas. Durante o internamento, e após decisão de não iniciar antibioticoterapia empírica perante estabilidade clínica, procedeu-se à avaliação microbiológica seriada, com colheita de material para

hemoculturas, urocultura e exsudado purulento no contexto de biópsia guiada por TC. Neste último foi possível isolar *Klebsiella pneumoniae* produtora de beta-lactamases de espectro alargado sensível a amicacina, fosfomicina, ertapenem e doxiciclina, tendo sido iniciado terapêutica com ertapenem 1g por dia por via endovenosa. Na RMN destaca-se: "No espaço D7-D8 observa-se erosão das plataformas vertebrais, associando-se hipersinal T2 discal e somático, com realce correspondente após administração de gadolínio, aspetos em relação com espondilodiscite.". Repetiu TC da coluna dorsal ao 18º dia de antibioticoterapia eficaz, onde se destacam os seguintes aspetos: "sobreponível a exame de RNM coluna realizado previamente, mantendo-se erosões das plataformas somáticas de D7/D8."

Atualmente, o doente mantém-se ainda internado, no 34º dia de terapêutica EV dirigida, com excelente melhoria dos parâmetros infeciosos clínicos e analíticos.

Discussão

A dorsalgia num doente com o diagnóstico de adenocarcinoma da próstata tem alta probabilidade de se dever a metastização óssea, sobretudo vertebral. Somar a esta sintomatologia um quadro de febre leva a um obrigatório alargamento do espectro de hipóteses diagnósticas como se verificou no caso apresentado [1].

A espondilodiscite é uma entidade rara, com maior prevalência em homens (2:1) entre a 4ª e 5ª década de vida, e requer terapêutica agressiva dadas as complicações e alta morbilidade [2].

O agente patogénico é transportado, via hematogénea, para as vertebras através do plexo de Batson ou por inoculação direta por procedimento invasivo. Em adultos, um pequeno êmbolo séptico pode-se alojar na região subcondral do osso no contexto de bacterémia e, após a sedimentação e proliferação do agente, provocará o enfarte do tecido ósseo e subsequente osteomielite. Posteriormente, a infeção transmite-se por continuidade através do disco e invadir a vertebra adjacente. No caso de procedimentos invasivos ou iatrogénicos o foco inicial pode ter início no disco, através das "end-arterial arcades" das regiões metafisárias adjacentes ao disco, e não da região subcondral do osso [2].

O quadro clínico é insidioso e arrastado (3 meses) em 50% dos doentes. A maioria dos doentes queixam-se de dor (90%) em topografia axial com radioculopatia; 52% apresentam febre e, raramente, apresentam calafrios. Ao exame objetivo destaca-se aumento da sensibilidade paravertebral, espasmos, limitação dos movimentos da coluna e, em alguns casos (12%), sinais de compressão medular/radicular ou meningismo, sendo sugestivo de abcesso epidural ou colapso vertebral. Na anamnese pode existir história prévia de trauma ou abuso de drogas ilícitas EV, mas em 37% dos casos a causa não é identificada. A suspeita deve ser sempre levantada quando há história prévia de procedimentos cirúrgicos/invasivos, endocardite ou infeções nosocomiais, sobretudo se foram nos últimos meses. Também a pesquisa de fatores epidemiológicos/endémicos relevantes (ex: tuberculose ou brucelose), e de antecedentes pessoais relevantes (imunossupressão) são fundamentais [2, 3, 4].

Laboratorialmente, pode-se observar o aumento dos parâmetros inflamatórios, com leucocitose discreta em 35% e, mais frequente, aumento da velocidade de sedimentação. A colheita

de sangue, urina e exsudado das áreas supuradas detetadas para avaliação microbiológica é obrigatória. Em metade dos casos as hemoculturas são positivas. Os exames de imagens como tomografia computorizada (TC) podem ser a primeira avaliação das alterações suspeitas de espondilodiscite, da instabilidade da coluna e suspeita de compressão medular. Saliente-se que telerradiografia não é ideal no início da sintomatologia, uma vez que há discrepância temporal de semanas entre o aparecimento de sintomas e a semiologia radiológica. A cintigrafia óssea (com tecnécio-99m ou com marcação de leucócitos) tem alta sensibilidade para a deteção de focos suspeitos nos primeiros dias, apesar da baixa especificidade e resolução de imagem. A ressonância magnética é o *gold-standard* na avaliação destes doentes, com sensibilidade de 96%, especificidade de 92%. Quando exequível, a biópsia sob orientação de TC é segura e precisa, com uma taxa de assertividade diagnóstica e do agente em questão, variando de 70% a 100%, enquanto que as biópsias abertas são diagnósticas em mais de 80% dos casos. Os agentes mais frequentes são *Staphylococcus aureus* e *Streptococcus spp* [1, 2].

O tratamento da espondilodiscite tem que cumprir os seguintes objetivos: aliviar a dor, prevenir ou reverter os défices neurológicos, erradicar a infeção, prevenir a recaída e estabelecer a estabilidade da coluna vertebral. A abordagem ao tratamento pode ser conservadora ou cirúrgica [2].

A abordagem conservadora deve englobar: (a) estabelecimento de um diagnóstico microbiológico preciso; (b) tratamento com antibioterapia adequada; (c) imobilização da coluna vertebral; (d) monitorização cuidadosa de evidências clínicas e radiográficas de instabilidade da coluna vertebral e progressão da infeção ou deterioração neurológica. O início da antibioticoterapia deverá ser iniciada após identificação do agente etiológico, exceto em situações particulares (ex: instabilidade hemodinâmica ou compromisso neurológico grave). A duração não é consensual, mas parece que pelo menos 6 semanas será eficaz na maioria dos casos, mas sempre em alerta para fatores de risco para recidiva (ex.: idade avançada, doença avançada ou infeção por MRSA). [2,5] Os objetivos do tratamento cirúrgico são de ação imediata e correspondem a: (a) desbridamento e remoção total do tecido infetado com avaliação microbiológica que permita otimizar antibioterapia, se, entretanto, iniciada; (b) descompressão; (c) efetuar alinhamento da coluna vertebral; ou (d) correção de instabilidade da coluna vertebral. A avaliação microbiológica com subsequente ajuste da antibioterapia, caso seja positiva, é obrigatória. O tempo médio de internamento varia entre 30 e 57 dias, com uma mortalidade calculada entre 2 e 17% [6, 7, 8, 9]. Vários autores sugerem que se o tempo até ao diagnóstico for superior a 60 dias, o prognóstico é pior, e ocorre menor recuperação dos défices neurológicos [10, 11], apesar de a média de tempo de evolução até diagnóstico ser de 2 a 6 meses [12].

Conclusão

Em conclusão, a espondilodiscite é uma entidade rara e de evolução insidiosa, mas cujo diagnóstico diferencial deve ser contemplado, principalmente, caso haja história prévia de infeção por procedimento invasivo ou fatores de risco associados. O diagnóstico deve ser colocado como hipótese no doente oncológico com quadro de queixas compatíveis e requer exames laboratoriais e imagiológicos para a melhor orientação terapêutica.

Referências bibliográficas

1. Grados, F., Lescure, F., Senneville, E., Flipo, R., Schmit, J., & Fardellone, P. Suggestions for managing pyogenic (non-tuberculous) discitis in adults. *Joint Bone Spine*. 2007; *74*(2), 133-139.
2. Skaf, G., Domloj, N., Fehlings, M., et al. Pyogenic spondylodiscitis: An overview. *Journal Of Infection And Public Health*. 2010; *3*(1), 5-16.
3. Sans, N., Faruch, M., Lapègue, F., Ponsot, A., Chiavassa, H., &Railhac, J. Infections of the spinal column – Spondylodiscitis. *Diagnostic And Interventional Imaging*. 2012; *93*(6), 520-529.
4. Costa, Jorge, Andrade, Noronha de, Arcangelo, Joana, Pedrosa, Carlos, & Figueira, Paulo. Espondilodiscite piogénica em adultos: diagnóstico e tratamento. *Revista Portuguesa de Ortopedia e Traumatologia*. 2015; *23*(3), 225-235.
5. Herren, C., Jung, N., Pishnamaz, M., Breuninger, M., Siewe, J., & Sobottke, R. Spondylodiscitis: Diagnosis and Treatment Options. *Deutsches Aerzteblat.* 2017; 114, 875-882.
6. Cottle, L., & Riordan, T. Infectious spondylodiscitis. *Journal Of Infection*. 2008; 56(6), 401-412.
7. Hopkinson, N., Stevenson, J. & Benjamin, S. A case ascertainment study of septic discitis: clinical, microbiological and radiological features. *Quarterly Journal of Medicine.* 2001; 94, 465-470.
8. Acosta, F., Galvez, L., Aryan, H. & Ames, C. Recent Advances: Infections of the Spine. *Current Infectious Disease Reports*. 2006; 8, 390-393.
9. Butler, J., Shelly, M., Timlin, M., Powderly, W., & O'Byrne, J. Nontuberculous Pyogenic Spinal Infection in Adults. *Spine*. 2006; 31(23), 2695-2700.
10. [10] Sobottke, R., Seifert, H., Fätkenheuer, G., et al. Current Diagnosis and Treatment of Spondylodiscitis. *Deutsches Ärzteblatt International*. 2008; 105 (10), 181-187.
11. Mann, S., Shütze, M. & J. Piek. Nonspecific pyogenic spondylodiscitis: clinical manifestations, surgical treatment, and outcome in 24 patients. *Neurosurgical* Focus. 2004; 17 (6), 1-7.
12. Zarghooni, K., Röllinghoff, M., Sobottke, R., & Eysel, P. (2011). Treatment of spondylodiscitis. *International Orthopaedics*. 2011; 36(2), 405-411.

Mania Após Um Acidente Vascular Cerebral - Uma Complicação Rara A Não Esquecer

Post Stroke Mania - A Rare Complication Not To Forget

Rodrigo Saraiva, Filipa Maria Proença, Maria João Gonçalves, Carolina Sereijo, Rita Barandas, Ricardo Coentre

Serviço de Psiquiatria, Hospital de Santa Maria, Centro Hospitalar Universitário Lisboa Norte

Resumo

Um episódio maníaco pode ser provocado por diversas doenças orgânicas. Os acidentes vasculares cerebrais (AVC) estão muitas vezes associados a sintomatologia psiquiátrica, principalmente depressiva, e mais raramente maníaca. Descrevemos o caso de um homem de 67 anos sem antecedentes psiquiátricos pessoais ou familiares, com história de hipertensão arterial, dislipidémia e diabetes, que aos 64 anos teve um AVC isquémico no território vascular da artéria cerebral média bilateralmente. Cerca de vinte dias após este AVC desenvolveu um episódio maníaco que motivou internamento psiquiátrico. Nos anos seguintes, esteve estável sob terapêutica de manutenção com valproato de sódio 1000 mg/dia, sendo totalmente independente nas atividades de vida diárias. Três anos depois deste episódio desenvolveu novo episódio maníaco, com necessidade de novo internamento em psiquiatria. Com este caso pretende-se sublinhar, que apesar de rara, o diagnóstico de mania após AVC não deve ser esquecido.

Palavras chave: Mania; Mania Secundária; Mania Vascular; Doença Bipolar; Acidente Vascular Cerebral.

Abstract

Various organic diseases can trigger a manic episode. Stroke is often associated with psychiatric symptoms, particularly depressive, and more rarely manic. We describe a 67-year-old man with no personal or family history of psychiatric illness, with hypertension, dyslipidemia and diabetes, who at age 64 had a bilateral ischemic stroke in the middle cerebral artery territory. About twenty days after this stroke he developed a manic episode that motivated hospitalization in a psychiatric ward. In the following years, he was clinically stable under 1000 mg sodium valproate per day, being totally independent in the activities of daily living. Three years after this episode he developed a new manic episode, with another hospitalization in a psychiatric ward. With this case we intend to emphasize that, although rare, the diagnosis of mania after stroke should not be forgotten.

Key Words: Mania; Secondary Mania; Vascular Mania; Bipolar Disorder; Stroke.

Introduction

Mania is a syndrome characterized by prominent and persistently elevated, expansive or irritable mood. At the same time, other symptoms may be present, such as increased energy, increased goal-directed activities, excessive talkativeness, flight of ideas, increased self-esteem and grandiosity, decreased need for sleep, psychomotor agitation, distractibility and disinhibition. Involvement in activities with potential for pejorative consequences such as excessive spending may also occur [1].

Bipolar disorder (BP) is a disease of high morbidity and mortality that affects 1.5 to 3% [2] of the general population, it alternates between mania and euthymia and depressive episodes often happen as well [3].

Secondary mania was defined as the presence of a manic syndrome, caused by an organic systemic or neurological disease, in the absence of personal or family history of affective illness [4]. Thus, a manic episode may occur secondary to endocrine diseases, infections and a wide range of neurological disorders, such as cerebrovascular diseases (CVD) [1,3].

A stroke contributes to early mortality and important physical and mental morbidity. Neuropsychiatric conditions are some of the major complications of stroke and remain underdiagnosed [5]. Stroke is associated with psychiatric symptomatology and the main psychiatric complications following stroke are depression (35%), anxiety (25%) and apathy (20%). Manic episodes have also been reported, but they are uncommon (<2%) [5,6].

The specific association between CVD and mania was defined in two terms: "post-stroke mania" and "vascular mania" (table 1) [4,7].

Table 1 - "Vascular Mania" criteria proposed by Steffans D. and Krishnan K. and reviewed by Wijeratne C. and Malhi G. S. [4]

Adapted from reference [4]

Criteria	Steffans e Krishnan (1998)	Wijeratne e Malhi (2007)
Essential/Required	Hypomanic or manic episode	DSM criteria for manic episode
	Clinical evidence of stroke; **OR** Neuroimaging findings compatible with cerebral ischemia **OR** Neuropsychological status compromise (executive functions, memory, processing speed);	Older than 50 when first manic episode occurred
		Clinical evidence of stroke; **OR** At least two systemic diseases which are vascular risk factors (hypercholesterolemia, coronary disease, hypertension, diabetes mellitus)
Supportive	Beginning or change of psychiatric illness older than 50;	Neuroimaging changes greater than predicted for age
	No family history of psychiatric illness	Neuropsychological changes greater than predicted for age
	Disability in daily life activities	

A systematic review published in 2010 by Santos *et al* confirms the rarity of mania after stroke, having identified only 49 cases of manic or hypomanic episodes secondary to stroke in the literature until 2010. The same group identified only 3 cases of mania in 188 consecutively evaluated stroke patients [8]. Dunne *et al* diagnosed 3 cases of mania after stroke in 661 patients [9] and similarly Stakstein *et al* identified only 3 cases in 700 stroke patients [10].

We report the case of a patient who, in addition to post stroke manic episode, presents a pattern of recurrence that isn´t frequently found in literature. [8] An informed consent was obtained from the patient to use his clinical information in this article.

Case Report

We report the case of a 67-year-old man, retired (ex entrepreneur), with completed 12th grade, married, living alone, totally autonomous in daily life activities and in his patrimony management.

He has medical history of dyslipidemia, hypertension, diabetes mellitus (with 30 years of evolution and treated with insulin for the last ten years with micro and macro vascular repercussions), diabetic retinopathy, atherosclerotic carotid disease and an interhemispheric meningioma known for the last ten years. For these conditions he is medicated with 50 mg losartan and 4 mg pitavastatin per day and insulin therapy. The patient is an active smoker (26 Pack Years) and has no history of other substances use. He has no personal or family history of psychiatric illness.

When he was 57 years old, he was hospitalized after a right middle cerebral artery ischemic stroke. After this hospitalization he remained with grade 4 left paresis of upper limb and facial asymmetry. This stroke had no impact on his subsequent daily functioning.

Six years later he was hospitalized again, in an internal medicine ward, after sudden onset of right hemiparesis and aphasia. He was submitted to cranial computerized tomography (CT) scan, which showed bilateral cortical and subcortical hypodense lesions. The most extensive lesion was located in the upper and medial frontal gyrus of the right hemisphere. On the left hemisphere, the lesions included the medial and pre-central frontal gyrus (fig. 1). He also underwent vascular ultrasound study that showed significant occlusion of the right internal carotid and left vertebral arteries. He was submitted to treatment with fibrinolysis and was discharged maintaining instability of gait and difficulty in fine coordination of right limbs. After this episode he initiated dual anti aggregation therapy with 75 mg clopidogrel and 150 mg acetylsalicylic acid per day.

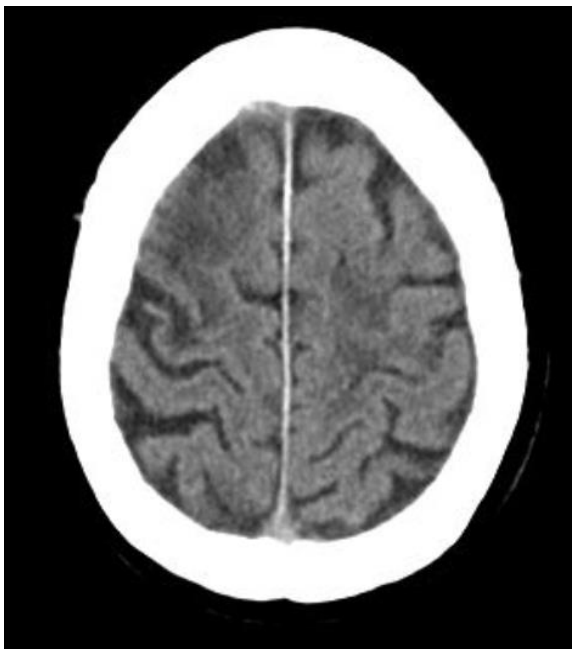

Fig. 1 - Cranial CT Scan - *Day two of internal medicine hospitalization motivated by bilateral ischemic stroke*

After discharge, about twenty days after the stroke, according to relatives, he started to show an irritable mood, emotional lability, aggressiveness, impulsivity, excessive spending and decreased need for sleep, with significant negative impact on the daily functioning of the patient. The clinical picture presented evolved and worsened for about four weeks and due to its severity the patient was hospitalized in a psychiatric ward. There he underwent cranial magnetic resonance imaging (MRI) scan, which showed cortical and subcortical bilateral stroke lesions in the medial and pre-central frontal gyrus (fig. 2). During the hospitalization he also underwent a neuropsychological evaluation that showed slight changes in sustained attention, in graph-motor initiative, in planning capacities, in sequence of action and in self-monitoring of performance. He was medicated with 1000 mg valproate sodium, 2 mg risperidone mg and 100 mg quetiapine per day, with subsequent psychiatric and neurologic follow-up as an outpatient.

In the following years, normal daily functioning and improvement of neuropsychological changes were observed. The patient had complete autonomy and remained clinically stable under psychiatric pharmacological therapy, which was reduced to 1000 mg valproate sodium per day, maintaining the medications for the non-psychiatric diseases.

Three years after the psychiatric hospitalization described, after a trip that the patient describes as "*of high emotionality and nostalgia*", he reports mood elation, increased energy, racing thoughts, increased goal-directed activities and decreased need for sleep. Relatives also reported excessive spending on unusual purchases and that the patient attempted indebtedness to achieve them.

Two weeks after the onset of this symptoms, he was brought to the emergency department (ER), where it was clinically evident psychomotor agitation, euphoric mood, social and sexual disinhibition, excessive talkativeness, race of thoughts, increased energy, increased self-esteem, delirious self-relation and delirious ideas of grandiosity. The patient lacked insight into his disease or need for therapeutics. In the ER, the patient underwent an analytical evaluation, of which we stand out that he had a valproate sodium blood level of 59.7 µg/dL (therapeutic level 50-100 µg/dL) and that the urinary drug screening (cannabinoids, opioids, cocaine and amphetamines) was negative. He also performed an electrocardiogram, a chest roenteogram and a cranial CT, that didn´t show any acute changes. Due to the severity of the clinical situation he was hospitalized again in a psychiatry ward.

In the first day as inpatient, when rated on Young Mania Rating Scale (YMRS), he scored 36 of a total score of 60 and he scored 22 of a total score of 30 in Montreal Cognitive Assessment (MOCA) test with alteration of attention, delayed evocation, verbal fluency, and language.

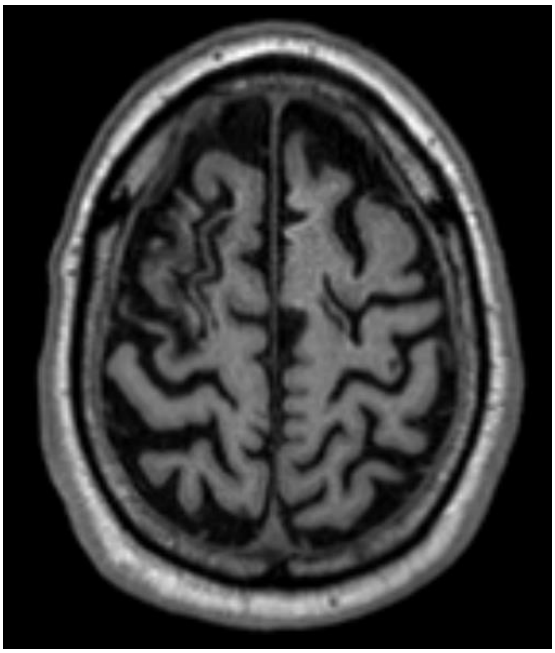

Fig. 2 - Cranial MRI Scan (T1) *- First psychiatric hospitalization, two months after bilateral stroke*

The patient underwent a complete analytical evaluation in which renal, thyroid, hepatic and ionic changes were excluded. HIV, syphilis and hepatitis B and C screening was negative. He also underwent cranial MRI scan, which did not show significant changes when compared with the cranial MRI scan performed three years before during the first psychiatric hospitalization.

He was treated with 1500 mg valproate sodium, 3 mg lorazepam and 10 mg haloperidol per day. During the first days of hospitalization he developed extrapyramidal signs (bradykinesia, peripheral tremor and superior limbs rigidity), which disappeared after switch from haloperidol to aripiprazol titrated to 20 mg per day. There was a significant clinical improvement after twenty five days, as the patient progressively presented remission of symptoms with improved interpersonal contact, attitude and behavior, progressive speech normalization, stabilization of mood and affections, decrease of dynamism and subsequent remission of delusional ideas and regularization of the sleep-wake cycle.

At the time of discharge the patient scored 4 out of 60 in the YMRS and 26/30 in the MOCA test. He kept his follow up as outpatient medicated with 20 mg aripiprazole and 1500 mg valproate sodium per day, and maintained his previous therapeutics for non psychiatric diseases.

Discussion

We report the case of a 67-year-old man with no personal or family history of psychiatric illness, with several vascular risk factors (dyslipidemia, hypertension, diabetes mellitus) and with carotid atherosclerotic disease, who at age 64 had a bilateral stroke in the middle cerebral artery territory. About twenty days after this stroke he developed a manic episode that motivated hospitalization in a psychiatric ward. He was medicated with 1000 mg sodium valproate, 2mg risperidone and 100 mg quetiapine per day with improvement. In the following years he was clinically stable under maintenance therapy of 1000 mg sodium valproate per day, being totally independent in the daily life activities. Three years later he developed a new manic episode, with another hospitalization in a psychiatric ward. Initially he presented a 36/60 score at YMRS (being 20 the cut off usually used to diagnose mania [11]). The patient was medicated with a mood stabilizer and an antipsychotic with clinical improvement expressed in the drop of the YMRS score from 36/60 to 4/60.

Both the symptomology that motivated the first psychiatric hospitalization and the one that was in the origin of the most recent meet the criteria for manic episode defined in the DSM-5, and also meet the criteria for bipolar disorder secondary to another medical condition [1]. On the other hand the first manic episode also fulfills the criteria for "vascular mania" (table 1) [4,7].

In the systematic review by Santos *et al* the "typical patient" with post stroke mania was characterized as a man, with no personal or family history of psychiatric illness, with at least one vascular risk factor, who develops a manic or hypomanic episode less than two years after a right hemisphere stroke [8]. The characteristics of the case here presented are consistent with this description.

Regarding the localization of the stroke, although the neural circuits involved in affective diseases are complex, the dorsolateral prefrontal circuit and the anterior cingulate cortex seem to be essential in mood regulation [2]. Several studies suggest that the frontal lobe (including the

orbitofrontal cortex), the temporal lobe, the basal ganglia, and the thalamus are the major areas involved in post stroke mania. [8,12] It is hypothesized that dysfunction of these fronto-limbic circuits secondary to ischemic injuries causes dysfunction in mood regulation that may culminate in a manic episode. [12]

Firstly, it was described that the occurrence of mania after a stroke was typical of right hemisphere strokes, [4,12] and most of the cases reported in literature are secondary to right hemisphere lesions [8]. One possible explanation for this finding is that ischemia lesions in certain areas of the right hemisphere interrupt interhemispheric inhibition, which may lead to an increase in left hemisphere activation causing a manic episode [14]. However, there are also case reports of mania following left hemisphere strokes [4,12,13]. Currently it is accepted that although mania after a stroke occurs more frequently after right hemisphere lesions, it may also occur after left hemisphere lesions [3,4,12].

The cranial CT scan, performed during the internal medicine hospitalization motivated by the bilateral stroke (fig. 1), and the cranial MRI scan (fig. 2), that the patient underwent two months later in the first psychiatric hospitalization, showed bi-hemispheric lesions in the frontal lobe, which coincides with the most frequently described areas in post stroke mania.

Although reports of disturbed mood episodes recurrence after post stroke mania are rarely found in literature, [8] more than 90% of patients with a manic episode (regardless of being secondary) develop another acute affective episode [1]. On the other hand, affective episodes, namely manic episodes, which occur in association with permanent brain injuries, may be episodic or recurrent, [1] presenting the characteristic cyclicity of a primary/functional bipolar disorder. This seems to occur in our case since the patient developed another manic episode three years after the first one.

There are several manic triggers of bipolar disorder like circadian rhythm disturbance, changes in medication (including introduction of antidepressants or withdrawal of mood stabilizing therapy), expressed emotion of caregivers, and personal achievement situations or events - Goal-Attainment Life Events (GOAL) - like job promotions or recent relationships. [15,16] Before the second manic episode the patient seemed to be taking his psychiatric drugs correctly and there wasn’t any recent therapeutic adjustment. We hypothesize that the patient's supra referred trip, in which he visited his childhood hometown, may have functioned as a GOAL (since during hospitalization the patient mentioned several times how important and thrilling the travel was for him) precipitating a manic episode. However, the biological mechanisms and triggers that cause a hypomanic or a manic episode in bipolar disorder are often undiscovered [15].

Conclusion

This case shows that it is possible for an organic disease to cause a syndrome with a phenotype and an evolution overlapping a primary psychiatric illness, in this case bipolar disorder, even in individuals without history of psychiatric disorders. We also intended to highlight that when an affective episode arises in the context of a disorder that causes structural changes in the brain, as in the case of stroke, one must be aware of the possibility of recurrence of new acute affective episodes.

References

1. American Psychiatric Association "*Diagnostic and statistical manual of mental disorders* (5th ed). Arlington, VA: American Psychiatric Association, pp 145-156; 171-173;
2. Antelmi E, Fabbri M, Cretella L et al. “Late Onset Bipolar Disorder Due to a Lacunar State.” Behavioural Neurology, vol. 2014, 2014, pp. 1–5.
3. Taylor B, Prager L, Quijije et al. “Case 21-2018: A 61-Year-Old Man with Grandiosity, Impulsivity, and Decreased Sleep.” New England Journal of Medicine, vol. 379, no. 2, Dec. 2018, pp. 182–189
4. Wijeratne C and Malhi G. “Vascular Mania: an Old Concept in Danger of Sclerosing? A Clinical Overview.” Acta Psychiatrica Scandinavica, vol. 116, no. s434, 2007, pp. 35–40.
5. Tan E, Aziz N and Ahmad “Neuropsychiatric Manifestation after a Stroke: Newly Developed Symptoms or Side-Effect of Drug?” Case Reports, vol. 2012, no. aug14 2, 2012
6. Hackett M, Köller S, O´Brien, et al. “Neuropsychiatric Outcomes after Stroke.” The Lancet Neurology, vol. 13, no. 12, 2014, p. 1168
7. Steffans D, Krishnan K. "Structural neuroimaging and mood disorders. Recent findings, implications for classification, and future directions." Biol Psychiatry 1998;43:705–712
8. Santos C, Caeiro L, Ferro J, *et al.* “Mania and Stroke: A Systematic Review.” Cerebrovascular Diseases, vol. 32, no. 1, 2011, pp. 11–21
9. Dunne J, Leedman P, Edis R. *et al.* “Inobvious Stroke: A Cause of Delirium and Dementia.” Australian and New Zealand Journal of Medicine, vol. 16, no. 6, 1986, pp. 771–778.
10. Starkstein S, Boston J, Robinson R. *et al.* “Mechanisms of Mania after Brain Injury.” The Journal of Nervous and Mental Disease, vol. 176, no. 2, 1988, pp. 87–10
11. Lukasiewicz M, Gerard S, Besnard A. *et al*. "Young Mania Rating Scale: How to interpret the numbers? Determination of a severity threshold and of the minimal clinically significant difference in the EMBLEM cohort". International Journal of Methods in Psychiatric Research, vol. 22, no. 2, 2013, pp. 46-58.
12. Yeh Y and Peng G “Post-Stroke Mania Precipitated by Withdrawal of Antidepressant in an Elderly Patient with Chronic Major Depression.” General Hospital Psychiatry, vol. 33, no. 3, 2011
13. Nagaratnam N, Wong K and Patel I “Secondary Mania of Vascular Origin in Elderly Patients: A Report of Two Clinical Cases.” Archives of Gerontology and Geriatrics, vol. 43, no. 2, 2006, pp. 223–232
14. Koreki A, Takahata K, Tabuchi H *et al*. “Increased Left Anterior Insular and Inferior Prefrontal Activity in Post-Stroke Mania.” BMC Neurology, vol. 12, no. 1, June 2012, 12:68
15. Proudfoo J, Doran J, Manicavasagar V *et al*. “The Precipitants of Manic/Hypomanic Episodes in the Context of Bipolar Disorder: A Review.” Journal of Affective Disorders, vol. 133, no. 3, 2011, pp. 381–387
16. Johnson S, Cueller A, Ruggero C, *et al*. “Life Events as Predictors of Mania and Depression in Bipolar I Disorder.” Journal of Abnormal Psychology, vol. 117, no. 2, 2008, pp. 268–27

Imunoactivação associada à infecção não controlada pelo vírus da imunodeficiência humana – a propósito de um caso clínico

Uncontrolled human immunodeficiency virus infection associated immune activation – a case report

Inês Leonor Leitão[1], Antónia Gomes[2], Tiago Marques[2], Carla Mimoso Santos[3], Luís Caldeira[4]

Serviço de Doenças Infeciosas, Hospital de Santa Maria, Centro Hospitalar Universitário Lisboa Norte

Resumo

A infecção pelo vírus da imunodeficiência humana (VIH) e a sua apresentação tardia, assim como os fenómenos de imunoactivação associados, constituem um desafio de abordagem diagnóstica e terapêutica. Apresenta-se o caso clínico de um homem de 36 anos, melanodérmico, natural de Angola, com diagnóstico inaugural de infecção por VIH em estadio avançado e evidência de miocardiopatia inflamatória e lesão renal aguda à admissão. Após extensa investigação diagnóstica em internamento prolongado com várias complicações associaram-se os diagnósticos de crioglobulinemia tipo III com síndrome pulmão-rim, toxoplasmose cerebral e miocárdica e reactivação de infecção por CMV, para além de tromboembolismo pulmonar segmentar e endocardite mitral concomitante com bacteriemia por *Pseudomonas aeruginosa*. A coexistência de patologia oportunista e imunomediada na evolução clínica do doente evidencia a complexidade da gestão das complicações associadas directa ou indirectamente à infecção por VIH e a importância de um acompanhamento atento e de um elevado índice de suspeição.

Palavras-chave: VIH, imunossupressão, imunoactivação, inflamação, infecção oportunista, patologia autoimune.

Abstract

Human immunodeficiency virus (HIV) infection in its late presentation stages, like the immune activation mechanisms associated with it, present a unique challenge in terms of diagnosis and treatment. We discuss the clinical case of a 36-year-old black male patient from Angola recently diagnosed with a late presentation of HIV infection and presenting with signs of inflammatory cardiomyopathy and acute kidney injury. After extensive investigation he was also diagnosed with type III cryoglobulinemia with pulmonary-renal syndrome, reactivation of CMV infection and myocardial and cerebral toxoplasmosis, as well as nosocomial mitral valve endocarditis. The combination of opportunistic disease and autoimmune manifestations in the same patient explain the variety of complications associated directly or indirectly to HIV infection and the importance of keeping a keen eye during patient follow-up in the ward and outpatient clinic.

Keywords: HIV, immunosupression, inflammation, oportunistic infeccion, autoimmune disease

Introdução

A infecção pelo vírus da imunodeficiência humana (VIH) continua a oferecer importantes desafios no que concerne à gestão do próprio agente e das complicações associadas à infecção, mesmo após o advento de múltiplos esquemas de terapêutica antirretroviral altamente eficazes.

Segundo dados de 2016 do *European Centre for Disease Control and Prevention* (ECDC), 51% dos doentes com diagnóstico de infecção por VIH na região europeia definida pela Organização Mundial da Saúde são *late presenters* (com contagens de linfócitos T CD4 inferiores a 350 células por mm^3 à data do diagnóstico), incluindo 30% com infecção em estadio avançado (contagens de linfócitos T CD4 inferiores a 200 células por mm^3) [1]. Tal facto condiciona e justifica a necessidade de um elevado índice de suspeição e um rastreio activo de patologia oportunista na abordagem destes doentes e, consequentemente, a documentação de uma elevada prevalência deste tipo de infecções.

Paralelamente, fenómenos associados à desregulação e activação imunes já estudados neste contexto condicionam inúmeras complicações, em especial nos doentes com diagnóstico em fase tardia e sem supressão virológica [2].

Assim se justifica que a abordagem de doentes com diagnóstico de infecção por VIH em estadio avançado implique um vasto conhecimento não só sobre a própria doença, mas também sobre as múltiplas complicações com diagnóstico diferencial extenso incluindo patologia infecciosa e não infecciosa que lhe estão associadas, das quais o caso clínico apresentado é ilustrativo.

Caso Clínico

Apresenta-se o caso de um doente do género masculino, 36 anos, melanodérmico, autónomo, natural de Angola, a residir em Portugal há cerca de 6 meses. Da história médica prévia salienta-se diagnóstico recente de infecção por VIH tipo 1 em contexto de episódio de urgência por hematúria, não encaminhado para consulta de Imunodepressão por ter regressado a Angola.

É avaliado no serviço de urgência por quadro consumptivo com cerca de 3 a 4 meses de evolução caracterizado por astenia, anorexia, perda ponderal não quantificada, sem outras queixas ou clínica específica de órgão ou sistema. Documentou-se exame objectivo sem alterações de relevo.

Analiticamente, a destacar anemia com Hb 9,2g/dL, discreta trombocitopenia de 112.000/uL, lesão renal aguda AKIN 3 com ureia 120mg/dL e creatinina 3,32mg/dL, elevação dos biomarcadores de necrose miocárdica com creatinina quinase 317mg/dL e troponina T 2.509ug/mL, exame sumário de urina com hematoproteinúria ligeira, sem outras alterações. Electrocardiograma em ritmo sinusal com frequência de 78 batimentos/minuto, supra-desnivelamento do segmento ST V2-4 e inversão das ondas T V2-6, compatível com padrão de *Brugada* tipo 2. Radiografia de tórax, ecocardiograma transtorácico sumário e ecografia renal sem alterações de relevo. Neste contexto o doente é admitido na Unidade de Internamento do Serviço de Doenças Infecciosas para estudo complementar.

Do estudo complementar dirigido ao estadiamento da infecção por VIH-1, rastreio de patologia oportunista e definição da etiologia de lesão renal aguda e cardiopatia, salienta-se:

- Linfócitos T CD4+ 76células/uL (4,1%), ARN-VIH1 1.145.057cp/mL (6,06log), subtipo F, genotipagem com mutação E138A (provável resistência a etravirina);

- Serologia *Toxoplasma* spp. com IgG positiva com título alto/IgM negativa (Ag *Criptococcus* spp. negativo, CMV IgG positiva/IgM negativa, EBV anti-VCA IgG positiva/anti-VCA IgM e EBNA negativos, restantes serologias negativas, nomeadamente VHB e VHC); quantificação da carga viral de VHC, CMV e EBV negativas; IGRA indeterminado;

- Painel de autoimunidade com ANA positivos (1/60, padrão fino granular), Ac anti-MBG positivo, restante perfil negativo; presença de crioglobulinas mistas policlonais; consumo de complemento – C3 57mg/dL, C4 12mg/dL, CH50 32U/mL; imunocomplexos circulantes negativos; doseamento de imunoglobulinas normal; imunofixação sérica negativa; TASO normal (65UI/mL);

- TC crânioencefálica com evidência de lesões frontoparietais e dos núcleos da base com captação de contraste em anel periférico – achados a favor de toxoplasmose *versus* linfoma – com sinais ligeiros de hipertensão intracraniana;

- TC de corpo com evidência de derrame pleural bilateral ligeiro a moderado com atelectasia, focos de densificação em vidro despolido do parênquima à direita, espessamento dos septos interlobulares, sem outras alterações de relevo.

O doente iniciou terapêutica para toxoplasmose cerebral provável em contexto de imunodepressão severa com pirimetamina e clindamicina dada disfunção renal. Manteve-se estudo complementar de lesão renal aguda com suspeita de glomerulopatia associada ao VIH *versus* outra etiologia infecciosa ou não infecciosa e de cardiopatia também com a hipótese de miocardiopatia associada ao VIH *versus* infiltrativa por *Toxoplasma* spp.

Ao longo da evolução clínica durante o internamento verificou-se agravamento da anemia e trombocitopenia com pancitopenia e necessidade de suporte transfusional, bem como agravamento da disfunção renal com acidemia metabólica e hipercaliemia, estabilizado sob terapêutica médica, sem necessidade de indução dialítica. No decurso deste quadro, de salientar agudização respiratória de novo caracterizada por dispneia, polipneia, tosse seca e hipoxemia flutuante coincidente com descida de hemoglobina até um mínimo de 4,7g/dL, com radiografia de tórax a demonstrar infiltrado algodonoso extenso bilateralmente. TC de tórax com evidência de derrame pleural bilateral, infiltrados alveolares extensos e pequeno êmbolo em ramo segmentar, sem melhoria clínica significativa após início de anticoagulação.

Neste contexto, foram colocadas as hipóteses diagnósticas de insuficiência cardíaca descompensada/síndrome cardiorrenal com sobrecarga de volume associada em contexto de miocardiopatia em estudo; pneumonia intersticial bilateral por *Pneumocystis jirovecii*; tuberculose e hemorragia alveolar em contexto de síndrome pulmão-rim. Dada a gravidade do quadro e instabilidade clínica procedeu-se a prova terapêutica com antibacilares de primeira linha, atovaquona e corticoterapia (pulsos de metilprednisolona endovenosa e posteriormente prednisolona oral), associando-se terapêutica antirretroviral com abacavir/lamivudina e raltegravir perante infecção por VIH-1 em estadio C3 do CDC (*Centers for Disease Control and Prevention*).

Realizou broncofibroscopia sem intercorrências – exame directo, cultural bacteriológico e cultural para micobactérias negativos, cultural micológico com isolamento de *Candida albicans* interpretada como colonização, citologia sem alterações de relevo, sem hemossiderófagos,

pesquisa de *P. jirovecii* por biologia molecular negativa, pesquisa de *Mycobacterium tuberculosis* por biologia molecular negativa, pesquisa de células neoplásicas negativa.

Foi também efectuada punção lombar, inicialmente não realizada por sinais de hipertensão intracraniana – exame citoquímico sem alterações de relevo, exame directo, cultural bacteriológico, micológico e para micobactérias negativos, pesquisa de células neoplásicas negativa, pesquisa de vírus neurotrópicos e *Toxoplasma* spp. por biologia molecular enviadas para o INSA também negativas, no entanto esta pesquisa foi efectuada tardiamente e após início de terapêutica anti-*Toxoplasma* dada ausência de condições para realização do exame previamente.

Como complemento do estudo foi ainda solicitada RM crânioencefálica que confirmou lesões compatíveis com toxoplasmose, com melhoria sob terapêutica; e RM cardíaca, inconclusiva por fraca colaboração do doente e impossibilidade de injecção de contraste paramagnético dada lesão renal importante. Ecocardiograma transtorácico com descrição de ventrículo esquerdo dilatado, com hipocinésia generalizada e compromisso grave de função sistólica global (fracção de ejecção do ventrículo esquerdo de 19%); imagens sugestivas de vegetação em ambos os folhetos da válvula mitral.

Verificou-se rápida melhoria do quadro clínico após introdução de corticoterapia e normalização dos valores de complementemia – C3 108mg/dL, C4 9mg/dL, CH50 44.4U/mL, dados que associados aos resultados do painel de autoimunidade foram admitidos como a favor de etiologia autoimune – provável crioglobulinemia mista policlonal (tipo III) com síndrome pulmão-rim. Foi suspensa terapêutica antituberculosa e para pneumonia por *P. jirovecii* em dose terapêutica após resultado de broncofibroscopia. O quadro intercorrente de endocardite foi admitido em possível contexto de bacteriemia por *Pseudomonas aeruginosa versus* etiologia não infecciosa, tendo o doente efectuado antibioterapia dirigida adequada com boa resposta.

A biópsia renal realizada após estabilização inicial revelou aspectos compatíveis com a clínica e a hipótese de vasculite – glomeruloesclerose segmentar e focal, infiltrado inflamatório e fibrose intersticial moderada, sem crescentes, com depósitos mesangiais de IgM, C3 e C1.

Foram admitidos os diagnósticos de infecção por VIH-1 em estadio C3 CDC, crioglobulinemia tipo III com síndrome pulmão-rim, toxoplasmose cerebral e miocárdica e reactivação de infecção por CMV (por quantificação posterior de carga viral de CMV de 171.816cópias/mL [5,24 log]), para além de tromboembolismo pulmonar segmentar e endocardite de válvula mitral nativa tratada em internamento. O doente manteve terapêutica antirretroviral, corticoterapia, ganciclovir e terapêutica anti-*Toxoplasma* em regime terapêutico e posteriormente profiláctico com boa evolução clínica e posterior alta referenciado a consulta de Imunodepressão para seguimento.

Discussão

A imunoactivação sistémica crónica associada à infecção pelo VIH encontra-se documentada em estudos com recurso a diversos biomarcadores e é considerada um dos principais factores associados à depleção progressiva de linfócitos T CD4 e à síndrome de imunodeficiência adquirida (SIDA) comprovada em estadios tardios da infecção [2,3,4]. Uma activação do sistema

imunitário residual persiste mesmo nos casos em que é atingida supressão da replicação viral através de terapêutica antirretroviral combinada (TARc) [2,5,6]. A degradação do sistema imunitário decorrente da infecção e dos fenómenos de imunoactivação descritos condicionam o aumento da prevalência de infecções oportunistas observado na clínica [2].

Paralelamente, a interacção com o ambiente e o aumento do número de infecções oportunistas contribuem para a perpetuação de um estado de imunoactivação crónica e persistente [2]. A interacção dinâmica entre estes três factores – VIH, activação do sistema imunitário e doença oportunista – e a coexistência de manifestações clínicas decorrentes dos mesmos, em especial em doentes com diagnóstico tardio ou acentuada degradação imunológica, torna a abordagem destes doentes bastante complexa.

No caso clínico apresentado, para além da diversidade de hipóteses de diagnóstico diferencial a colocar pelo envolvimento de vários órgãos e sistemas, também a dicotomia fenómeno oportunista ou imunomediado contribuiu para acentuar a dificuldade no estabelecimento do diagnóstico e plano de tratamento mais adequados. Tendo sempre em mente a necessidade de excluir diversa patologia oportunista nos casos de diagnóstico inaugural em fase tardia da infecção, é também importante considerar outras etiologias tanto para um quadro prolongado como para uma descompensação aguda.

Por outro lado, a coexistência de outras comorbilidades, como por exemplo co-infecção por vírus hepatotrópicos, bem como a reactivação de infecções latentes por vírus imunogénicos altamente prevalentes, como o citomegalovírus (CMV) e o vírus Epstein-Barr (EBV), contribuem também para a manutenção deste estado pró-inflamatório e de activação/desregulação do sistema imunitário, ao qual se associam ainda fenómenos de hipercoagulabilidade e disfunção endotelial com aumento do risco cardiovascular [2,5].

O desenvolvimento de doença auto-imune estabelecida está também descrito, estando associado à desregulação imune já descrita e podendo ocorrer em todos os estadios da infecção por VIH, no entanto parece estar mais significativamente relacionado com a recuperação imunológica associada ao controlo virológico sob TARc e a estadios não-SIDA [7,8]. O espectro é bastante variado, passando não só por doença reumática sistémica, mas também por doença autoimune de órgão ou sistema, sarcoidose, vasculites ou síndrome anti-fosfolípido [7,8]. Dado o aparente aumento da prevalência deste tipo de patologias nos indivíduos que vivem com infecção por VIH, é essencial manter um elevado índice de suspeição e procurar activamente as suas manifestações. Poderá ainda ser considerada a criação de recomendações sobre o tema direccionadas para esta população de modo a melhorar os cuidados prestados [7].

Conclusão

Em suma, a gestão de todo o espectro de complicações associadas directa ou indirectamente à infecção por VIH exige conhecimento, actualização e dedicação constantes com o objectivo de assegurar o melhor seguimento para cada doente.

Referências

1. European Centre for Disease Prevention and Control/WHO Regional Office for Europe. HIV/AIDS surveillance in Europe 2017 – 2016 data. Stockholm: ECDC; 2017.
2. Paiardini M, Müller-Trutwin M. HIV-associated chronic immune activation. Immunol Rev. 2013;254:78-101.
3. Douek DC. Immune Activation, HIV Persistence and the Cure. Top Antivir Med. 2013;21(4):128-32.
4. d'Ettorre G, Paiardini M, Ceccarelli G, Silvestri G, and Vullo V. HIV-Associated Immune Activation: From Bench to Bedside. AIDS Res Hum Retroviruses. 2011;27(4):355-64.
5. Hsu DC, Sereti I. Serious Non-AIDS Events: Therapeutic Targets of Immune Activation and Chronic Inflammation in HIV Infection. Drugs. 2016;76(5):533-49.
6. Wada NI, Jacobson LP, Margolick JB, *et al*. The effect of HAART-induced HIV suppression on circulating markers of inflammation and immune activation. AIDS. 2015;29:463-71.
7. Roszkiewicz J, Smolewska E. Kaleidoscope of autoimmune diseases in HIV infection. Rheumatol Int. 2016;36(11):1481-91.
8. Iordache L, Launay O, Bouchaud O, *et al*. Autoimmune diseases in HIV-infected patients: 52 cases and literature review. Autoimmun Rev. 2014;13(8):850-7.

Intravascular lymphoma with exclusive involvement of the central nervous system presenting with myelopathy, epileptic seizures and encephalopathy

Linfoma intravascular com envolvimento exclusivo do sistema nervoso central com apresentação de mielopatia, crises epilépticas e encefalopatia

Pedro Coelho[1], Madalena Rosário[1], Pedro Monteiro[2], Marta Leal Bento[2], Filipa Falcão[1], Rafael Roque[1,3], M Luísa Albuquerque[1,4,5]

1 – Serviço de Neurologia, Departamento de Neurociências e Saúde Mental, Hospital de Santa Maria, Centro Hospitalar Universitário Lisboa Norte; 2 – Serviço de Hematologia, Hospital de Santa Maria, Centro Hospitalar Universitário Lisboa Norte; 3 – Laboratório de Neuropatologia, Serviço de Neurologia, Departamento de Neurociências e Saúde Mental, Hospital de Santa Maria, Centro Hospitalar Universitário Lisboa Norte; 4 – Faculdade de Medicina da Universidade de Lisboa, Lisboa; 5 – Instituto de Medicina Molecular, Lisboa

Abstract

Intravascular lymphoma (IVL) is a rare type of extranodal large cell lymphoma characterized by a selective growth of neoplastic cells within the lumina of small and medium-sized blood vessels of several organs, without an obvious extravascular tumor mass or circulating lymphoma cells in the peripheral blood.

It usually evolves with a multisystemic envolvement and follows an aggressive behaviour. In fact, most of the patients die within one year after the first symptoms start if no treatment is administered. Central nervous system (CNS) manifestations include nonspecific symptoms and signs, notably multifocal neurological symptoms.

We present a case of a 52-year-old female patient who presented with an almost exclusive CNS involvement, which initially exhibited a longitudinal extensive myeltis and subsequently developed multiple brain lesions, encephalopaty, psychosis, and seizures. Brain biopsy diagnosed IVL, reinforcing the diagnostic difficulty in the absence of systemic involvement.

Keywords: Intravascular lymphoma, Encephalopathy, Myelopathy, Vasculitis, Central Nervous System, Epileptic seizures

Resumo

O linfoma intravascular é um tipo raro de linfoma extranodal de grandes células, caracterizado por um crescimento selectivo de células neoplásicas dentro do lúmen dos vasos de pequeno e médio calibre de vários órgãos, sem uma massa tumoral extravascular óbvia ou células neoplásicas em circulação no sangue periférico.

Normalmente apresenta um envolvimento multissistémico e um comportamento agressivo, com a maioria dos doentes a morrer no espaço de um ano após o início dos sintomas sem terapêutica iniciada. As manifestações do sistema nervoso central (SNC) incluem sintomas e sinais

inespecíficos, nomeadamente sintomas neurológicos multifocais, o que torna o diagnóstico difícil caso não exista um elevado nível de suspeição clínica.

Reporta-se um caso clínico de uma doente de 52 anos do sexo feminino que se apresentou inicialmente com uma mielite longitudinalmente extensa e subsequentemente desenvolveu múltiplas lesões cerebrais, encefalopatia, psicose e crises epilépticas.

Palavras chave: Linfoma intravascular, Encefalopatia, Mielopatia, Vasculite, Sistema Nervoso Central, Crises epiléptica

Introduction

Intravascular lymphoma (IVL) is a rare type of extranodal large B-cell (in 85% of cases, though some T-cell cases have been described [1]), characterized by the selective growth of lymphoma cells within the lumina of vessels, in particular, capillaries, arterioles and venules, sparing large caliber vessels [2]. The exclusive intravascular localization of malignant cells is supposed to result from loss of function of adhesion molecules, which are required for tissue homing [3]. It occurs in adults, at a median age of 67 years and there is no gender preference. [2] This lymphoma is usually highly disseminated in extranodal sites, including the bone marrow, and may arise in virtually any organ. However, lymph nodes are usually spared [2].

The IVL incidence is unknown due to its rarity. Its diagnosis is challenging, since patients present most of the times with nonspecific laboratory and neuroimaging findings. 40–80% of IVL cases remain undiagnosed until after the autopsy [4].

The frequency and clinical presentation differ according to patients' geographical origin (West versus Far East). Two major patterns of clinical presentation have been recognized: a so-called classical form in the West, with predominant neurological and cutaneous involvement and a hemophagocytic syndrome-associated form (Asian variant). IVL is generally aggressive, except for cases with disease limited to the skin [2].

IVL involves the central nervous system in 34-85% of patients (depending on the series) and neurological symptoms include sensory and motor deficits or neuropathies, meningoradiculitis, paresthesia, hyposthenia, aphasia, dysarthria, hemiparesis, seizures, transient visual loss, vertigo and impaired cognitive function [5, 6]. Neuroimaging discloses CNS involvement only in half of the patients with neurological symptoms. There are no pathognomonic neuroradiological findings for IVL. Ischemic foci are the most common presentation pattern and therefore vasculitis is the most common differential diagnosis [7].

Initial CNS presentations are assumed with erroneous diagnoses of stroke, encephalomyelitis, Guillain-Barré syndrome, vasculitis, and multiple sclerosis [8].

Histological confirmation is necessary for diagnosis and it demonstrates large lymphoma cells sequestered within the intravascular spaces [9].

Chemotherapeutic regimens with Rituximab have significantly improved clinical outcomes of these patients, with a 3-year overall survival rate of 60-81% [2].

We present the case of a patient with recurrent isolated CNS involvement before diagnosis was possible.

Case report

A previously healthy 52-year-old woman presented to the emergency department (ER) with a three-week history of altered sensation in both legs, starting by a burning sensation on her feet that progressed to the root of the thighs and perineal area, accompanied by numbness. Immediately before coming to the ER, the patient had developed both urinary and fecal incontinence. She denied both fever or any systemic symptoms or infection as well as neurologic symptoms in the past.

On examination, there was hyposthesia and intense dysesthesias of the lower limbs with a sensory level at T12, brisk tendon reflexes and an ataxic gait with a positive Romberg sign, without motor compromise or proprioceptive deficits (vibratory sensation could not be evaluated due to painful dysesthesias). Thoraco-lumbar spine MRI showed hyperintense lesions at T8-T9 and T11-T12 with slight contrast enhancement, suggestive of myelitis (Fig 1 a-b). T2 sequence brain MRI demonstrated small hyperintense lesions and T1 sequence showed contrast enhancemenet in the frontal and parietal cortex, without DWI-sequence changes, making a differencial diagnosis of inflammatory, vasculitic or active demyelinating lesions (Fig 1 c-d).

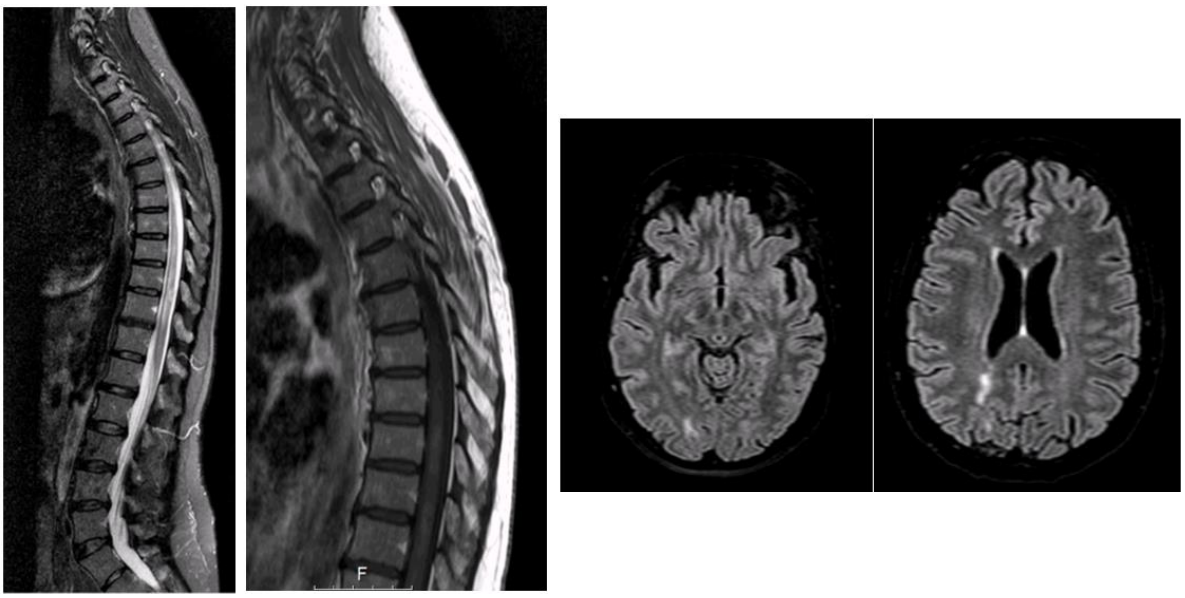

Fig 1 – Spine MRI showing T2 hyperintense lesions from D5 to the conus (a), and in T1 sequence slight contrast enhancement (b); Brain MRI showing white matter lesions at admission on FLAIR sequence without restricted diffusion (c,d).

The lumbar puncture showed no pleocytosis and was negative for neoplastic cells. Serologic testing for the most common infectious agents was negative, as were anti-AQP4 and anti-MOG antibodies. Her blood workout revealed mild anemia (Hb 11 g/dL) and M band on serum electrophoresis, with positive kappa free light chains, with normal autoimmune antibodies, infectious serologies, beta 2-microglobulin or LDH elevation, liver enzymes, creatinine, erythrocyte sedimentation rate, thyroid stimulating hormone, vitamin B12 and E, folate and copper levels. She

was started on iv corticosteroids for 5 days and symptomatic treatment (pregabalin). Despite treatment the neurological deficit progressed with paraplegia, absent tendon reflexes, urinary retention and fecal incontinence. A new dorsal MRI showed radiological worsening of the spinal lesion, with intense contrast enhancement (Fig 2).

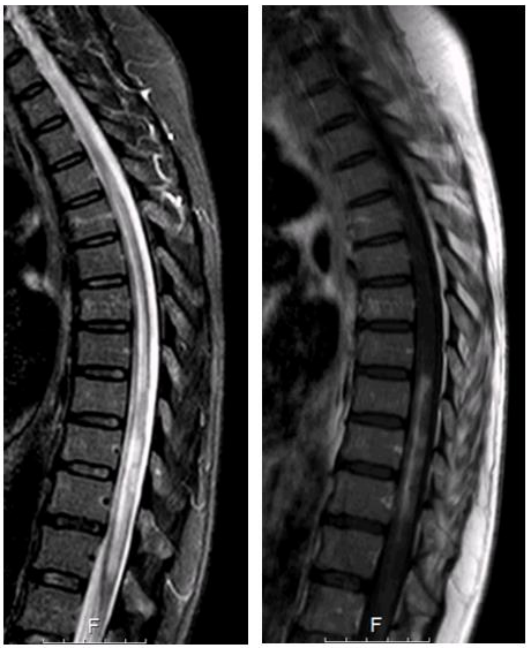

Fig 2- T2-STIR sequence showing progression of the previous lesions after 5-day methylprednisolone pulse, with involvement from D5 to the conus and (d) greater enhancement of the lesions with contrast.

During her hospital stay, the patient developed a phlebitis that complicated with bacteremia and an aortic valve abscess, which was treated and cured with a 6-week course of antibiotics. Further immunosuppressive treatments for the myelitis were not administered due to this infectious complication. She was discharged for rehabilitation.

Three months after discharge, the patient presented again to the ER with multiple generalized tonic-clonic seizures. On bedside examination she had temporal and spatial disorientation, fluctuating attentional deficits with reduced digit span and inverted digit span. Additional cognitive tests were difficult to evaluate due to the attentional deficits, but she also showed frequent word-finding difficulties in spontaneous speech and naming, even when clearly engaged in this task. Frontal Assessment Battery (FAB) testing scored 3/18. She maintained flaccid paraplegia with sensory level at D8-D9, urinary retention and fecal incontinence. Blood work-up maintained the previous anemia and M band on serum electrophoresis, with no other changes. New brain MRI confirmed multiple bilateral lesions in the corpus callosum, frontal, parietal and occipital lobes, with restricted diffusion in DWI sequence and slight non-specific contrast enhancement in some of the lesions (fig 3 a-d). Angio-MRI was normal. Electroencephalography (EEG) did not show epileptic activity. Contrast enhanced spine MRI showed longitudinally extensive lesion from D5 to the conus medularis with focal areas at D7-D8 and D9-D10 with intense contrast enhancement. Lumbar puncture showed elevated cerebrospinal fluid (CSF) protein without pleocytosis or CSF glucose

changes. Microbiology, immunohistochemistry, anatomopathological and oligoclonal bands were negative. Blood cultures and transesophageal echocardiogram were performed, which excluded active blood infection and recurrent endocarditis. This first work-up excluded the initial clinical suspicion of infectious complication.

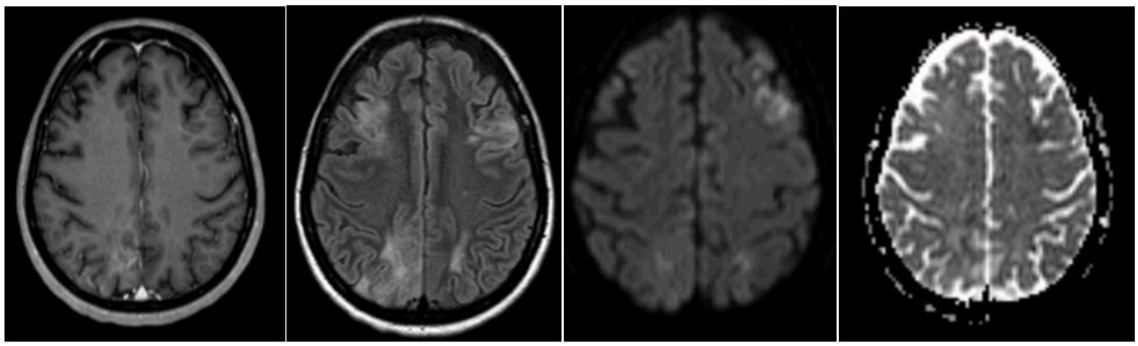

Fig 3 – Brain MRI at the second admission: a) there is contrast enhancement on the parasagittal right parieto-occipital area; b) FLAIR sequence showing cortical and subcortical lesions in both hemispheres; c) DWI sequence with some high signal lesions showing restricted diffusion, d) with corresponding low signal in ADC map sequence.

A second pulse of 5-days iv methyl-prednisolone was initiated, followed by prednisolone 1 mg/kg/day.The patient disclosed progressive cognitive impairment, visuospatial neglect and extinction in multiple sensory modalities. In addition, she developed psychosis and seizures.

Subsequent contrast-enhanced brain MRI showed new multiple lesions and progression of the previous ones with the same characteristics.

A brain biopsy was performed on one of the lesions on the occipital lobe. Histological examination showed large neoplastic lymphoid cells, with prominent nucleoli, mainly lodged in the lumina of the leptomeningeal and intraparenchymal vessels, especially the small capillaries. Immunohistochemistry revealed positive CD20, bcl-6 and MUM-1 and negative CD10 (fig 4). The patient was formally diagnosed with intravascular large B cell lymphoma.

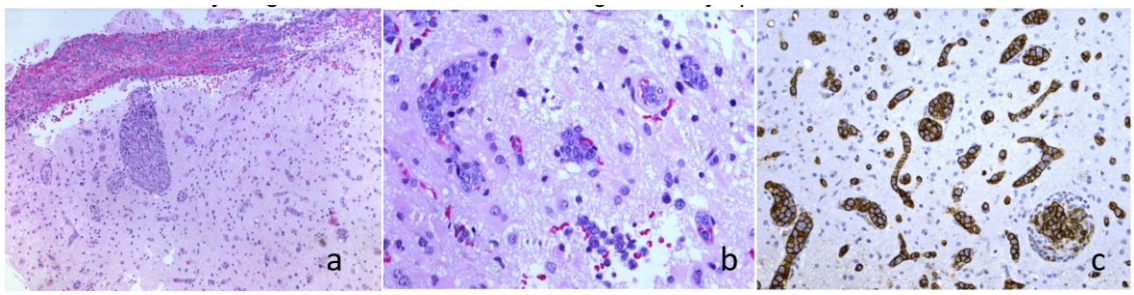

Fig 4 - The biopsy revealed small leptomeningeal and parenchymal vessels fulfilled with large lymphoid cells (figures 4 a) HE x 10) and b) HE x 40), with prominent nucleoli, CD20-positive (figure c) CD 20 x 20), MUM1-positive (not shown), BCL-6 positive (not shown) and CD10 negative (not shown), consistent with an intravascular large B-cell lymphoma. The neoplastic cells were mainly limited to the vessels with minimal extravascular extension. (HE: haematoxylin and eosin).

On the hematology department, physical examination was unremarkable, there were no detectable skin lesions, palpable superficial adenomegalies or hepatosplenomegaly. The previously

described neurologic defects were unchanged. Laboratory workup maintained mild normocytic normochromic anemia (Hb 11.4 g/dL), with normal lactate dehydrogenase, erythrocyte sedimentation rate and beta-2 microglobulin. Full body CT scan revealed a mild hepatomegaly without detectable enlarged lymph nodes or splenomegaly. The patient started combination chemotherapy using the R-CHOP and high dose methotrexate protocol (high dose methotrexate 3g/m^2, rituximab 375mg/m^2, cyclophosphamide 1200 mg/m^2, doxorubicin 40 mg/m^2, vincristine 80 mg/m^2 and prednisolone 80 mg/m^2). After 2 cycles, neurological examination was unchanged at 3 weeks follow-up.

Discussion

We discuss the rare case of a patient with B-cell IVL restrited to the CNS. IVL clinical presentation is varied and usually patients present with nonspecific clinical signs and symptoms, like constitutional B symptoms, which are seen in the majority of patients (55 to 85%), and with symptoms related to organ dysfunction affected by occlusion of blood vessels [10, 11]. The reason for the vascular occlusion in patients with IVL remains unclear, but some explanations include injury of the endothelial surface triggering thrombotic microangiopathy leading to platelet activation, thrombocytopenia and red blood cell fragmentation followed by the formation of microthrombi [12].

As in our case, neurological symptoms are manifold, including stroke-like episodes, (sub-acute) encephalopathy, cognitive impairment, seizures, psychosis, motor and sensory deficits, paresis, cranial neuropathy (particularly cranial nerves VII and VIII) and myelopathy [12, 13], and as such intravascular lymphoma should be considered in the differential diagnosis of unexplained neurological syndromes. Most patients with neurologic disease lack other manifestations, in particular cutaneous disease [13].

In this patient subacute myelopathy was the first manifestation. Myelitis as an initial presentation of IVL is uncommon, with only approximately 20 cases reported [14], and usually affects middle-age and elderly people, as opposed to inflammatory and demyelinating disorders [13, 14]. IVL should also be considered when myelopathy is associated with encephalopathy or other manifestations of multifocal disease, or when no etiology is evident for a longitudinally extensive myelitis.

The disease progression showed an extension of the intramedullary signal alteration till the conus. Conus medularis involvement should raise consideration of intravascular lymphoma as the conus this an unusual site of involvement in myelitis [13].

In patients with IVL, cerebral MRI may be normal or display hyperintense nonspecific white matter lesions on T2- or FLAIR-weighted images, indicating small vessel ischemic disease or demyelination. Likewise, obliteration of the affected blood vessels can lead to multifocal cerebral infarcts reflected by a subacute infarction pattern in the MRI. Findings mimicking CNS vasculitis in cerebral angiography appear in nearly half of all cases of IVL with CNS involvement [12]. On our case, angioMRI was normal. There are not typical or pathognomonic findings in brain images that can adequately distinguish these two diseases.

IVL is indeed often misdiagnosed as an inflammatory condition of the CNS due to its multifocal clinical pattern, notably CNS vasculitis. As such, immunosupressive therapy is done, with IVL patients presenting an temporary clinical response only to aggravate again as the disease ensues.

Corticotherapy was started in our patient, which seemed to have halted the disease temporarily, but her neurological condition aggravated with frank encephalopathy, psychosis and new brain MRI lesions.

One remarkable aspect of this case is that besides the mild anemia and monoclonal serum component, the patient did not show any other paraclinical signs (other hematological changes such as elevated LDH, beta 2-microglobulin or ESR), which are mostly present even in the almost neurological exclusive involvement [13].

On our case the first CSF was normal. However, CSF analysis usually presents with lymphocyte pleocytosis (more than 50% of cases) and elevated CSF protein (90% of cases) In 3% of cases, neoplastic cells can be found in CSF [7, 13].

The diagnostic work-up of IVL should include biopsies of organs known to be frequently involved in patients with IVL, and are mostly performed on brain, as in our patient, spine or skin, although any organ can be biopsied.

When there is an IVL suspicion, skin biopsies are recommended and can be diagnostic in the absence of skin lesions, because tumour cells are often seen in subcutaneous tissue irrespective of the absence of skin eruption [2]. Nevertheless, skin involvement is rare in patients with neurological symptoms [12].

The role of bone marrow biopsy is more controversial, where opinions often diverge, with one case series pointing only one out of eight patients with positive results [1].

FDG-PET and SPECT exams can be useful to determine biopsy site when there is suspicion of IVL [15].

Treatment with chemotherapy has been found to yield positive results, with some of the patients improving significantly from their neurological syndromes [14]. Most commonly used protocols include CHOP (cyclophosphamide, doxorubicin, vincristine and prednisolone) or R-CHOP (with rituximab) based schemes, as in other high grade lymphoma. CNS involvement is extremely frequent in IVL, and for that reason protocols should include regimens with adequate CNS penetration, as systemic high dose metotrexate, intrathecal chemotherapy and whole brain and/or spine radiation [12, 13] as in the case presented. These regimens can be both used for prophylaxis and targeted CNS disease [12]. In R-CHOP regimen, there is a 3-year overall survival of rate of 60—81%. However, CNS relapse, which occurs in ~25% of cases and neurolymphomatosis are serious complications in the rituximab era. Neither the clinical type of presentation nor clinical parameters predict CNS relapse [2].

In summary, IVL is a rare systemic disease that usually presents with a myriad of neurological symptoms, whose diagnosis is challenging and requires a high index of suspicion and an aggressive workup.

References

1. Savard M, Verreault S, Gould P V, Bernier V, Bouchard J-P. Intravascular Lymphoma with Conus Medullaris Syndrome Followed by Encephalopathy. Can. J. Neurol. Sci. 2008; 35: 366-371
2. Nakamura S, Ponzoni M, Campo E. Intravascular large B-cell lymphoma. In: Swerdlow S, Campo E, Harris N L, Stein H, Jaffe E S, Pileri S A, Thiele J, eds. World Health Organization Classification of Tumours of Haematopoietic and Lymphoid Tissues. Lyon: International Agency for Research on Cancer, 2017;
3. Ponzoni M, Arrigoni G, Gould VE et al. Lack of CD 29 (beta1 integrin) and CD 54 (ICAM-1) adhesion molecules in intravascular lymphomatosis. Hum Pathol. 2000; 31:220-6.
4. Yang T, Tian L, Li Q et al. A case of intravascular B-cell lymphoma presenting as myelopathy and diagnosed post mortem. J Neurol Sci. 2008; 272:196-8
5. Orwat D E, Batalis N I. Intravascular Large B-Cell Lymphoma. Arch Pathol Lab Med. 2012; 136: 333-338
6. Beristain, X, Azzarelli, B. The Neurological Masquerade of Intravascular Lymphomatosis, Arch Neurol. 2002; 59: 439-443
7. Mihaljevic B, Sternic N, Skender M et al. Intravascular large B-cell lymphoma of central nervous system - a report of two cases and literature review. Clin Neuropathol. 2010;29:233-8.
8. Zuckerman D, Seliem R, Hochberg E. Intravascular lymphoma: the oncologist's "great imitator". Oncologist. 2006; 11:496-502
9. Ponzoni M, Ferreri AJ, Campo E et al. Definition, Diagnosis, and Management of Intravascular Large B-Cell Lymphoma: Proposals and Perspectives From an International Consensus MeetingJ Clin Oncol. 2007;25:3168-3173
10. Ferreri AJ, Campo E, Seymour JF et al. Intravascular lymphoma: clinical presentation, natural history, management and prognostic factors in a series of 38 cases, with special emphasis on the 'cutaneous variant'. Br J Haematol. 2004;127:173-83.
11. Murase T, Yamaguchi M, Suzuki R et al. Intravascular large B-cell lymphoma (IVLBCL): a clinicopathologic study of 96 cases with special reference to the immunophenotypic heterogeneity of CD5. Blood. 2007;109:478-85
12. Fischer M, Iglseder S, Grams A et al. Intravascular large B-cell lymphoma mimicking central nervous system vasculites. Human Pathology: Case Reports. 2017; 8: 3–8
13. Kumar N, Keegan BM, Rodriguez FJ, Hammack JE, Kantarci OH. Intravascular lymphoma presenting as a longitudinally-extensive myelitis: diagnostic challenges and etiologic clues. J Neurol Sci. 2011; 303:146-9
14. Yunoki M, Suzuki K, Uneda A, Yoshino K. A case of intravascular lymphoma presenting as myelopathy diagnosed with a skin biopsy. Surg Neurol Int. 2015; 6(Suppl 13): S367–S370.
15. Yamada S, Nishii R, Oka S et al. FDG-PET a pivotal imaging modality for diagnosis of stroke-onset intravascular lymphoma. Arch Neurol. 2010; 67:366-7.

Agradecimentos

Os autores do trabalho gostariam de agradecer a ajuda do Prof. José Pimentel pela ajuda fundamental no diagnóstico neuropatológico; à Dr.ª Rita Peralta e à Dr.ª Daniela Alves pela ajuda com a orientação desta exposição.

The boundaries between persistent delusional disorder associated with alcohol use and alcohol induced psychosis

As fronteiras entre a perturbação delirante persistente associada ao uso de álcool e psicose induzida pelo álcool: a propósito de um caso clínico

Gabriela Andrade, Beatriz Côrte-Real, Filipa Novais, Tiago Mendes, Frederico Simões do Couto

Department of Psychiatry and Mental Health, Hospital Santa Maria, Centro Hospitalar Universitário Lisboa Norte, EPE

Abstract

The persistent delusional disorder associated with alcohol use and delusional subtype of alcohol-induced psychosis are very uncommon disorders that have similar manifestations. While the former is a primary psychotic disorder in which pathological alcohol intake is a comorbidity, in the latter there is an established relation between chronic heavy consumption and the development of psychotic symptoms.

Authors report a case of a middle-aged man with a history of daily consumption of two units of alcohol during thirty years until two years ago. This inaugural psychiatric presentation was characterized by the development of systematized persecutory delusional ideas without hallucinations and subsequently to the heavy alcohol consumption that persisted after one month of withdrawal.

The aim of this report is to highlight the importance of identifying the correct nosology of the alcohol-related psychosis, considering other diagnostic hypotheses, and the main therapeutic and prognostic implications of the mentioned conditions.

Key-words: Alcohol-related psychosis; persistent delusional disorder; nosology; differential diagnosis; treatment; prognosis.

Resumo

A perturbação delirante persistente associada ao consumo de álcool e o subtipo delirante da psicose induzida pelo álcool são perturbações muito incomuns que apresentam manifestações semelhantes. Enquanto que a primeira é uma perturbação psicótica primária na qual o consumo patológico de álcool constitui uma comorbilidade, na última existe uma relação entre o consumo excessivo e crónico e o desenvolvimento de sintomatologia psicótica.

Os autores apresentam o caso clínico de um homem de meia-idade com história de consumo diário de duas unidades de álcool durante trinta anos e até há dois anos atrás. A apresentação psiquiátrica inaugural caraterizou-se pelo desenvolvimento de ideação delirante persecutória sistematizada sem alucinações, subsequentemente ao consumo excessivo de álcool e que persistiu após um mês de abstinência.

Pretende-se abordar a importância da correta identificação nosológica do tipo de psicose associada ao álcool, considerando outras hipóteses diagnósticas, as principais implicações no tratamento e no prognóstico das condições mencionadas.

Palavras-chave: psicose relacionada com o álcool, perturbação delirante persistente, diagnóstico diferencial, tratamento, prognóstico

Introduction

The association between alcohol use and psychosis has been acknowledged for almost two centuries [1] and it is known that psychotic symptoms related to alcohol might be present in acute intoxication, withdrawal or chronic heavy alcohol consumption [2,3].

Persistent delusional disorder (PDD) is a very uncommon primary psychotic disease [4], which occurs in a heterogeneous group of patients with non-bizarre delusions being the predominant symptom [4–10]. The epidemiological data about its prevalence is scarce and the few available studies suggest that the prevalence of delusional disorder (not necessarily persistent delusional disorder) is 0.03% in general population, corresponding to 1-2% of all psychiatric inpatients The development of psychotic symptoms is not secondary to any organic, schizophrenic or affective disorder [10]. The diagnosis of the PDD is generally very stable over time [8]. Delusional disorder may occur in the context of alcoholism [8].

Alcohol-induced psychosis (AIP) described in the 10th edition of International Classification of Diseases (ICD-10) as psychotic disorder due to the use of alcohol is characterized by the presence of psychotic symptoms that are not explained on the basis of acute intoxication and do not form part of a withdrawal state [10] and occurs in a clear sensorium [1]. This secondary psychotic disorder has a lifetime prevalence of 0,4% in the general population and 4,0% in patients with alcohol dependence that may vary according the inclusion criteria used for diagnosis [1,3]. According to the predominant delusional content, it is classified in alcoholic hallucinosis, alcoholic jealousy, alcoholic paranoia and alcoholic psychosis not otherwise specified [2,3,8] and it may have similar manifestations to those found in primary psychotic disorders [2,3]. AIP is generally associated with chronic and heavy alcohol consumption [2,12] and the incidence is highest in working-age men [1].

Although it is known that PDD and AIP are distinct disorders from schizophrenia [1,8], few investigations addresses the nosological independence of AIP from PDD, especially in patients with solely paranoid symptoms in the context of chronic alcohol consumption.

The authors report a case of a patient with a late onset of delusional symptoms associated with the increased consumption of alcohol.

Case Report

We report the case of a middle-aged male patient born in a small village on the North of Portugal, with a young daughter, living alone in Lisbon since his divorce a decade ago. The patient has completed a higher degree and he has been teaching in high schools for the last two decades.

In the last two years, after being victim of an alleged aggression by one of his students, he has been absent from his work.

The patient does not have previous history of medical or psychiatric diseases. Regarding family history, one of his maternal uncles committed suicide in unspecified circumstances and there are no other first or second-degree relatives with known diagnosis of psychotic, affective or additive disorders. Concerning premorbid personality, the patient refers disinterest in social relationships and intimacy, being suspicious and overly sensitive about some real or perceived situations during his adulthood (cluster A personality).

Two years ago, the patient became progressively more worried and suspicious about some coincidences that were happening to him and, consequently, he stopped contacting his family and became even more isolated. During this period, the patient complained about insomnia and anxiety symptoms with the subsequent development of a secondary alcohol abuse disorder (currently, 90 g of alcohol daily), and, in his own words, “it was attributed to the alcohol anxiolytic effect because it had helped to deal with the preoccupations of being persecuted”. There is no evidence of sudden personality modification and any other significant daily changes.

Some weeks before the hospitalization, the patient described extreme anxiety, he said: “I understood the meaning of the things, there is a criminal network that was hired to hurt me and are related with the aggression at school”. He was convinced that “they have access to my personal information on email and they know where I am through the localization signal sent from my mobile phone”.

Previously to the psychiatric unit admission, the patient said that after watching a famous person being assaulted on the news, that he considered to look like himself, he went to the police office to complain that the aggression was supposed to be directed to him. Consequently, he was conducted to the emergency unit by police office agents, showing marked behavioural disorganization associated with acute alcoholic intoxication. During the observation, the patient was conscious, orientated, with psychomotor agitation and demonstrated an uncooperative and querulant attitude. The speech was spontaneous, fluent, organized and its content was related with the non-bizarre persecutory delusional thoughts and self-reference phenomena, with an important affective and behavioural component. The mood was anxious and occasionally he was irritated, with an adequate affective resonance. The patient showed no insight for his psychopathological condition.

Both physical and neurologic examination showed no relevant changes. Analytical evaluation identified a mean corpuscular volume at the upper limit of the reference range (97,4fL), hypertriglyceridemia (190mg/dL) and serum alcohol level of 1.1g/L (ten times the upper limit of the reference range). No other analytical alterations, including liver evaluation tests, were found. The brain MRI performed showed no significant changes.

Neuropsychological assessment performed on the twelfth day of hospitalization showed mainly a moderate to severe cognitive impairment in the episodic memory domain with associated mild to moderate deficit in visuo-spatial memory recall. Moreover, mild impairment in divided attention and visuo-perceptive abilities was registered. Interestingly, performance on executive functions was relatively on average. As regards to cognitive flexibility, indications of a diminished performance were

observed considering the expected pattern of functioning in the premorbid period. Moreover, results on the semantic verbal fluency and the working memory domains were at the lower limit.

The pharmacological approach included antipsychotics (olanzapine titrated until 15mg daily), high dose of thiamine (300 mg by intramuscular route during five days), oral acid folic supplementation (5mg daily) and benzodiazepines (during seven days).

Few days after the admission, there was a significant improvement of agitation and a decrease in preoccupation and anguish with delusions. No symptoms of withdrawal were observed during hospitalization. One month after hospital discharge, the delusional ideas and the absence of insight persisted.

Discussion

This clinical case highlights the importance of recognising the clinical features of PDD associated with alcohol consumption and the differential diagnosis with AIP. Both are very uncommon disorders and are associated with the late onset of psychiatric manifestations in a patient without personal or family history of mental illness. The exact chronological relation between the consumption and the onset of psychotic is also an important clinical aspect that should be considered in the differential diagnostic of alcohol-related disorders. In table 1, the authors present the main clinical features described in delusional disorder and in AIP.

The presence of sensitive personality and other cluster A personality characteristics, as well as the newly systematized, persecutory and querulant delusional symptoms that started after the occurrence of a meaningful personal event and their persistence for more than few months, are all suggestive of the diagnosis of PDD [6,10,13,14]. The reported case represents the understandable psychological reaction of psychotic paranoia due to a precipitant event in a patient with premorbid personality of a paranoid type, that was classically designated *sensitiver beziehungswahn* [4,13].

Although this clinical presentation is typical of PDD, delusional subtype of AIP and its therapeutic and prognostic implications cannot be excluded due to the regular consumption of 20g of alcohol daily. Against this last diagnosis is the fact that jealous delusional ideas are among the most common psychopathological findings in delusional subtype of AIP, instead of persecutory delusional content. The onset of psychotic symptomatology before the significant increase of alcohol consumption, and not after chronic excessive use, is also unfavourable to that diagnosis.

Nowadays, the scientific evidence about the underlying neurobiology, neurocognitive changes, treatment and outcomes of PDD and AIP is limited [1,8,9]. Most **of** the studies are about alcoholic hallucinosis and little is known about the delusional subtype of AIP and its relation with PDD associated with alcohol. This clinical report addresses the importance of clarifying the nosological relation between PDD and AIP and some explanatory hypothesis need to be considered: (1) delusional subtype of AIP and PDD are two distinct disorders and alcohol consumption is a common shared feature, which represent the cause of AIP and it constitutes a risk factor for PDD; (2) delusional subtype of AIP belongs to the PDD spectrum disorders; (3) and, finally, the AIP should not be considered as an independent nosology since the increase of alcohol consumption, besides the chronologic relation, has not a causality role in the development of psychotic symptoms.

The management of paranoid symptoms and delusional disorder is complex and difficult [5,9,14] and, although high quality evidence studies about the effectiveness of treatment in PDD and AIP are scarce [9,14], antipsychotic therapy is recommended. According to some authors, maintenance therapy is not necessary in abstinent patients with fully remission of AIP [1], differently to lifelong antipsychotic treatment generally prescribed in patients with PDD, due to the symptomatically persistence in almost half of the patients with delusional disorder [4]. In patients diagnosed with PDD, cognitive behaviour therapy seems to have additional short term benefits, once this strategy addresses the delusional development process and modifies emotional responses [5,9].

Regardless the diagnosis of PDD or AIP, alcohol abstinence is the modifier factor that should be taken in consideration. In fact, chronic heavy intake of alcohol is consistently related with cognitive decline [15] and recovery of cognitive skills appears to be linked to amount of recent alcohol use and duration of abstinence rather than lifetime alcohol consumption. Also, the clinical improvement of psychotic symptoms is associated with alcohol abstinence either in PDD and in AIP [1–3].

To conclude, the long-standing symptomatology before hospitalization and the absence of clinical remission after antipsychotic therapy and alcohol abstinence is suggestive of the persistence of delusional symptoms. Certainly, regular psychiatric assessment and a new neuropsychological evaluation in the follow-up will be crucial to monitor the profile of cognitive deficits and to determine whether it remains stable or evolves towards a pattern closer to that of a neurodegenerative process.

Conclusion

The differential diagnosis of patients with PDD associated with alcohol use and delusional type of AIP may be challenging due to the presence of similar manifestations. In addition, understanding if alcohol use has a primary or secondary role on the development of psychotic symptoms through history taking may help in the differential diagnosis between those clinical disorders**,** both related with late onset of psychiatric manifestations.

The main clinical implications are associated with the need of long-standing antipsychotic treatment in patients with PDD compared to those with AIP who generally have a good prognosis with clinical remission after withdrawal. In both, starting promptly antipsychotic treatment and planning an adequate treatment strategy addressing alcohol misuse, probably are the most important prognostic factors.

Verbal and written informed consent were obtained from the patient for publication of this case report. A copy of the written consent is available for review.

The authors have no conflict of interests.

The authors would like to express their gratitude to the Director of the Psychiatry and Mental Health Department, Prof. Dr. Luís Câmara Pestana, for the permission to publish this clinical report, and to the Chief of the Psychiatry Inpatient Unit, Dr. Arlindo Ralas, for the critical review.

References

1. Jordaan G.P. and Emsley R. Alcohol-induced psychotic disorder: A review. Metab Brain Dis. 2010;17:231-43.
2. Yang Z. Alcohol-Related Psychosis. Medscape. Dec 01,2017. Retrieved from https://emedicine.medscape.com/article/289848-overview.
3. Stankewicz H and Salen P. Alcohol Related Psychosis. StatPearls Artic. October 9, 2017.Retrieved from https://www.ncbi.nlm.nih.gov/books/NBK459134/.
4. Semple D and Smyth Roger. Schizophrenia and related disorders. In: Oxford Handbook of Psychiatry. 3rd ed. 2013.
5. Roudsari MJ, Chun J and Manschreck TC. Current Treatments for Delusional Disorder. Curr Treat Options Psychiatry . 2015;2:151–67.
6. Couto, FS. Perturbação Delirante Crónica In: Figueira ML, Sampaio D and Afonso P, Manual de Psiquiatria Clínica. Lisboa: Lidel, 2015; 192-196.
7. Bourgeois JA. Delusional Disorder. Medscape. Nov 15, 2017. Retrieved from: https://emedicine.medscape.com/article/292991-overview
8. Soyka M, Zingg C and Baumgärtner G. Prevalence of delusional disorder among psychiatric inpatients: Data from the German hospital register. Neuropsychiatry. 2011; 1:319–323.
9. Skelton M, Khokar WA and, Thacker SP. Treatments for delusional disorder [Review]. Cochrane. 2015; 5:10-12.
10. The International Statistical Classification of Diseases and Related Health Problems. Tenth Revision. Geneva: World Health Organization, 1992.
11. Engelhard CP, Touquet G, Tansens A et al. Alcohol-induced psychotic disorder: a systematic literature review. Tijdschr Psychiatr. 2015; 57:192–201.
12. Byrne PR. A Look at Alcohol-Induced Psychosis. NEJM Journal Watch. September, 2010. Retrieved from: https://www.jwatch.org/jp201010180000003/2010/10/18/look-alcohol-induced-psychosis.
13. Casey P and Kelly B. Disorders of Though and Speech. In: Fish's Clinical Psychopathology: signs and symptoms in Psychiatry. Garlek: 2007;39-43.
14. Harrison P, Cowen P, Burns T, Fazel M. Paranoid symptoms and syndromes. In: Shorter Oxford Textbook of Psychiatry. Glasgow: Oxford University Press, 2018; 299-312.
15. Topiwala A, Ebmeier KP. Effects of drinking on late-life brain and cognition. Evid Based Ment Heal. 2017; 21:1-4.

Table 1 - Clinical features of delusional disorder and alcohol induced psychosis

	Delusional disorder [4–6,9–10,14]	**Alcohol induced psychosis** [1,2,4,8,10–12]
Psychotic disorder	Primary	Secondary
Classification	Paranoid (including paranoia querulans) Jealousy Grandiose Somatic	Alcoholic hallucinosis Alcoholic jealousy Alcoholic paranoia Alcoholic psychosis not otherwise specified
Prevalence	0,03% in general population	0.4% in general population and 4% among alcohol dependent patients
Family history	Infrequent	Infrequent

	Delusional disorder [4–6,9–10,14]	**Alcohol induced psychosis** [1,2,4,8,10–12]
Premorbid personality	Cluster A	Cluster A
Previous academic and professional level of functioning	Good	Good
Age of onset	Late onset during the 3rd-4th decade of life	Late onset during the 3rd-4th decade of life
Alcohol consumption	Secondary alcohol use disorder (comorbidity)	Primary alcohol use disorder with psychotic symptoms related with chronic heavy drinking pattern that persist after acute intoxication and withdrawal periods.
Clinical features	Delusional ideas (more frequently persecutory) systematized with a non-bizarre content without hallucinations. Important affective and behaviour component related with delusional content. Insomnia, anxiety and depressive symptoms are frequent.	Auditory hallucinations (alcoholic hallucinosis) and persecutory delusions (alcoholic paranoia). Absence of sensorium and formal thought process alterations Insomnia, anxiety and depressive symptoms are frequent.
Negative symptoms	Absent	Absent
Insight	Generally absent	Better insight and judgement
Neurocognitive changes	None or mild in attention, working memory or executive function. Jumping to conclusions bias.	May have neurocognitive changes related with chronic alcohol abuse (mainly, at memory domain)
Pharmacological treatment	Antipsychotic drugs <u>are the first choice.</u>	Alcohol abstinence. Antipsychotics should be considered.
Non-pharmacological approach	Individual and supportive therapy. Short-term cognitive behaviour therapy focusing on interpersonal sensitivity, reasoning process and emotional responses.	Referral to a substance-abuse unit, with the participation in support groups.
Functional impairment	None or slight besides the repercussions related with the delusional content	Moderate
Prognosis	In delusional disorder, remission occurs in 33-50% of all patients, improvement is expected in 10% and symptoms may persist in 30-50%. Better prognosis for the persecutory or jealous subtypes. Worst outcomes if symptoms have persisted for more than 6 months. Efficacy of antipsychotic treatment is limited and frequently the delusional thoughts persist~~s~~, with improvement of the affective and behavioural repercussions related to the delirium content.	May remit with alcoholic abstinence. 10-20% of the cases evolves to chronic psychosis. Good prognosis when compared with patients with PDD.

Ileus biliar: uma causa rara de oclusão intestinal

Gallstone ileus: a rare cause of bowel obstruction

Ricardo Pereira Dias[1], David Lopes[2], António Fernandes[1], Inês Leite[1], José Fonseca Santos[1]

1 Serviço de Imagiologia Geral – Centro Hospitalar Lisboa Norte E.P.E., Hospital Santa Maria
2 Serviço de Cirurgia Geral – Centro Hospitalar Lisboa Norte Norte E.P.E., Hospital Santa Maria

Corresponding author: Ricardo Pereira Dias, Medical Resident in Radiology, Serviço de Imagiologia Geral – Centro Hospitalar Lisboa Norte E.P.E., Hospital Santa Maria, Avenida Professor Egas Moniz,1649-035, Lisboa, Portugal. Correio electrónico: pereira.dias.ricardo@gmail.com

Resumo

O ileus biliar é uma causa rara de oclusão mecânica do intestino. Ocorre habitualmente devido à migração de cálculos biliares através de uma fístula que conecta a vesícula biliar ao trato gastrointestinal. As localizações mais frequentes de impactação dos cálculos são o ileon terminal e a válvula ileocecal. Reportamos o caso de uma doente com 70 anos de idade com dor abdominal aguda cuja avaliação imagiológica por radiografia simples do abdómen, ecografia abdominal e tomografia computorizada revelou a presença da tríade de Rigler, compatível com o diagnóstico de ileus biliar. A doente foi submetida a cirurgia, tendo-se efetuado extração do cálculo por enterotomia simples com resolução completa do quadro oclusivo.

Palavras-chave: Ileus Biliar; Tríade de Rigler; Oclusão Intestinal

Abstract

Gallstone ileus (GI) is a rare cause of mechanical bowel obstruction. It usually occurs due to migration of gallstones through a fistula that connects the gallbladder with the gastrointestinal tract. The commonest sites of impaction are in the terminal ileum and ileocecal valve. We report the case of a 70 years old female patient presenting with acute abdominal pain in which the imaging evaluation with plain abdominal radiograph, abdominal ultrasound and computed tomography demonstrated the Rigler's triad, allowing the diagnosis of GI. She underwent surgical treatment with gallstone extraction by a simple enterotomy leading to full recovery of the patient.

Keywords: Gallstone Ileus; Rigler's Triad; Bowel Obstruction.

Introduction

Gallstone ileus (GI) is a rare cause of mechanical bowel obstruction (0.4–5%) [1] characterized by the presence of a gallstone in the bowel lumen, usually due to a fistula that connects the gallbladder with the gastrointestinal tract or, less often, following endoscopic retrograde cholangiopancreatography [1,2]. It affects more commonly the elderly patient population with a female predominance and is related with a history of gallstones and cholecystitis [1-3]. GI must be

considered in the differential diagnosis of mechanical bowel obstructions, mainly those affecting small bowel and particularly in elderly patients in which nonspecific findings during physical examination are common. We present the case of a 70-year-old female patient with the classic imaging features of GI. The aim of this report is to remind physicians to be aware of this rare entity along with a review of the current literature with a focus on imaging findings.

Case presentation

We report the case of a 70-years old Caucasian woman that presented at the Emergency Department of our hospital in April 2017 complaining of vomiting and abdominal pain of recent onset (less than 12 hours). The patient denied fever, cough, chest pain or dyspnea. On physical examination, the patient appeared distressed and her abdomen was diffusely tender to palpation. The patient had a medical history of hypertension and symptomatic gallstone disease with previous episodes of biliary colic. Her past surgical history consisted of total thyroidectomy.

The laboratory findings at admission showed significant leukocytosis (17,2x10^9/L) and elevated C-reactive protein (4,6 mg/dL). Aspartate aminotransferase (AST), alanine aminotransferase (ALT), Y-glutamyl transpeptidase (GGT), alkaline phosphatase (AP) and bilirubin levels were within the normal range.

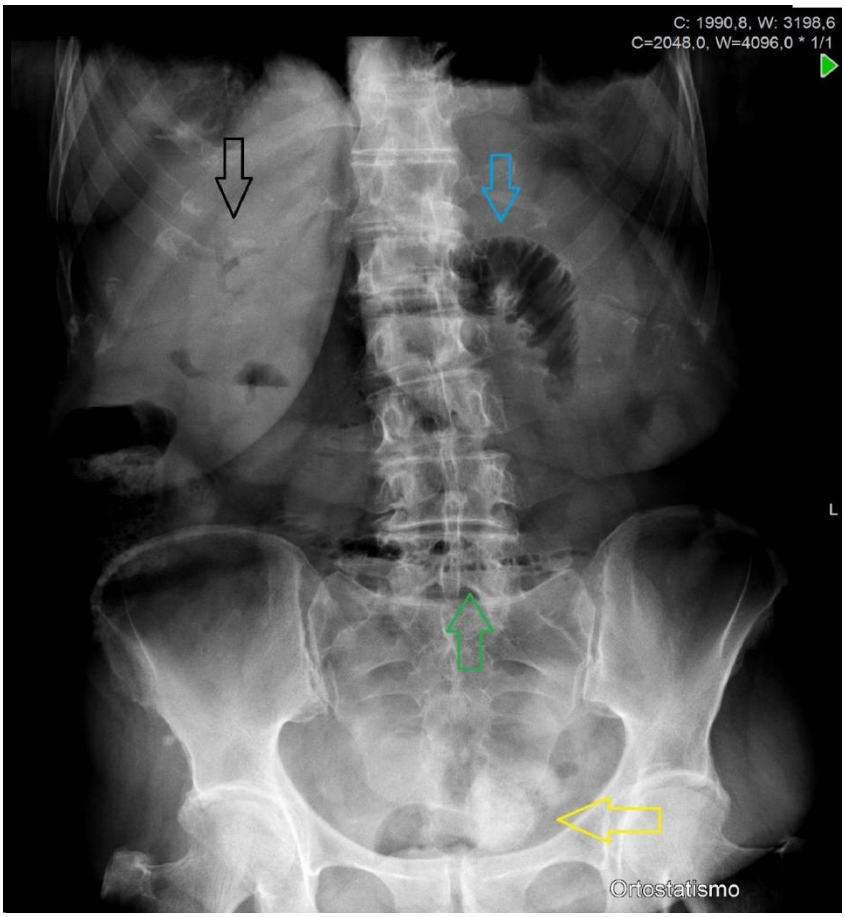

Figure 1 – The plain abdominal radiograph demonstrated the Rigler's Triad: i*) pneumobilia (black arrow); ii) a radio-paque gallstone located in the lower left abdominal quadrant (yellow arrow); iii) dilatation of small bowel loops. The presence of the "stretch" sign (blue arrow) and the "string of beads" sign (green arrow) were indicative of small bowel obstruction*

A plain abdominal radiograph (Fig.1) was obtained at admission and the patient was referred to our Radiology Department to perform an abdominal ultrasound (Fig. 2). The plain abdominal radiograph (Fig.1) demonstrated signs of small bowel obstruction (SBO), namely: i) a central dilated small bowel loop which was partially filled with gas outlining the valvulae conniventes (“stretch” sign); ii) a certain paucity of small-bowel gas due to fluid-filled loops of bowel, with a small amount of remaining gas trapped in folds between the valvulae conniventes (“string of beads” sign). In addition, the plain abdominal radiograph also revealed pneumobilia and an image suggestive of a radio-opaque stone in lower left abdominal quadrant. The subsequent abdominal ultrasound (Figure 2) confirmed the presence of pneumobilia and multiple dilated small bowell loops. The gallbladder was

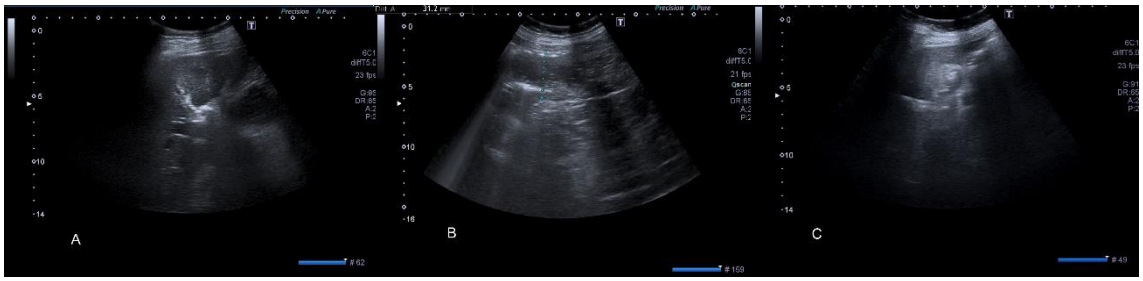

Figure 2 – Images from abdominal ultrasound. A*, Air in the biliary tree.* ***B****, Multiple dilated small bowel loops. C, The gallbladder was markedly difficult to visualize but the presence of hyperechoic foci with posterior acoustic dirty shadowing in the gallbladder bed was indicative of air in the gallbladder*

markedly difficult to visualize. However, we identified the presence of hyperechoic foci with posterior acoustic dirty shadowing in the gallbladder bed indicative of air inside the gallbladder. Nevertheless, the apparent radio-opaque stone visualized on the plain abdominal radiograph was not identified with ultrasound. These radiological findings were suggestive of SBO due to GI and a contrast-enhanced computed tomography (CT) was subsequently performed which revealed multiple dilated predominantly fluid-filled small bowel loops and decompressed distal small bowel loops indicative of SBO with the point of transition localized at the terminal ileum where a high attenuation intraluminal filling defect (with a maximal diameter of 3,4 cm) was present (Fig. 3) and consistent with the hypothesis of a gallstone that eroded from the gallbladder to obstruct the small bowel. Indeed, the CT also revealed a cholecystoduodenal fistula with resulting gas in the gallbladder and biliary tree (Fig. 4). There were also inflammatory signs around the gallbladder bed. No signs of coexistent ischemia of the affected gastrointestinal tract neither presence of free extraluminal gas or ascites were seen on CT.

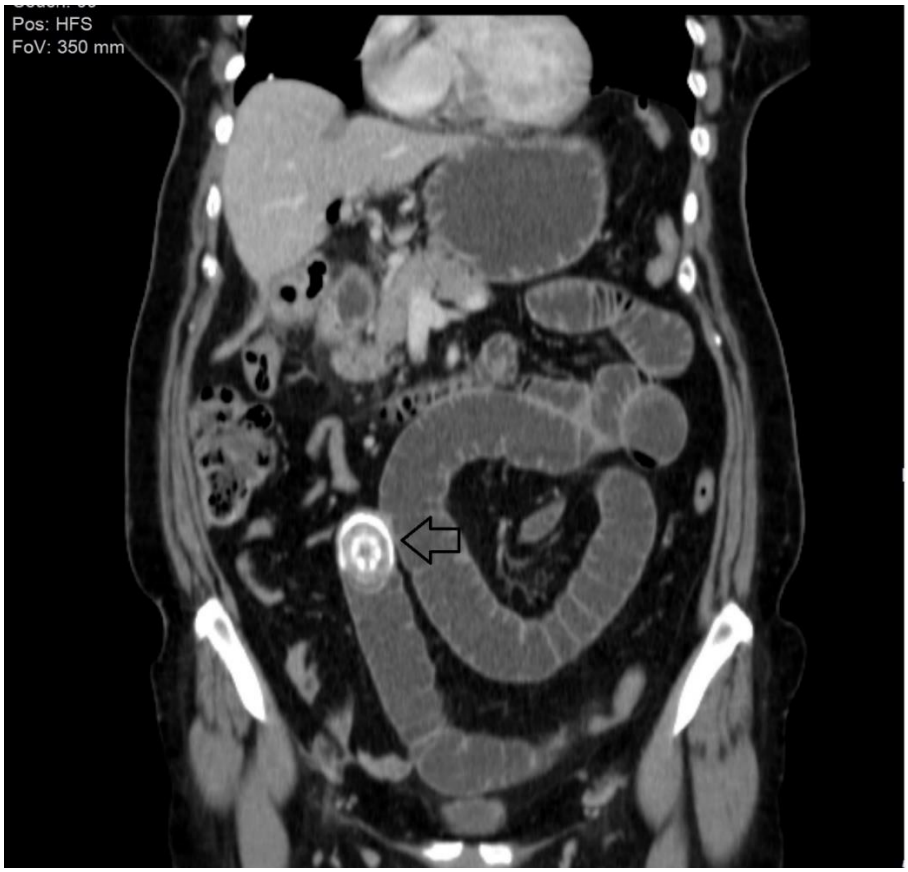

Figure 3 – A coronal image from contrast-enhanced tomographic computed scan. *Dilated fluid-filled small bowel loops and decompressed distal small bowel consistent with obstruction. The transition point corresponds to a high attenuation intraluminal filling defect (arrow), measuring 3 cm, which proved to represent a gallstone that eroded from the gallbladder to obstruct the small bowel*

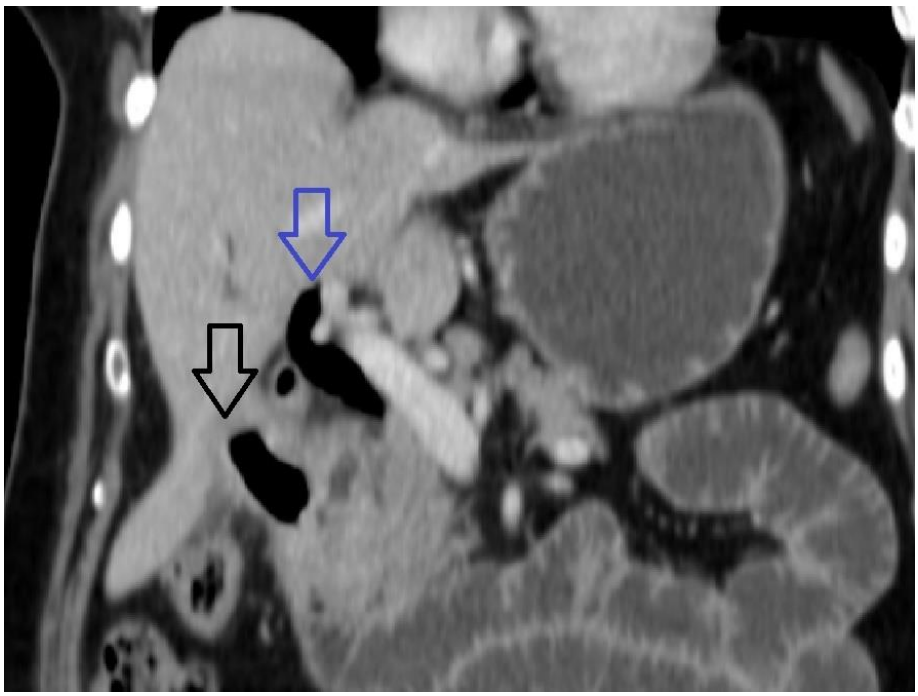

Figure 4 – Coronal image from contrast-enhanced computed tomographic scan*. A cholecystoduodenal fistula (black arrow) was observed with resulting gas in the gallbladder and biliary tree (blue arrow).*

The clinical and radiological findings of the patient indicated a SBO due to GI. Accordingly, the patient underwent surgical treatment with gallstone extraction by a enterolithotomy leading to immediate relief of obstructive symptoms. There were no complications on the post-operative course and the patient was discharged home after full recovery.

Discussion

GI accounts for a small percentage of cases of mechanical bowel obstruction in the general population but such percentage rises to 25% in patients older than 65 [4]. Moreover, 70% of patients with GI are over 65 years [5]. Given the higher prevalence of gallbladder disease in women, there is a female–male ratio of 4–7:1[1]. Mainly due to the patient's demographics, concomitant comorbidities and delayed diagnosis, GI is associated with a mortality and morbidity rate of 7-30% [1,6]. Thus, in elderly patients presenting with SBO, a high index of suspicion for GI is recommended.

The first clinical manifestation is the occurrence of a very strong colic, localized in the right hypocondrium and epigastrium, which corresponds to the formation of a biliary-digestive fistula [7]. Although cholecystoduodenal fistula is the most common (68% of cases), other fistulations are seen, including cholecysto-jejunal, cholecysto-colonic (5–25%), cholecystoduodenal-colonic (2.5%) and cholecysto-gastric [1,7]. At the beginning, the GI symptoms may present with a "migrating pain" which is believed to be due to a "tumbling phenomenon": driven by peristalsis, the gallstone has an intermittent distal migration along the gastrointestinal tract [2,8,9]. There may be a momentary attenuation of symptoms (from few hours to some days), after which arise repeated painful crises of the occlusive type [8,9]. The size of the stone represents a key factor in the development GI, as a stone bigger than 2.5cm can cause a bowel obstruction [1,2]. Still, smaller stones can cause GI in cases of stenosis. The gallstone usually impacts the terminal ileus or the ileocecal valve (60% of cases) due to their anatomically narrow lumen [1,8]. Other sites of stone impaction are the jejunum (16%), stomach (14%), colon (4%), and duodenum (3.5%) [1,8]. If the gallstone is small, it may be expelled with no harm to the patient leaving a biliary-digestive fistula that can remain unknown.

Since it may be difficult to clinically recognize GI, imaging plays a pivotal role in the diagnosis. Plain abdominal radiograph is traditionally the first imaging modality in the assessment of abdominal pain. Radiological presentation is pathognomonic of GI if it classically demonstrates Rigler's triad [10], namely: i) pneumobilia; ii) aberrantly located radio-opaque gallstone (position that can change during the following hours and days); iii) intestine loops dilatation and air-fluid levels (mainly if migrating, fluctuating and changing appearance). Diagnosis can be made if two out of three signs are identified [1,2]. However, such triad, is present in less than a half of patients [11] since only 10% of gallstones are sufficiently calcified to be radio-opaque [1] and that there is a lack of consistency in detecting air within the biliary tree [1,12]. To avoid misdiagnosis in the presence of pneumobilia, other differential diagnoses must also be considered: recent endoscopic retrograde cholangiopancreatography, oddi sphincterotomy, and common bile duct-duodenal anastomosis [1]. When used in conjunction with plain abdominal radiograph, ultrasound contributes to GI diagnosis improving sensitivity up to 74% since it can show the complete Rigler's triad when plain abdominal radiograph shows only SBO [9,13]. The following ultrasonography findings may be present: absent visualization of the gallbladder

or presence of hyperechoic foci with posterior acoustic shadowing in the gallbladder bed, aerobilia, gallstone obstructing intestine lumen and intestine loops dilatation [9]. Despite its ability to detect gallstone migration to the bowel, it is less useful in identifying fistula. Fistula tract can be seen if it is filled with fluid or air; however, it can confuse with other linear structures like common bile duct. Previous studies have concluded that CT is the more accurate for the diagnosis of GI [1,2] (with a sensitivity up to 93% [14]), showing the classical signs of Rigler's triad even when neither plain abdominal radiograph, nor ultrasound could demonstrate them [12]. In addition, CT allows to: i) identify the presence and number of gallstones, their accurate dimensions and impaction sites; ii) visualize the point of obstruction; iii) identify and characterize the fistula site; iv) evaluate inflammatory changes of the gallbladder; v) detect oedema and ischemia of the affected gastrointestinal tract (with use of contrast-enhanced CT), improving the diagnosis and choice of treatment [1]. Since in 15–25% of cases the gallstone may appear as isodense as surrounding fluid and thus difficult to visualize on CT [1,2] it has been suggested that magnetic resonance cholangiopancreatography might be useful. Indeed, the appearance of signal void in gallstone against the high signal in surrounding fluid provides accurate location of impaction and accurate measurement of the size of gallstone [1,2]. It is also able to demonstrate and characterize fistulas that may be missed on CT [15]. However, the current role of magnetic resonance in the emergency setting is still limited in our daily practice.

In our case report, plain abdominal radiograph and ultrasound yielded helpful clues regarding the presence of Rigler's triad and CT accurately confirmed the diagnosis allowing an accurate evaluation of the SBO, localization and measurement of the impacted gallstone and identification of the cholecystoduodenal fistula. The main clinical problem to be solved was the SBO caused by the impacted gallstone. Although some conservative treatments (endoscopic removal and lithotripsy) have been developed with favourable outcomes in specific situations, surgical treatment remains the only and preferable therapy in most patients for the time of diagnosis [2,3]. The minor clinical problem in our case was the biliodigestive fistula. Indeed, the main long-standing controversy in the surgical management of GI is whether biliary surgery - cholecystectomy and fistula closure - should be carried out at the same time as the relief of SBO (one-stage procedure), performed later (two-stage procedure) or not at all [2,3]. Although leaving the diseased gallbladder and cholecystoenteric fistula can predispose the patient to recurrent symptoms, relief of SBO with enterolithotomy alone is considered by different authors as the best option for most patients with GI [2,3,6]. In fact, complications related to unresected cholecystoenteric fistula are rare and only 10% of patients eventually require reoperation [16]. The one-stage procedure leads to prolonged operating time, is technically demanding and carries the risk of enteric and biliary leakage leading to even higher mortality (up to 50%) [17] and should be offered only to highly selected patients with absolute indications for biliary surgery [2]. Accordingly, a simple enterotomy was performed in our patient with complete recovery.

Conclusions

GI is an important differential diagnosis in elderly patients presenting with SBO. Despite its rarity, physicians should be aware of the potential of GI in individuals with a history of gallbladder disease. In our case, plain abdominal radiograph and ultrasound yielded helpful clues and CT accurately confirmed the diagnosis. Timely surgery to remove the obstructing gallstone can be lifesaving.

References

[1] Chuah PS, Curtis J, Misra N, Hikmat D, Chawla S. Pictorial review: the pearls and pitfalls of the radiological manifestations of gallstone ileus. Abdom Radiol (NY). 2017 Apr;42(4):1169-1175.

[2] Nuño-Guzmán CM, Marín-Contreras ME, Figueroa-Sánchez M, Corona JL. Gallstone ileus, clinical presentation, diagnostic and treatment approach. World J Gastrointest Surg. 2016 Jan 27;8(1):65-76.

[3] Ploneda-Valencia CF, Gallo-Morales M, Rinchon C et al. Gallstone ileus: An overview of the literature. Rev Gastroenterol Mex. 2017 Apr 19. pii: S0375-0906(17)30013-7.

[4] Reisner RM, Cohen JR. Gallstone ileus: a review of 1001 reported cases, Am Surg. 1994 Jun;60(6):441-6.

[5] Ayantunde AA, Agrawal A. Gallstone ileus: Diagnosis and Management. World J Surg. 2007 Jun;31(6):1292-7.

[6] Halabi WJ, Kang CY, Ketana N et al. Surgery for gallstone ileus: a nationwide comparison of trends and outcomes. Ann Surg. 2014 Feb;259(2):329-35.

[7] Berger MY, van der Velden JJ, Lijmer JG, de Kort H, Prins A, Bohnen AM. Abdominal symptoms: do they predict gallstones? A systematic review. Scand J Gastroenterol. 2000 Jan;35(1):70-6.

[8] Beuran M, Ivanov I, Venter MD. Gallstone ileus--clinical and therapeutic aspects. J Med Life. 2010 Oct-Dec;3(4):365-71.

[9] D. Michele, G. Luciano, F. Massimiliano et al. Usefulness of CT-scan in the diagnosis and therapeutic approach of gallstoneileus: report of two surgically treated cases. BMC Surg. 2013; 13(Suppl 2): S6.

[10] Rigler LG, Borman CN, Noble JF. Gallstone obstruction: pathogenesis and roentgen manifestations. JAMA 1941; 117: 1753-1759

[11] Lassandro F, Gagliardi N, Scuderi M, Pinto A, Gatta G, Mazzeo R. Gallstone ileus analysis of radiological findings in 27 patients. Eur J Radiol. 2004 Apr;50(1):23-9.

[12] Balthazar EJ, Schechter LS. Air in gallbladder: a frequent finding in gallstone ileus. AJR Am J Roentgenol. 1978 Aug;131(2):219-22.

[13] Lasson A, Lorén I, Nilsson A, Nirhov N, Nilsson P. Ultrasonography in gallstone ileus: a diagnostic challenge. Eur J Surg. 1995 Apr;161(4):259-63.

[14] Yu CY, Lin CC, Shyu RY et al. Value of CT in the diagnosis and management of gallstone ileus. World J Gastroenterol. 2005 Apr 14;11(14):2142-7.

[15] Pickhardt PJ, Friedland JA, Hruza DS, Fisher AJ. Case report. CT, MR cholangiopancreatography, and endoscopy findings in Bouveret's syndrome. AJR Am J Roentgenol. 2003 Apr;180(4):1033-5.

[16] Doko M, Zovak M, Kopljar M, Glavan E, Ljubicic N, Hochstädter H. Comparison of surgical treatments of gallstone ileus: preliminary report. World J Surg. 2003 Apr;27(4):400-4.

[17] Kirchmayr W, Mühlmann G, Zitt M, Bodner J, Weiss H, Klaus A. Gallstone ileus: rare and still controversial. ANZ J Surg. 2005 Apr;75(4):234-8.

Pelvic actinomycosis – Suspicious adnexal mass

Actinomicose pélvica – Massa anexial suspeita de neoplasia ginecológica

Maria Pulido Valente[1], Tiago Marques[2], Ana Rodrigues[1], Carlos Calhaz-Jorge[1]

1-Departamento de Obstetrícia, Ginecologia e Medicina de Reprodução do CHULN – Hospital Universitário de Santa Maria, Faculdade de Medicina da Universidade de Lisboa, CAML - Centro Académico de Medicina de Lisboa; 2-Serviço de Doenças Infecciosas do CHULN – Hospital Universitário de Santa Maria, Faculdade de Medicina da Universidade de Lisboa, CAML - Centro Académico de Medicina de Lisboa

Abstract

Actinomycosis is a chronic bacterial infection caused by *Actinomyces spp,* a gram-positive anaerobic bacterium. Its symptomatology can simulate some malignant pelvic tumors, causing pelvic abscess and fistula. Actinomycosis is an opportunistic infection and therefore requires an alteration of normal mucous barrier.

We present a case of a 26-year-old female patient who was referred to the gynecologic oncology clinic due to a suspicious adnexal mass. The symptoms, laboratory findings and diagnostic images were inconclusive. The diagnosis was confirmed by CT guided biopsy which revealed actinomycoses and excluded malignancy. There was a complete resolution of the infection after long-term antibiotherapy.

Pelvic actinomycosis can be misdiagnosed due to its rarity. Nevertheless, should be considered in the differential diagnosis of pelvic lesions, in special if there is history of an intrauterine device.

Keywords: actinomicosis, adnexial mass, intrauterine device

Resumo

A actinomicose é uma infeção bacteriana crónica causada por bacilos anaeróbios gram-positivos do género *Actinomyces spp*. A sua apresentação clínica pode mimetizar uma neoplasia ginecológica invasiva, podendo causar abcesso pélvico e fístula. É uma infeção oportunista pelo que necessita de uma lesão da barreira epitelial inicial.

Apresentamos o caso de uma mulher de 26 anos referenciada à consulta de ginecologia oncológica por massa anexial suspeita. Os sintomas, avaliação analítica e exames de imagem foram inconclusivos. O diagnóstico foi confirmado por uma biópsia guiada por tomografia computorizada (TC) que revelou a presença de actinomicose, excluindo patologia neoplásica. Observou-se uma resolução completa da infeção com antibioterapia de longa duração.

A actinomicose pélvica é difícil de diagnosticar pelo que deve ser considerada no diagnóstico diferencial de massa pélvica, sobretudo se houver história de uso de dispositivo intra-uterino.

Palavras-chave: actinomicose, massa anexial, massa pélvica, dispostivo intra-uterino

Introdução

A actinomicose é uma infeção granulomatosa crónica e supurativa causada por uma bactéria gram-positiva anaeróbica ou microaerofílica denominada *Actinomyces israelii.* Trata-se de um organismo comensal da flora da orofaringe, trato gastrointestinal e urogenital [1]. A infeção por este agente ocorre mais frequentemente na região cervico-facial (50-65%), abdominal (20%) e torácica (15%) [2].

Devido ao seu baixo potencial de virulência, a actinomicose é uma infeção oportunista que só atravessa a superfície epitelial aquando de uma lesão da mucosa quer por trauma, cirurgia ou infeção. Esta bactéria dissemina-se pelos tecidos formando abcessos e fístulas [3].

A prevalência de actinomicose pélvica é desconhecida e associa-se à imunossupressão e à utilização de dispositivos intra-uterinos (DIU) [4].

A actinomicose pélvica manifesta-se habitualmente por endometrite, salpingo-ooforite ou abcesso tubo-ovárico [5]. O aparecimento de uma massa pélvica de crescimento recente pode mimetizar os sintomas de uma neoplasia ginecológica. Pode observar-se também a invasão dos tecidos adjacentes como a bexiga, cego, cólon sigmóide e ureter [3].

Clinicamente, esta patologia surge de forma indolente através de sintomas inespecíficos o que pode dificultar e atrasar o diagnóstico. A sua confirmação obriga a exame histológico, por biópsia ou pós-operatório [1].

O tratamento depende da localização e da gravidade da infeção. Contudo, a antibioterapia com beta-lactâmicos é considerada a terapêutica *gold-standard*, devido à elevada eficácia na resolução desta infeção [1] [6].

Apresentamos um caso de actinomicose pélvica que demonstra como esta infecção pode mimetizar uma neoplasia ginecológica, dificultando o diagnóstico e a decisão sobre o tratamento.

Caso clínico

Mulher de 26 anos, menarca aos 13 anos, índice de massa corporal 23 kg/m^2, com ciclos regulares e que iniciou a sua vida sexual aos 18 anos, tendo tido 3 parceiros sexuais. Sete anos antes deste episódio, refere ter tido uma gravidez, tendo optado por interrupção voluntária da gravidez após a qual iniciou contracepção com dispositivo de libertação hormonal intra-uterino (Mirena) que retirou 2 anos antes de iniciar as queixas ginecológicas. Sob contracepção oral combinada nos 2 anos anteriores a esta patologia. Sem antecedentes pessoais de relevo, além de uma lesão pavimentosa intraepitelial de baixo grau (LSIL) diagnosticada há 4 anos e com regressão espontânea. Sem história familiar de neoplasia ginecológica.

Três meses antes da primeira consulta hospitalar, a doente iniciou um quadro de algia pélvica, localizada no hipogastro e com irradiação para a região lombar. Referia perda de peso (18kg em 7 meses) e febre com predomínio noturno e sudação. Foi observada, inicialmente, nos cuidados de saúde primários. Realizou ecografia pélvica que revelou formação anexial direita, quística e multi-septada com cerca de 47mm de maior diâmetro, sem outras alterações relevantes. Posteriormente, realizou ressonância magnética (RM) pélvica com contraste de gadolínio tendo-se identificado lesão

na área anexial direita, com cerca de 65x40x60mm, evidenciando componente misto e sólido, de limites imprecisos e aspeto infiltrativo, estendendo-se aos vasos obturadores e parede pélvica e envolvendo o ureter distal direito (ureter-hidronefrose homolateral). Não se identificou plano de clivagem com ovário homolateral nem vertente direita do útero.

Perante estes achados suspeitos - massa anexial direita de crescimento recente - a doente foi referenciada à consulta hospitalar de ginecologia oncológica. À observação do abdómen identificou-se uma massa pélvica volumosa e existia dor à palpação profunda dos quadrantes abdominais inferiores, mas sem reação peritoneal; o exame ginecológico revelou uma massa de consistência dura no fundo de saco posterior, dolorosa, de limites difíceis de definir.

Da investigação então realizada destaca-se:

- Avaliação analítica sem alterações relevantes (hemoglobina 11,3g/dl (12,0g/dl-15,3g/dl), leucócitos 7,9x10^9/L (4,0x10^9/L-11,0x10^9/L), plaquetas 532x10^9/L (150x10^9/L-450x10^9/L), creatinina 0,79 mg/dL (0,50-0,90 mg/dL), sódio 141 mmol/L (135-145mmol/L), potássio 4,7 (3,5-5,1mmol/L); CEA, alfa fetoproteína, CA 19.9, CA 125, CA 25-3, SCC negativos, hCG negativa);
- Citologia cervical e genotipagem HPV negativas;
- Ecografia pélvica (um mês após a ecografia inicial) confirmou a existência de formação predominantemente sólida na área anexial direita com 64x59x60 mm, vascularização moderada, central e periférica, sem vasos irregulares, que estava em continuidade com a parede lateral do útero (classificação IOTA - não classificável), não se observando ovário direito; ovário esquerdo normodimensionado aderente ao útero, e rim direito com dilatação pielocalicial;

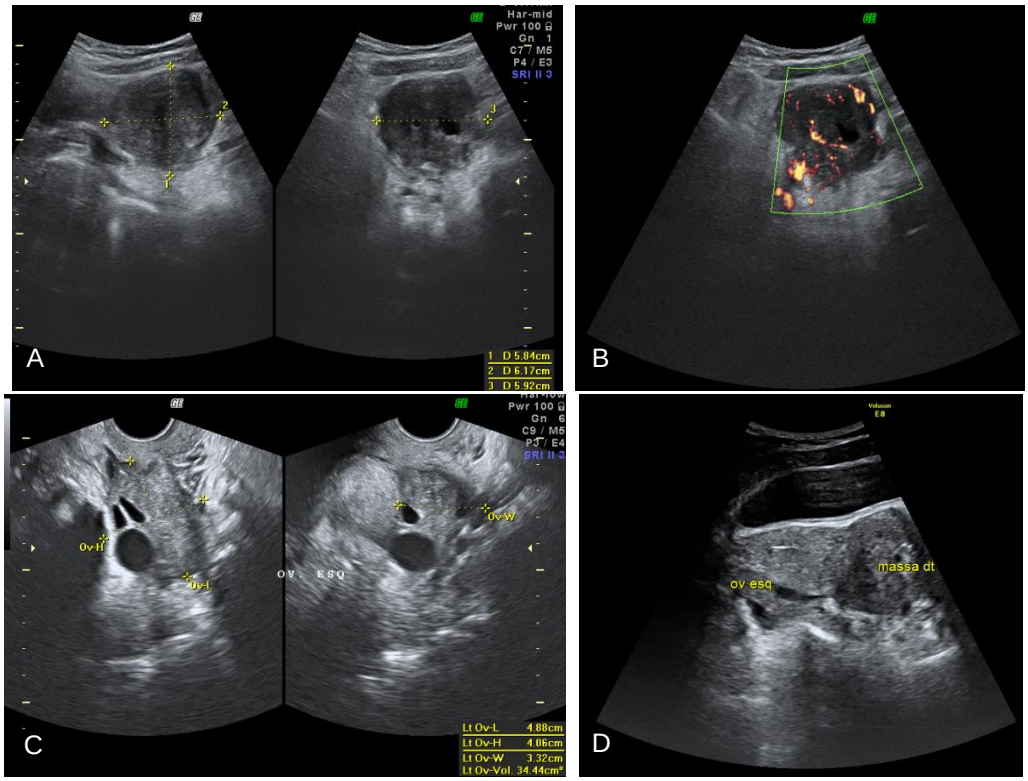

Figura 5 - Ecografia pélvica – A) formação anexial direita 64x59x60mm; B) vascularização moderada, central e periférica, sem vasos irregulares; C) ovário esquerdo normodimensionado; D) formação anexial direita e ovário esquerdo aderente ao útero

- TC toraco-abdomino-pélvica (4 semanas após a ecografia descrita acima) evidenciou massa anexial direita (6,5x5,7x5cm) de natureza mista, mas predominantemente sólida, heterogénea, sem planos de clivagem com útero, bexiga, sigmóide, vasos ilíacos externos e ligeira uretero-hidronefrose homolateral e massa anexial esquerda sólida ovalar (4x3,7x3,2cm); adenopatia lateroaórtica esquerda (14mm), pequenas adenopatias iliopélvicas bilaterais, ascite de pequeno volume;
- RM pélvica (5 semanas após a ecografia descrita acima) confirmou as volumosas massas sólidas (7x5x4,5cm à direita e 5,5x4,5x4cm à esquerda) com seguro ponto de partida anexial bilateral associando muito provável componente tubário e com características de agressividade nomeadamente pela sua estrutura, restrição à difusão e características invasivas das estruturas adjacentes (colo e corpo do útero, reto, sigmóide, parede pélvica à direita);

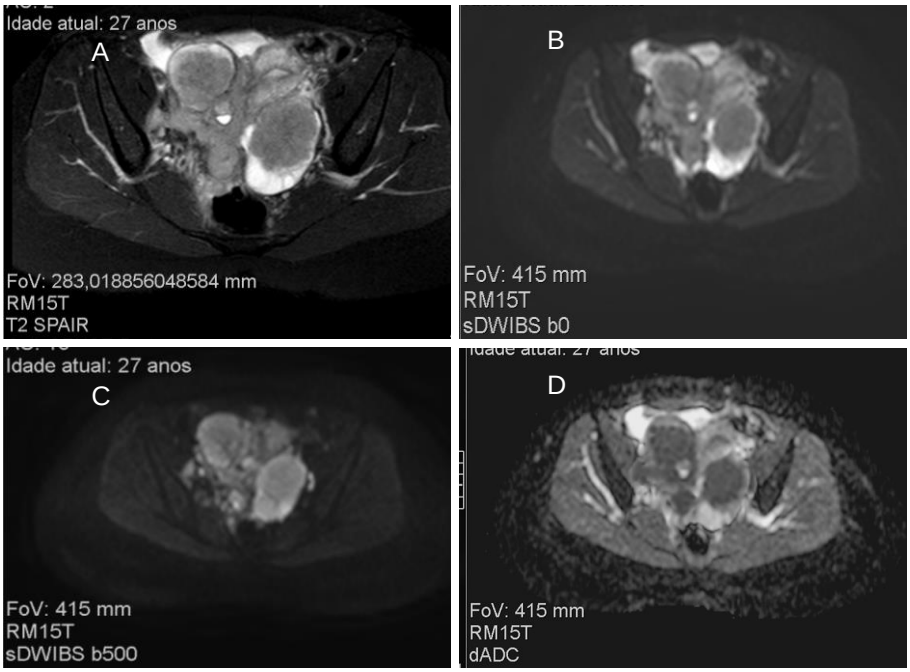

Figura 2 – Ressonância magnética pelvica – A) massas sólidas com ponto de partida anexial associado a componente tubário, desviando útero para a direita e esquerda; B,C, D) massas sólidas com restrição à difusão

- Cistoscopia realizada em ambulatório não revelou alterações.

Ao longo do tempo em que foram efectuados os exames, houve um progressivo agravamento da dor pélvica, difícil de controlar com analgesia múltipla e que interferia com a qualidade de vida da doente.

Face à elevada suspeita de se tratar de patologia neoplásica maligna, realizou-se uma biópsia guiada por TC que revelou infiltrado linfoplasmocítico, neutrófilos, tecido de granulação e uma colónia sugestiva de *Actinomyces,* não havendo evidência histológica de tecido neoplásico.

Perante o diagnóstico de abcesso tubo-ovário por actinomicose pélvica, a doente foi referenciada à consulta de Infecciologia tendo iniciado amoxicilina oral 1gr 6/6h, com indicação para

manter durante 1 ano. Ao sexto dia de antibioterapia, a doente iniciou quadro de vómitos incoercíveis. Analiticamente, apresentava hemoglobina de 6,3g/dl (12,0g/dl-15,3g/dl), leucócitos 16,96x10^9/L (4,0x10^9/L-11,0x10^9/L), plaquetas 852x10^9/L (150x10^9/L-450x10^9/L), creatinina 1,78 mg/dL (0,50-0,90mg/dL), potássio 5,5 mmol/L (3,5-5,1 mmol/L), PCR 11,1 mg/dL (<0,5mg/dL), ferro 15,5ug/dL (33-193ug/dL), capacidade total de fixação do ferro 180ug/dL (250-450ug/dL), saturação da transferrina 9% (20-40%), ferritina 1141ug/L (13-150ug/L), vitamina B12 1972 pg/mL (195-770pg/mL), folatos 2,8 ng/ml (4,6-18,7ng/ml), LDH 176 U/L (100-250U/L). Optou-se por internamento no serviço de ginecologia por intolerância à terapêutica por via oral. Foi medicada com penicilina 400000UI endovenosa (ev) 4/4h e clindamicina 900 mg ev 8/8h durante 14 dias, e efectuou-se transfusão de 2 UCE. Durante o internamento, observou-se uma melhoria clínica e laboratorial, tendo tido alta ao fim de 14 dias, medicada com amoxicilina 1gr 6/6h e ácido fólico 10mg por dia.

Cumpriu um ano de terapêutica, sem intercorrências. Do ponto de vista imagiológico, 5 meses após o início da antibioterapia, a ecografia pélvica mostrou uma regressão das lesões anteriormente descritas, com ovários de dimensões normais fixos ao útero; a RM pélvica revelou regressão parcial do processo tubo-ovárico, sem delimitação de verdadeiras coleções e ureteres de normal calibre em toda a sua extensão.

No final do ano de terapêutica, a doente apresentava-se assintomática, sem alterações analíticas nem imagiológicas, e ficou em vigilância.

Discussão

A actinomicose é uma doença rara e de difícil diagnóstico. A forma mais comum é a cervico-facial, no contexto de intervenções dentárias ou trauma. Apresentações torácicas e abdominais são também comuns [2]. O papel da imunossupressão ainda não está totalmente esclarecido e a maioria dos casos descritos surgem em indivíduos imunocompetentes [6]. Nos últimos anos, observou-se um aumento da incidência de actinomicose pélvica no sexo feminino, associado à utilização de dispositivos intra-uterinos (DIU) [7]. Contudo, ainda se desconhece qual o tipo de DIU (cobre ou hormonal) que condiciona maior risco de desenvolver esta patologia. Um dos mecanismos etiológicos invocados refere que este tipo de contraceção pode levar à destruição da mucosa, favorecendo a infecção por *actinomyces* [8]. Apesar desta associação, a duração de utilização de DIU e o risco de desenvolver actinomicose pélvica ainda não está estabelecido [9]. No presente caso, o aparecimento desta infeção surgiu numa jovem saudável, imunocompetente que tinha retirado o DIU há cerca de 2 anos, o que sugere a necessidade da existência de outros fatores que contribuam para esta doença.

Tal como observado neste caso, trata-se de uma patologia de desenvolvimento indolente, com sinais e sintomas inespecíficos, o que atrasa o diagnóstico atempado [1]. A massa abdomino-pélvica de crescimento recente, a dor, a perda de peso e a febre estão descritos como os sintomas mais frequentes desta entidade [3]. A apresentação clínica inespecífica e os exames de imagem que sugerem massa com sinais de malignidade dificultam o diagnóstico correto, sugerindo como principal hipótese de diagnóstico uma neoplasia ginecológica invasiva.

O diagnóstico definitivo é, habitualmente, após exame histológico e bacteriológico da peça [2]. Na nossa doente, a realização de biópsia tornou-se uma mais valia pois permitiu o diagnóstico. Tendo em conta o potencial maligno das massas descritas nos exames de imagem, a anexectomia bilateral iria ser a proposta cirúrgica, limitando precocemente o potencial de fertilidade da doente.

Após a confirmação de actinomicose, o tratamento preconizado é a antibioterapia. Na ausência de um consenso, atualmente opta-se por uma abordagem individualizada, de acordo com a localização e extensão da doença. A experiência clínica tem mostrado que a actinomicose pélvica pode ser curada com elevadas doses de antibióticos beta-lactâmicos, nomeadamente penicilina durante 6 a 12 meses [10]. A cirurgia deverá ser reservada, para os casos em que não há uma boa resposta à antibioterapia [10]. Nesta doente, o tratamento inicial com elevadas doses de penicilina endovenosa durante 14 dias seguida de amoxicilina oral durante um ano foi eficaz na cura da infeção, com resolução morfológica quase total ao fim de 5 meses de terapêutica.

Conclusão

A actinomicose pélvica é uma infeção rara e um desafio diagnóstico, mas facilmente tratável e com excelente prognóstico. O diagnóstico precoce bem como o tratamento correto são essenciais, para evitar intervenções desnecessárias e reduzir a morbilidade e a raríssima mortalidade associadas.

Referências

1. Dhillon AK, Fairlie, N, Finch G. Pelvic Actinomyces israelii abscess: A differential diagnosis of a pelvic mass. *BMJ Case Reports 2015;* 2015: 3-6.
2. Pusiol T, Morichetti D, Pedrazzani C, Ricci F. Abdominal-Pelvic Actinomycosis Mimicking Malignant Neoplasm. *Infectious diiseases in Obstetrics and Gynecology 2011*; 2011:747059.
3. García-García A, Ramírez-Durán N, Sandoval-Trujillo H, Romero-Figueroa MDS. Pelvic Actinomycosis. *Canadian Journal of Infectious Diseases and Medical Microbiology 2017*; 2017:9428650.
4. Khodavaisy S, Zibafar E, Hashemi SJ, Narenji H, Daie Ghazvini R. Actinomycosis in Iran: Short narrative Review article. *Iranian Journal of Public Health 2014*; 43(5): 556-60.
5. Simsek A, Perek A, Cakcak IE, Durgun AV. Pelvic actinomycosis presenting as a malignant pelvic mass: A case report. *Journal of Medical Case Reports 2011*; 5(1): 40.
6. Bonnefond S, Catroux M, Melenotte C, et al. Clinical features of actinomycosis: A retrospective, multicenter study of 28 cases of miscellaneous presentations. *Medicine 2016*; 95(24): e3923.
7. Galata CL, Vogelmann R, Gaiser T, Post S, Horisberger K. Abdominopelvic actinomycosis in three different locations with invasion of the abdominal wall and ureteric obstruction: An uncommon presentation. *International Journal of Surgery Case Reports 2015*; 12: 48-51.
8. Valour F, Sénéchal A, Dupieux C et al. Actinomycosis: Etiology, clinical features, diagnosis, treatment, and management. *Infection and drug resistance 2014;* 7: 183-97.
9. [Choi M, Beak J, Lee J, Park S, Lee W. Clinical Features of Abdominopelvic Actinomycosis: Report of Twenty Cases and Literature Review. *Yonsei Medical Journal 2009;* 50 (4): 555-559.
10. Wong VK, Turmezei TD, Weston VC. Actinomycosis. *Bmj 2011*; 343(3):d6099.

Cutaneous Angiosarcoma

Angiosarcoma cutâneo

Maria Mendonça Sanches, Ana Marcos Pinto, Luís Soares-de-Almeida, Paulo Leal Filipe, João Pedro Freitas
Clínica Universitária de Dermatologia, Hospital de Santa Maria, Centro Hospitalar Universitário Lisboa Norte, Lisboa, Portugal

Abstract

Cutaneous angiosarcoma is a highly malignant vascular tumour with a poor prognosis. It is commonly seen in elderly man in the face, scalp, at sites of previous radiation therapy or lymphoedematous regions. It commonly presents as an asymptomatic, sporadic, bluish-red multifocal papule on the scalp, which may eventually penetrate to deeper tissue and ulcerate. Treatment is challenging since it relies on small retrospective case series with no randomised trials.

Keywords: Angiosarcoma, scalp, chemotherapy, radiotherapy

Resumo

O angiosarcoma cutâneo é um tumor vascular com elevado grau de malignidade e um prognóstico bastante reservado. Afeta mais frequentemente doentes idosos do género masculino e tem predileção para envolver a face, couro cabeludo e regiões de linfedema crónico ou já submetidas a radioterapia. As lesões cutâneas são tipicamente assintomáticas e apresentam-se como pápulas eritemato-violáceas com potencial de envolvimento dos tecidos profundos e de ulceração. O tratamento é difícil e baseado em pequenas series de doentes, não existindo estudos randomizados.

Palavras-chave: Angiosarcoma, escalpe, quimioterapia, radioterapia

Introduction

Angiosarcomas are rare soft-tissue sarcomas of endothelial cell origin that have a poor prognosis. They may appear anywhere in the body but commonly involve the head and neck regions, particularly the scalp [1,2].

Although there are several well-described risk factors, such as chronic lymphoedema, most angiosarcomas arise spontaneously [1].

Treatment is challenging since most published reports rely on retrospective case series with no randomised trials and few prospective studies [1]. Radical surgery with complete resection and adjuvant radiotherapy is the primary treatment of choice in localized disease due to the high risk of recurrence. In metastatic disease cytotoxic chemotherapy remains the standard treatment [1,3,4].

Case Report

We present a case of a 63-year-old male admitted to our outpatient clinic due to a painful, exophytic, indurated tumour mass (7x5cm) on the right frontoparietal region with central ulceration and a progressive growth over the past four months. The patient denied fever, other constitutional symptoms or a previous history of trauma/inoculation or insect bite. He had been previously evaluated by his general practitioner and treated with oral antibiotics, without clinical improvement. The remaining clinical and laboratory evaluation was unremarkable.

On histopathological examination (figure 2A) vascular sinusoids formed by abnormal endothelial cells dissecting between collagen bundles was seen. Immunohistochemistry (figure 2B) was positive for CD31 and podoplanin and negative for HHV-8, S100, AE1/AE, supporting the diagnosis of angiosarcoma. A Magnetic Resonance brain imaging showed no bone involvement. The Chest-Computed Tomography revealed multiple cystic lesions on both lungs and a Positron Emission Tomography was compatible with metastatic lung disease.

Due to the presence of metastatic lung disease and local hemorrhage, the patient initially started radiotherapy with a favorable hemostatic control and is now initiating chemotherapy with liposomal doxorubicin.

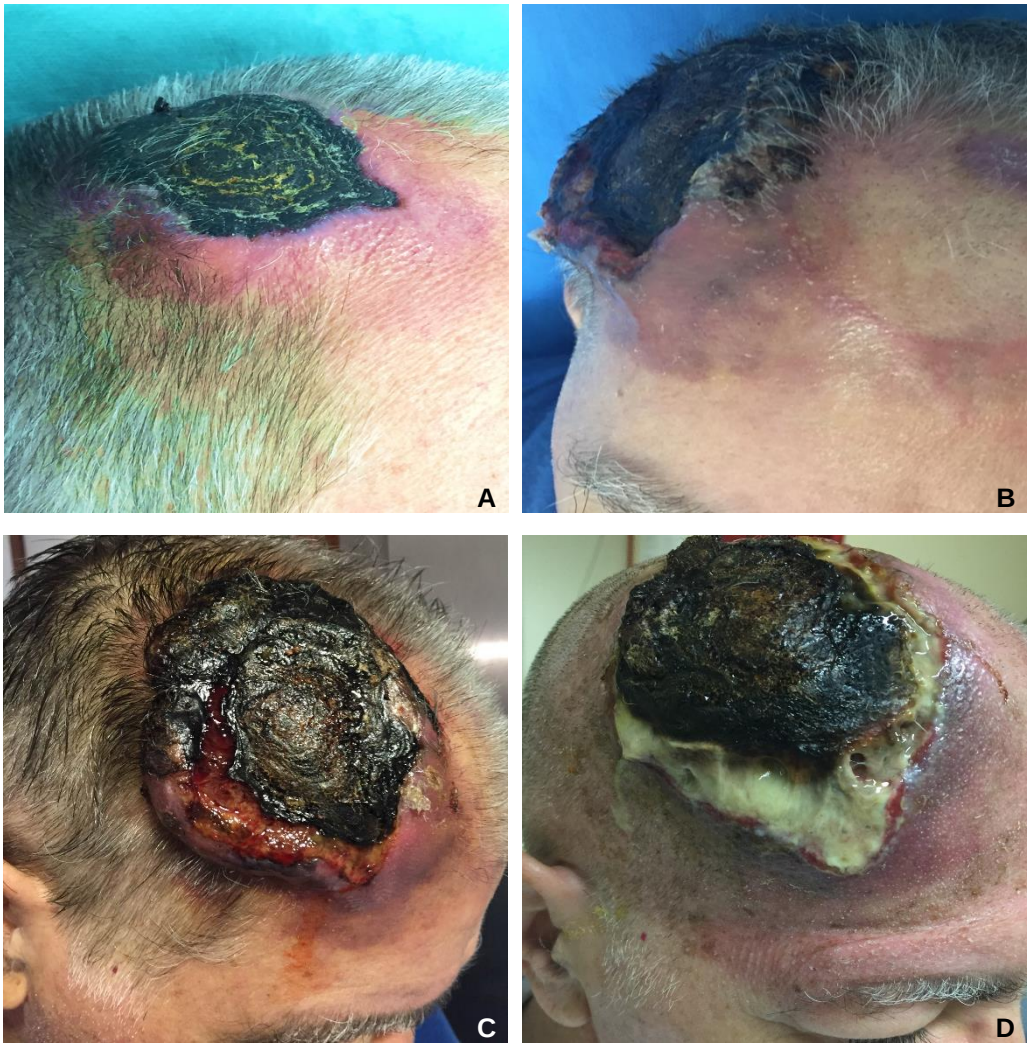

Figure 1. *Clinical progression over 3 months (A-C) and one month after radiotherapy (D).*

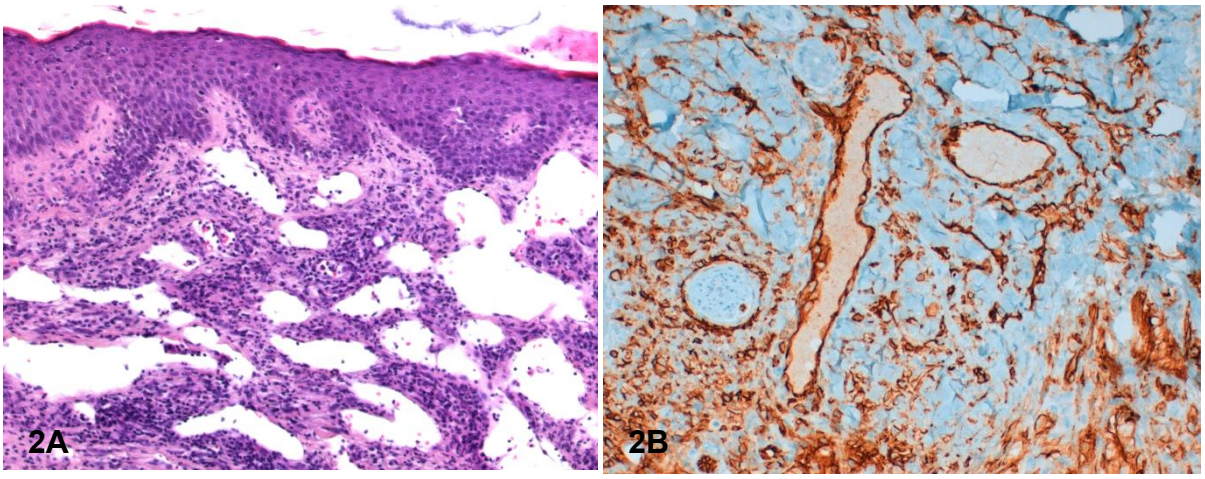

Figure 2. *2A- Histological examination (H&E, 40x); 2B-Immunohistochemistry (CD31)*

Conclusion

Cutaneous angiosarcoma has an aggressive natural history with a high rate of local and/or distant recurrences. As such, most patients ultimately die due to disseminated disease [1,3].

Although treatment is challenging the knowledge of angiosarcomas' molecular biology with the aim to identify specific targets for treatment is under continuous update and trials of vascular-targeted drugs seem promising [1,5].

References

1. Young RJ, Brown NJ, Reed MW, Hughes D, Woll PJ. Angiosarcoma. Lancet Oncol. 2010;11(10):983-91.
2. Kong YL, Subash Chandran SN, Goh SG, Ng SK. Cutaneous angiosarcoma of the scalp mimicking a keratoacanthoma. Dermatolo Online J 2013;19(6):18566.
3. Dossett LA, Harrington M, Cruse CW, Gonzalez RJ. Cutaneous angiosarcoma. Curr Probl Cancer. 2015;39(4):258-63.
4. Pawlik TM, Paulino AF, McGinn CJ, et al. Cutaneous angiosarcoma of the scalp: a multidisciplinary approach. Cancer 2003; 98: 1716-26.
5. Mocellin S, Rossi CR, Brandes A, Nitti D. Adult soft tissue sarcomas: conventional therapies and molecularly targeted approaches. Cancer Treat Rev 2006; 32: 9-27.

Double Trouble in the OR: Lown-Ganong-Levine and long QT syndromes

Double Trouble no bloco operatório: Sindrome Lown-Ganong-Levine e QT longo

D. Guerreiro[1], S. Maurício[2], J.R. Soares[3], I. Rodrigues[1]

[1] Serviço de Anestesiologia, Centro Hospitalar Lisboa Norte; [2] Serviço de Anestesiologia, Instituto Português de Oncologia de Lisboa Francisco Gentil; [3] Serviço de Anestesiologia, Centro Hospitalar Universitário do Algarve

Abstract

Lown-Ganong-Levine (LGL) is a rare pre-excitation syndrome with a higher incidence of paroxysmal supraventricular tachycardia. On the other hand, long QT syndrome (LQT) is a conduction disorder characterized by prolongation and dispersion of ventricular repolarization. Both syndromes bear a risk of perioperative arrhythmias, with the former potentially increasing the risk of malignant arrhythmias associated with the latter. Besides, antiarrhythmics and drugs commonly used in anesthesia might prolong the QT. Given the lack of evidence on the management of these patients, we report a case of a 48-year-old woman, diagnosed with both syndromes during the preoperative evaluation, proposed for a partial parotidectomy for a Warthin tumor.

Keywords: Anaesthesia, Lown-Ganong-Levine, long QT syndrome

Resumo

A síndrome de Lown-Ganong-Levine é uma condição rara, associada a taquicardia supraventricular paroxística. Por outro lado, a síndrome de QT longo é um distúrbio de condução caracterizado por prolongamento e dispersão da repolarização ventricular. Ambas as síndromes acarretam o risco de arritmias peri-operatórias, sendo que a primeira pode aumentar o risco de arritmias malignas associadas à segunda. Além disso, anti-arrítmicos e fármacos anestésicos comuns podem prolongar o intervalo QT. Dada a escassez de evidência sobre a abordagem destes doentes, reportamos o caso de uma mulher de 48 anos, com ambos os diagnósticos na avaliação pré-operatória, proposta para parotidectomia parcial por tumor de Warthin.

Palavras-Chaves: Anestesia, Sindrome Lown-Ganong-Levine, Síndrome QT longo

Introduction

Lown-Ganong-Levine (LGL) is a rare pre-excitation syndrome with a higher incidence of paroxysmal supraventricular tachycardia. The ECG pattern includes a PR interval <0.12s and a normal QRS complex (Image 1). Although the structural abnormality responsible for the premature

but normal ventricular activation has not been identified yet, enhanced AV nodal conduction and a perinodal accessory pathway (James bundle) have been implicated [1, 2].

On the other hand, long QT syndrome (LQT) is a conduction disorder characterized by prolongation and dispersion of ventricular repolarization (Figure 2). Patients with QTc >0.43s (men) / >0.45s (women) are susceptible to ventricular arrhythmias, namely Torsades de Pointes [3].

Lown-Ganong-Levine	**Long QT syndrome (LQT)**
Figure 1	*Figure 2*
PR interval < 0.12s Absence of delta wave QRS < 0.12s with normal morphology Clinical paroxysmal tachycardia	Bazett formula: $QTc = \frac{QT}{\sqrt{RR}}$ Normal: QTc < 0.45s for women, < 0.43s for men

The priority in the anesthesic management is the appropriate selection of anesthetic agents, avoidance of arrhythmogenic triggers, and the maintenance of a normohemodynamic state with proper electrocardiographic monitoring, in order to ensure an uneventful perioperative course. The avoidance of arrhythmogenic triggers plays a major role in the management of patients with QTL, since some anesthetic agents are associated with additional QT *prolongation*, increasing the risk of fatal arrhythmias. The most frequent triggers in the anaesthesia care are listed below (Table 1) [3, 4].

Table 1: Risk factors for LQT associated with torsade de Points (for a more exhaustive list visit http://www.sads.org.uk/drugs-to-avoid/) [3, 4]

Non pharmacological factors	Abrupt haemodynamic changes, simpatic stimulus, pain Hypoxia, hypocapnia, hypercapnia Hipocalemia, hipomagnesemia, hipocalcemia Hipotermia, hipoglicemia, hypothyroidism Myocardial ischaemia and infarction, subarachnoid Hemorrhage
Induction agents	Ketamine, Sodium *thiopental**
Volatile agents	Sevofluorane *, Desflurane
Muscle relaxants	Suxamethonium*, Pancuronium*
Antiemetics	Droperidol, Ondansetron
Antiarrhythmics	*Flecainide*, *Propafenone*, Sotalol, *Amiodarone*
Anticholinergic drugs and cholinesterase inhibitor	*Atropine, Glycopyrrolate*, *Neostigmine*
Vasoconstrictors and *inotropic* agents	*Epinephrine, Dobutamine*, *Dopamine*, *Ephedrine*, *Phenylephrine, Isoprenaline*, *Noradrenaline*
Others	*Haloperidol*, *Methadone*, *Oxytocin*, Salbutamol

* Low Arritmogenic risk

Case Report

A 48-year old female, ASA II, was proposed for a Warthin tumor surgery. The patient had no previous history of medical problems besides a history of recurrent palpitations erroneously attributed to anxiety, no history of previous surgical procedures and displayed a good general status. She was taking no medication and had no familial history of sudden death.

Her preoperative 12-lead ECG (Figure 3) revealed a sinus rhythm, heart rate 93bpm, PR interval 0.1s, QRS duration <0.12s with normal morphology and a QTc interval 0.46s, and a LGL and LQT diagnosis was proposed. The remainder evaluation, including cardiac and metabolic workup, was unremarkable.

Considering the scarcity of LGL reported cases and conflicting data on LQT management, we tried to identify the most innocuous anesthetic agentes and avoided the possible triggers for arrhythmias.

On the day of the surgery, the patient was premedicated with Midazolam in order to decrease preoperative anxiety. The clinical monitoring followed the recommendation of the American Society of Anesthesiologists and included hemodynamic monitoring (ECG and noninvasive blood pressure measurement), oximetry, capnography and noninvasive temperature monitoring. The adequate anesthetic depth was ensured using bispectral index.

She underwent partial parotidectomy under propofol and remifentanil target-controlled infusions. We chose this strategy since it provides an adequate anesthetic depth and analgesia, avoiding the potential further prolongation of QT associated with inhalational agentes; furthermore, propofol *is* associated with a low incidence of postoperative nausea and vomiting and it is considered a safe choice in WPW syndrome. *The use of remifentanil offers* some additional *advantages* since it *provides an adequate* intraoperative *analgesia and blunts the* autonomic responses to noxious stimulus. Even though the role of sympathetic stimulation is controversial in acquired QTL, it promotes impulse generation, which accessory pathways can propagate far better than AV node, making AV reentrant tachycardias more likely.

Routine direct laryngoscopy and tracheal intubation were performed after administering a non-depolarizing muscle relaxant (rocuronium 0,6 mg/kg) and lidocaine (1,5 ml/kg). During the procedure no electrolyte and acid-base disturbances occurred and we assured the maintenance of normocapnia, normothermia and normovolemia. Considering the risk of torsade de pointes and other arrhythmias, magnesium sulphate and an external defibrillator were available.

Since nausea and vomiting is one of the most common complications after general anaesthesia and the patient had several risk factors for their occurrence (female, non-smoker and use of opioids), dexamethasone was chosen for prophylaxis, because droperidol and ondansetron are associated with prolonged repolarization.

In order to ensure adequate levels of postoperative analgesia and a smooth recovery, a cervical superficial plexus block with 10ml of Ropicavaine 0,75% was performed before emergence considering the length of surgical incision.

Another priority at the end of the surgery is the effective reversal of the neuromuscular block. The use of an anticholinesterase, like neostigmine, is effective but not ideal in patients with LQT. Their use is additionally limited by the need of the concomitant administration of a antimuscarinic

drug like atropine, to avoid the muscarinic side-effects. A safe and adequate reversal might be achieved with sugammadex, a novel cyclodextrin analogue that does not interfere with the ventricular repolarization.

No arrhythmias were documented in intraoperative 5-lead ECG and the patient's recovery progressed without complications. The postoperative analgesia was supplemented with paracetamol.

Discussion

Despite the scarcity of LGL cases and conflicting data on LQT, some general principles must be followed: [1-4]

- Chronic beta-blockers maintained
- Magnesium sulphate and external defibrillator available
- 5-lead ECG, consider A-line
- Adequate anxiolysis, anesthetic depth and analgesia
- Normo -capnia, -temperature, -volemia and electrolytes
- Avoid drugs prolonging QT, although rarely proarrhythmic (droperidol, ondansetron, inhalational agents, etc.)
- Avoid sympathetic stimulation
- Avoid amiodarone when treating tachycardia (it prolongs QT interval, and depresses AV conduction, enhancing accessory pathways)

Conclusion

Appropriate selection of anesthetic drugs and avoidance of arrhythmogenic triggers ensure an uneventful perioperative course in these cases. Total intravenous anesthesia is safe in patients with LGL and LQT. Finally, nerve blocks avoid opioid rescue along with its side effects and antiemetic drugs known to prolong QT.

Cardiology consultation, multidisciplinary evaluation and development of a protocol for long QT patients were critical to support decision making and perhaps the management of future cases.

References

1. Podrid P. Lown-Ganong-Levine syndrome and enhanced atrioventricular nodal conduction. UpToDate, 2017.
2. Sharma M. Anaesthetic management of a patient with Lown Ganong Levine syndrome. MJAFI 2011; 67: 285-287.
3. Kies S. Anesthesia for patients with congenital long QT syndrome. Anesthesiology. 2005 Jan; 102(1): 204-10.
4. Staikou C. Perioperative management of hereditary arrhythmogenic syndromes. Br J Anaesth, 2012 May; 108(5): 730-44.

Alergia ao ácido clavulânico

Clavulanic acid allergy

Tatiana Lourenço[1], Mara Fernandes[1,2], Anabela Lopes[1], Manuel Pereira Barbosa[1,3]

[1]Serviço de Imunoalergologia, Hospital de Santa Maria, Centro Hospitalar Lisboa Norte (CHLN) EPE, Lisboa; [2]Unidade de Imunoalergologia, Hospital Dr. Nélio Mendonça, SESARAM, EPE, Funchal; [3]Clínica Universitária de Imunoalergologia, Faculdade Medicina da Universidade de Lisboa

Resumo

Os antibióticos beta-lactâmicos são os fármacos mais frequentemente associados a reações alérgicas IgE mediadas. Inicialmente, as benzilpenicilinas eram os beta-lactâmicos mais frequentemente descritos, tendo sido gradualmente substituídas pelas aminopenicilinas, nomeadamente a amoxicilina. O ácido clavulânico é um potente inibidor de beta-lactamases cuja prescrição, em associação com amoxicilina, tem aumentado na prática médica. Um estudo espanhol revelou que cerca de 30% das reações alérgicas após toma da associação amoxicilina e ácido clavulânico são causadas pelo ácido clavulânico. Não existe evidência de reatividade cruzada entre este e outros beta-lactâmicos. É importante a realização de uma investigação imunoalergológica para determinar se se trata de uma reação seletiva ao ácido clavulânico, uma vez que estes doentes podem ser tratados com outros beta-lactâmicos, nomeadamente a amoxicilina. Os autores descrevem um caso clínico de uma reação tardia ao ácido clavulânico em que a utilização da molécula isolada de ácido clavulânico foi essencial para o diagnóstico.

Palavras-chave: Ácido clavulânico; beta-lactâmicos; hipersensibilidade tardia

Abstract

Beta-lactam antibiotics are the drugs most frequently associated with IgE mediated allergic reactions. Initially, benzylpenicillins were the most frequently described beta-lactams and were gradually replaced by aminopenicillins, namely amoxicillin. Clavulanic acid is a potent beta-lactamase inhibitor whose prescription in association with amoxicillin has increased in medical practice. A spanish study revealed that about 30% of the allergic reactions after taking the combination amoxicillin and clavulanic acid are caused by clavulanic acid. There is no evidence of cross-reactivity between this and other beta-lactams. An immunoallergic investigation is important to determine whether it is a selective clavulanic acid reaction, since these patients may be treated with other beta-lactams, namely amoxicillin. The authors describe a clinical case of a late reaction to clavulanic acid in which the use of the isolated clavulanic acid molecule was essential for diagnosis.

Keywords: Clavulanic acid; beta-lactams; late hypersensitivity

Introdução

Os beta-lactâmicos são antibióticos frequentemente prescritos no tratamento e prevenção de processos infeciosos [1]. Contudo, estes também são os fármacos mais comumente associados a reações de hipersensibilidade mediadas por um mecanismo imunológico específico [2]. Estas reações podem ser classificadas em imediatas ou tardias (não-imediatas). As reações imediatas normalmente ocorrem nas primeiras horas após a toma e resultam de um mecanismo IgE mediado, enquanto as reações tardias ocorrem tipicamente várias horas ou até mesmo dias após a toma do fármaco e estão associadas a mecanismos mediados por células T [3].

Apesar de qualquer fármaco poder ser responsável por uma reação alérgica, existem fármacos que são mais frequentemente associados do que outros. Esta maior prevalência está diretamente associada ao padrão de consumo dos fármacos e tem variado ao longo do tempo e entre países [2]. Inicialmente, as benzilpenicilinas eram os fármacos mais frequentemente descritos como causadores de reações de alergia medicamentosa, tendo sido gradualmente substituídas pela amoxicilina. Atualmente, devido ao aumento das resistências bacterianas, a amoxicilina é prescrita frequentemente em associação com o ácido clavulânico, inibidor de beta lactamases [2].

Estudos iniciais consideravam que o ácido clavulânico tinha uma fraca imunogenicidade [4], mas têm vindo a ser descritas reações de hipersensibilidade a esta molécula. Em 1995 [5] foram descritos os primeiros dois casos clínicos de reação imediata ao ácido clavulânico. Desde então o número de casos relatados tem vindo a aumentar [6-7], sendo as reações descritas maioritamente IgE mediadas. Poucos casos de reação tardia têm sido reportados [7-8].

Os autores descrevem um caso clínico de uma reação tardia ao ácido clavulânico após a toma de amoxicilina em associação com ácido clavulânico em que a possibilidade de utilização da molécula isolada de ácido clavulânico foi essencial para o diagnóstico. Foi também possível excluir alergia à amoxicilina.

Caso clínico

Homem de 45 anos de idade, raça caucasiana, analista químico de profissão, sem antecedentes pessoais relevantes, referenciado à consulta de Imunoalergologia por aparecimento de exantema maculopapular, pruriginoso, não descamativo e generalizado ao sétimo dia de tratamento com amoxicilina em associação com ácido clavulânico e ibuprofeno por quadro clínico de faringite. Foi excluída hipersensibilidade aos anti-inflamatórios não esteróides (AINEs) mediante a realização de uma prova de provocação oral com ibuprofeno com prolongamento durante 2 dias, que foi negativa.

Para a investigação de alergia aos beta-lactâmicos foram efetuados doseamentos de IgE específicas para beta-lactâmicos, que foram negativos. Realizou-se também testes cutâneos em picada (TCP) e intradérmicos (ID) com determinantes major (PPL) e minor (MDM), e com as moléculas nativas de penicilina, amoxicilina, amoxicilina em associação com ácido clavulânico, ampicilina e cefalosporinas, que também foram negativos em leitura imediata e tardia (às 48h). Os testes epicutâneos realizados com os fármacos acima citados também foram negativos.

Efetuou-se então uma prova de provocação oral com amoxicilina em associação com ácido clavulânico com indicação inicial para prolongamento da toma durante 8 dias, que o doente cumpriu até ao quinto dia, quando iniciou quadro clínico caracterizado por exantema maculopapular, eritematoso e pruriginoso, inicialmente localizado ao tronco mas com rápida generalização (Figura1).

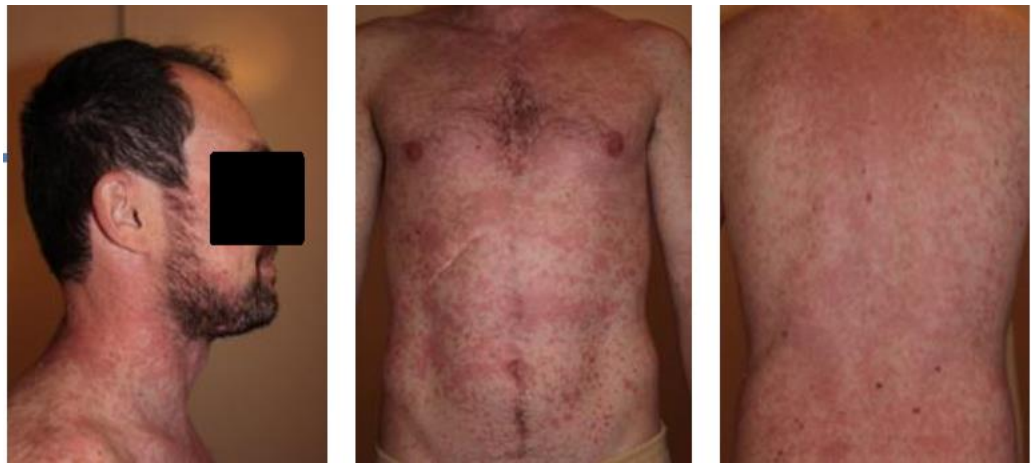

Figura 1*- Manifestações clínicas após toma de amoxicilina + ácido clavulânico (5 dias)*

Após esta reação foram executados testes ao ácido clavulânico isoladamente, em TCP e em ID com as concentrações 0,5; 5 e 20 mg/mL com leitura imediata e tardia. Observou-se positividade às 48h no ID (Figura 2) efetuado com a maior concentração (20 mg/mL) e negatividade nos restantes ID, bem como nos testes epicutâneos.

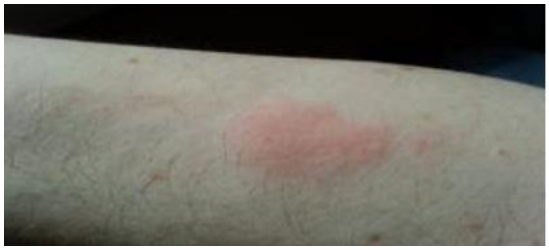

Figura 2 *– Reação às 48h de ID com ácido clavulânico (20mg/mL)*

Posteriormente foi submetido a prova de provocação oral com amoxicilina com prolongamento durante oito dias (1g de 8h/8h), que decorreu sem intercorrências. O estudo imunoalergológico aos beta-lactâmicos encontra-se resumido no Quadro 1.

Quadro 1: *Investigação imunoalergológica aos beta lactâmicos*

Reagentes	**TCP (1/1)**	**ID (1/1000;1/100;1/10)**	**sIgE (<0,35KUA/L)**	**TE**	**PP (O)**
PPL/MDM	Neg	Neg	NR/ND	NR/ND	NR/ND
Penicilina 10 000 UI/L	Neg	Neg	Neg	Neg	NR

Amoxicilina 20mg/mL	Neg	Neg	Neg	Neg	Neg
Ampicilina 20mg/mL	Neg	Neg	Neg	Neg	NR
Amox/clav 20mg/0,5mg/mL	Neg	Neg	NR/ND	Neg	**Pos** (5ºdia)
Ácido clavulânico[1]	Neg	**Pos** (20 mg/mL; 48h)	NR/ND	Neg	NR/ND

Legenda: [1] - concentrações utlizadas nos ID do ácido clavulânico:0,5; 5 e 20 mg/mL; h-horas; ID – testes cutâneos intradérmicos; MDM- determinantes major; ND – não disponível; NR – não realizado; Neg – negativo; O – oral; Pos – positivo; PP – prova de provocação; PPL – determinantes minor; sIgE – IgE específica; TCP – testes cutâneos em picada; TE – testes epicutâneos

Discussão

Atualmente, as resistências bacterianas constituem um problema grave [9]. O uso de inibidores de beta lactamases, como é o caso do ácido clavulânico, pode ajudar a controlar este problema e reforça a necessidade de estar atento à possibilidade de reação alérgica a este fármaco bem como à diferenciação entre reação à amoxicilina ou reação ao ácido clavulânico em doentes tratados com a associação amoxicilina + ácido clavulânico.

Apesar da amoxicilina e o ácido clavulânico pertencerem à mesma família de antibióticos: os beta-lactâmicos, estes dois fármacos não apresentam reações de reatividade cruzada [10], sugerindo que a reação ao ácido clavulânico é seletiva e por isso, doentes com reação seletiva ao ácido clavulânico podem ser tratados de forma segura com qualquer outro beta-lactâmicos. Este fato apresenta implicações clínicas importantes, uma vez que não é infrequente doentes com reação ao ácido clavulânico serem erradamente rotulados como alérgicos a todos os antibióticos beta-lactâmicos.

Como já foi mencionado, o número de doentes referenciados à consulta de Imunoalergologia por suspeita de reação alérgica após a toma de amoxicilina + ácido clavulânico tem vindo a aumentar. Relativamente ao diagnóstico de alergia ao ácido clavulânico, este pode ser feito através da realização de testes cutâneos (TCP e ID), sendo que o *gold-standa*rd é a prova de provocação oral [11].

Os testes cutâneos são o método diagnóstico mais utilizado, especialmente se se tratar de uma reação imediata. A suspeita de alergia ao ácido clavulânico tem sido classicamente baseada na presença de TCP e ID negativos para a amoxicilina e positivos para amoxicilina + ácido clavulânico. Contudo, estes testes são positivos em apenas 18% dos casos [6]. Este número pode ser atríbuido à baixa concentração de ácido clavulânico comparativamente com a amoxicilina na associação amoxicilina + ácido clavulânico, levando por isso a falsos negativos. O uso da molécula isolada de ácido clavulânico levou a um aumento da sensibilidade de 9 para 18,7% nos TCP e de 63,6 para 81,2% nos ID [6, 7,10]. Um estudo espanhol demonstrou que doentes com história de reação imediata a amoxicilina + ácido clavulânico apresentavam testes cutâneos positivos para ácido clavulânico em cerca de 30% dos casos [10].

Uma vez que a sensibilidade dos testes cutâneos não é ótima, em alguns casos deve ser considerada a realização de prova de provocação medicamentosa [11]. A realização da prova de provocação requer pessoal médico e de enfermagem treinados bem como um local apropriado, uma vez que existe risco de reação. Esta pode ser utilizada para confirmar alergia ou tolerância à amoxicilina diretamente [12], mas o seu uso no estudo de uma reação ao ácido clavulânico, pelo fato de este se encontrar disponível apenas em associação com a amoxicilina, implica a realização de duas provas de provocação, uma com amoxicilina e outra com a associação de amoxicilina e ácido clavulânico. Desta forma, a confirmação de alergia ou tolerância ao ácido clavulânico é feita de forma indireta.

Conclusão

Os autores descrevem um caso clínico de uma reação tardia após ~~a~~ toma de amoxicilina em associação com ácido clavulânico e demonstraram tratar-se de um caso de reação seletiva ao ácido clavulânico, através de um ID positivo para ácido clavulânico e uma prova de provocação oral negativa para a amoxicilina. O doente deve fazer evicção de ácido clavulânico, podendo realizar todos os restantes beta lactâmicos.

Referências

1. Adriaenssens N, Coenen S, Versporten A, Muller A et al. European surveillance of antimicrobial consumption (ESAC): outpatient antibiotic use in Europe (1997-2009). J Antimicrob Chemother. 2011; 66(6):3-12.
2. Dona I, Blanca-Lopez N, Torres MJ, Garcia-Campos J et al. Drug hipersensitivity reactions: response patterns, drug involved, and temporal variations in a large series of patients. J Investig Allergol Clin Immunol. 2012; 22:363-71.
3. Torres MJ, Blanca M. The complexclinical picture of beta-lactam hypersensitivity: penicilins, cephalosporins, monobactams, carbapenems, and clavams. Med Clin North Am 2010; 94:805-20.
4. Edwards RG, Dewdeney JM, Dobrzanski RJ, Lee D. Immunogenicity and allergenicity of two betalactam structures, a clavam, clavulanic acid and a carbapenem: structure activity relationship. Int Arch Allergy Appl Immunol 1988; 85:184-89
5. Fernandez-Rivas M, Perez Carral C, Cuevas M, Marti C, Moral A, Senent C J. Selective allergic reactions to clavulanic acid. J Allergy Clin Immunol 1995;95:748-50.
6. Torres MJ, Ariza A, Mayorga C, Dona I, et al. Clavulanic acid can be the component in amoxicilin-clavulanic acid responsible for immediate hypersensitivity reactions. J Allergy Clin Immunol. 2010;125:502-5.
7. Sanchez-Morillas L, Perez-Ezquerra PR, Reano-Martos M, Laguna-Martinez JJ et al. Selective allergic reactions to clavulanic acid: a report of 9 cases. J Allergy Clin Immunol 2010;126:177-9.
8. Bonadonna P, Schiappoli M, Senna G, Passalacqua G. Delayed selective reaction to clavulanic acid: a case report. J Investig Allergol Clin Immunol 2005; 15: 302-4.
9. Spellberg B, Powers JH, Brass EP, Miller LG, Edwards JE. Trends in Antimicrobial Drug Development: Implications for the Future. Clin Infect Dis 2004; 38:1279–86.
10. Blanca-Lopez N, Perez-Alzate D, Ruano F et al. Selective immediate responders to amoxicillin and clavulanic acid tolerate penicillin derivative administration after confirming the diagnosis. Allergy 2015; 70:1013–9.

11. Bousquet PJ, Pipet A, Bousquet-Rouanet L, Demoly P. Oral challenges are needed in the diagnosis of b-lactam hypersensitivity. Clin Exp Allergy 2008; 38:185–90.
12. Blanca M, Romano A, Torres MJ et al. Update on the evaluation of hypersensitivity reactions to betalactams. Allergy 2009; 64:183–93.

Rhinoentomophthoramycosis

Conídiobolomicose Rino-Facial

Raquel Bento[1], Catarina Duarte[1], Vitor Oliveira[1], Tiago Marques[2], Ana Rita Santos[1], Leonor Fernandes[3], Rosa Roque Farinha[1], Leonel Luis[1]

1. Serviço de Otorrinolaringologia, Hospital de Santa Maria, Centro Hospitalar Universitário Lisboa Norte; 2. Serviço de Doenças Infecciosas, Hospital de Santa Maria, Centro Hospitalar Universitário Lisboa Norte; 3. Serviço de Imagiologia, Hospital de Santa Maria, Centro Hospitalar Universitário Lisboa Norte

Abstract

Rhinoentomophthoramycosis is a rare subcutaneous mycosis caused by *Conidiobolus coronatus*. It affects predominantly immunocompetent men in tropical countries. The infection of the nose and face soft tissues causes a characteristic painless midface swelling. Although rare, it may spread or have a locally invasive behaviour. An early and accurate diagnosis is essential to achieve better outcomes.

The authors report the case of a 24-year-old men from Guinea-Bissau, presenting with a seven months grotesque painless facial swelling. The imaging study showed no bone erosion. Histopathological examination revealed multiple inflammatory cells granulomas with eosinophils prevalence. Cultures were negative. Oral itraconazole lead to clinical improvement with marked reduction of the swelling.

Key-words*:* Rhinoentomophthoramycosis, Granuloma, Rhino-facial

Resumo

A conidiobolomicose rino-facial é uma micose subcutânea rara causada pelo *Conidiobolus coronatus* que afeta predominantemente homens imunocompetentes em países tropicais. Trata-se, na maioria dos casos, de uma infeção crónica indolente dos tecidos moles, que afeta caracteristicamente o terço médio da face, ainda que, nas formas atípicas possa disseminar ou ser localmente invasiva. O diagnóstico precoce e correto é essencial para uma evolução clínica favorável.

Os autores apresentam o caso clínico de um jovem de 24 anos, natural e residente na Guiné-Bissau, com uma tumefação indolor generalizada do terço médio e inferior da face, com 7 meses de evoluçãoo. O estudo imagiológico revelou ausência de erosão óssea. O exame histopatológico mostrou um intenso infiltrado inflamatório com a formação de granulomas e predomínio de eosinófilos, com culturas negativas. A terapêutica antifúngica com itraconazol, levou a uma melhoria clínica, com redução significativa da tumefacção fa-cial.

Palavras-chave*:* Conidiobolomicose, granuloma, rino-facial

Introdução

A conídiobolomicose é uma micose subcutânea rara causada pelo fungo saprófita *Conidiobolus coronatus* que afeta predominantemente os indivíduos do sexo masculino em regiões tropicais e áridas [1].

Trata-se, na maioria dos casos, de uma infeção crónica indolente dos tecidos moles, que afeta caracteristicamente o terço médio da face, ainda que, nas formas atípicas possa disseminar ou ser localmente invasiva [2,3].

A infecção inicia-se com a fixação dos esporos do *C. coronatus* à mucosa nasal, seja por inalação ou por trauma, causando sintomas nasais inespecíficos, mimetizando uma sinusite. O aparecimento de um nódulo na parede lateral da pirâmide nasal indica a invasão dos tecidos subcutâneos e a disseminação progressiva para os tecidos moles da pirâmide nasal, pálpebras e lábio superior, causa um edema firme e indolor do terço médio da face, característico desta patologia. Ainda que raro, pode ocorrer ulceração da pele e mucosas, assim como dispneia, por envolvimento faríngeo e laríngeo [4].

O diagnóstico é um verdadeiro desafio, não só por se tratar de uma patologia rara (mesmo nos países tropicais), mas sobretudo porque outros diagnósticos mais frequentes, como *lupus vulgaris*, lepra, ou leishmaniose cutânea - nos países tropicais-, ou neoplasias ou doenças granulomatosas - nos países não tropicais- são considerados inicialmente [5].

O diagnóstico precoce e correto é essencial para uma evolução clínica favorável.

Neste artigo, destacamos esta patologia como diagnóstico diferencial nas tumefações indolores rino-faciais, enfatizando a importância de uma abordagem multidisciplinar não só para o diagnóstico, mas também para o tratamento desta patologia.

Caso clínico

Doente do sexo masculino, de 24 anos, natural e residente na Guiné-Bissau, recorre ao Serviço de Urgência de Otorrinolaringologia apresentando uma tumefacção indolor generalizada do terço médio e inferior da face, com cerca de 7 meses de evolução. Adicionalmente, apresentava queixas de obstrução nasal crónica e rinorreia mucosa, persistentes, com meses de duração. Negava odinofagia ou disfagia, disfonia, diplopia, dor cervical ou epistáxis. Os antecedentes pessoais eram irrelevantes.

À observação constatou-se uma tumefacção firme e indolor do terço médio e inferior da face (Figura 1, 2 e 3), mímica facial mantida e simétrica. A endoscopia nasal revelou um edema da mucosa nasal e rinorreia serosa, sem outras alterações (nomeadamente, presença de crostas, exsudado purulento, perfuração septal). A observação da cavidade oral, faringe e laringe não revelou alterações. A palpação cervical foi inocente, não se conseguindo identificar adenopatias.

Analiticamente verificou-se um aumento da proteína C reactiva (6,6 mg/dL), sem leucocitose associada (leucócitos de 10.000).

O estudo imagiológico com tomografia computorizada revelou uma extensa densificação das partes moles dos lábios e da região nasal, sobretudo à esquerda, com ausência de erosão

óssea e múltiplas adenopatias nos níveis I, II, retrofaríngeas e espinhais sem áreas de necrose (Figura 4 e 5).

Figuras 1, 2 e 3: Fotografia de perfil esquerdo e frontais do doente antes

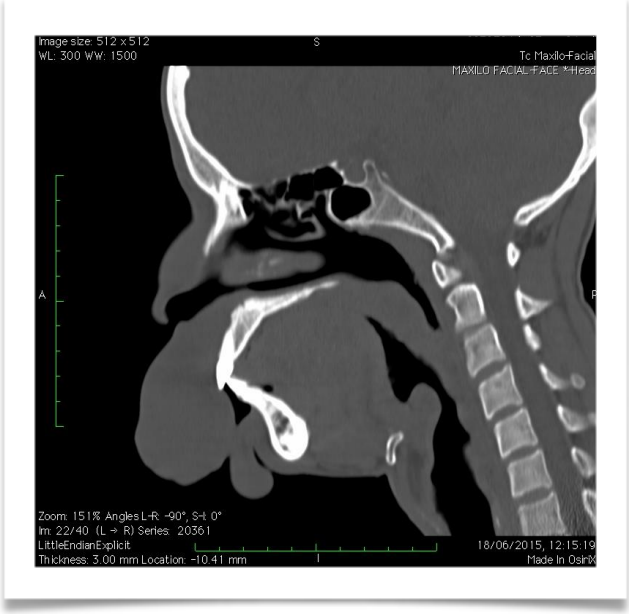

Figura 4: Corte sagital de tomografia computorizada antes do tratamento

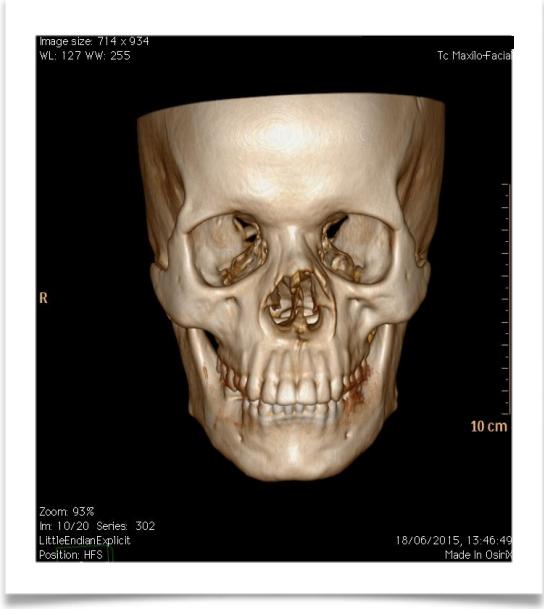

Figura 5: Reconstrução tridimensional de tomografia computorizada antes do tratamento

O exame histopatológico mostrou hiperplasia e hiperqueratose do epitélio; intenso infiltrado inflamatório constituído por linfócitos, plasmócitos, células histiocitárias com formação de

granulomas com células gigantes multinucleadas de tipo Langhans e abundantes eosinófilos, não tendo sido identificados microrganismos compatíveis com fungos. As culturas foram negativas.

O caso clínico foi discutido por uma equipa multidisciplinar (com colaboração da Otorrinolaringologia e Cirurgia Cérvico-Facial, Doenças Infecciosas, Imagiologia e Oncologia Médica), tendo sido admitido o diagnóstico de conídiobolomicose rino-facial, pelo que foi instituída terapêutica antifúngica com itraconazol 100mg bid. Observou-se uma melhoria clínica progressiva ao longo dos vários meses de seguimento clínico, com redução significativa da tumefacção facial. Com dois anos de seguimento, mantém apenas um edema residual da pirâmide nasal à esquerda e do lábio superior (Figura 6, 7 e 8).

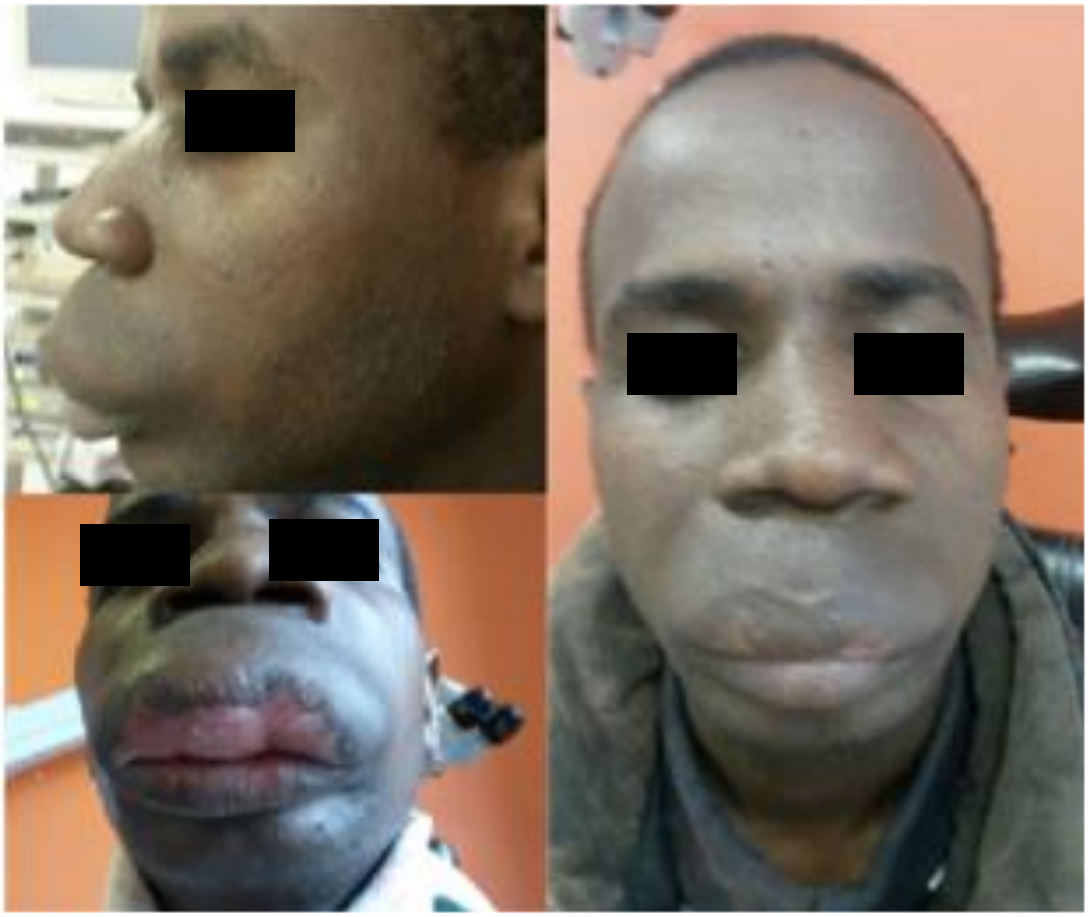

Figuras 6, 7 e 8 Fotografia de perfil esquerdo e frontais do doente após terapêutica anti-fúngica

Discussão

O diagnóstico definitivo da Conídiobolomicose Rino-Facial requere demonstração histopatológica e isolamento do agente etiológico em cultura [6]. Porém, ainda que o exame histológico com coloração hematoxilina-eosina possa revelar hifas encapsuladas num material amorfo eosinofílico (fenómeno Splendore-Hoeppli) em até 40% dos casos, as culturas são positivas em apenas 15 a 50% dos casos e os estudos serológicos específicos e de *polymerase chain-reaction* estão disponíveis apenas em centros especializados [4,7]. Assim, o diagnóstico correcto

da Conídiobolomicose constitui um desafio, sendo baseado frequentemente na anamnese e exame objectivo.

Não existem *guidelines* para o tratamento desta patologia e, ainda que a terapêutica antifúngica seja a base do tratamento, o antifúngico (anfotericina B, itraconazole, fluconazole, terbinafina), as doses e a duração específicas do tratamento não estão definidos na literatura. Existe porém consenso que um dia- gnóstico precoce e um tratamento ao longo de meses sejam necessários para a abordagem adequada desta doença. É defendido por alguns autores que a terapêutica deva ser mantida até uma redução de pelo menos 75% do edema facial [7].

O tratamento cirúrgico não é consensual, com autores a defender que possa levar à disseminação da doença. Ainda assim, a cirurgia assume um papel importante em casos selecionados (p.e. desbridamento cirúrgico de tecido desvitalizado), nas complicações (envolvimento orbitário ou laríngeo) ou na reconstrução facial das sequelas estéticas, após tratamento antifúngico [3,7].

A diferenciação entre persistência de infecção e cura com sequelas constitui outro desafio na abordagem desta patologia, uma vez que pode persistir algum grau de tumefacção ou deformação facial após tratamento adequado.

Conclusão

O presente caso clínico demonstra a importância de uma avaliação multidisciplinar na abordagem desta patologia específica, não só pela sua raridade, mas também pelo desafio diagnóstico e terapêutico que constitui.

Referências

1. Dutta S, Sarkar S, Dora S. *Conidiobolomycosis: A case report of rare fungal infection from the eastern India*. Indian Dermatol Online J. 2015 Nov-Dec; 6(6): 393–395.
2. Cherian LM, Varghese L, Panchatcharam BS et al. *Nasal conidiobolomycosis: A successful treatment option for localized disease*. J Postgrad Med 2015;61:143-144.
3. Ramirez J, Maguina P. *Invasive Conidiobolomycosis Can Be Successfully Treated on Burn Survivors.* Journal of Burn Care & Research Volume 38, Number 1. e460-e463.
4. Blumentrath CG, Grobusch MP, Matsiégui P et al. *Classification of Rhinoentomophthoromycosis into Atypical, Early, Intermediate, and Late Disease: A Proposal*. PLoS Negl Trop Dis 9(10): e0003984.
5. Janappriya G, Gunasekera CN, Keragala B et al. *Disfiguring facial mycoses - a diagnostic and therapeutic challenge*. J Eur Acad Dermatol Venereol. 2018 May;32(5):e167-e168.
6. Arora N, Bhargava, EK, Rai V. *Nasal Conidiobolomycosis - The Unknown Threat*. Journal of Clinical and Diagnostic Research. 2016 Dec, Vol-10(12): MJ01.
7. Grupta M, Narang T, Kaur R et al. *A prospective case series evaluating efficacy and safety of combination of itraconazole and potassium iodide in rhinofacial conidiobolomycosis*. International Journal of Dermatology 2016, 55, 208-214.

Acute postpartum dyspnea

Dispneia aguda pós-parto

Margarida Cal[1]; Catarina Reis de Carvalho[1], Ana Aguiar[1]

Departamento de Ginecologia, Obstetrícia e Medicina da Reprodução, Hospital de Santa Maria, Centro Hospitalar Universitário Lisboa Norte

Abstract

Spontaneous acute aortic dissection in pregnancy is a rare and potentially fatal clinical entity, both for the mother and the fetus. Most of the time, its etiology is related to connective tissue diseases, cardiac valve changes or trauma. We present the case of a 42-year-old pregnant woman, previously healthy and without known risk factors, who underwent an emergent cesarean section due to a non-reassuring fetal state of both fetuses, and thereafter developed a picture of severe acute dyspnea accompanied by arterial desaturation in the immediate postpartum period. Thoracic tomography detected an extensive aortic dissection, having undergone urgent surgery for resection of the ascending aorta and replacement with vascular prosthesis. This case intends to highlight the challenge experienced in the diagnosis of rare clinical entities such as the one described here, as well as the importance of a multidisciplinary approach in complex and potentially fatal clinical situations.

Keywords: dyspnea, aortic dissection, pregnancy

Resumo

A dissecção aórtica aguda espontânea na gravidez é uma entidade clínica rara e potencialmente fatal, tanto para a mãe como para o feto. Na maioria das vezes a sua etiologia está relacionada com doenças do tecido conjuntivo, alterações valvulares cardíacas ou trauma. Apresentamos o caso de uma grávida primigesta de 42 anos, previamente saudável e sem fatores de risco conhecidos, submetida a uma cesariana emergente por estado fetal não tranquilizador de ambos os fetos, que no puerpério imediato desenvolve um quadro de dispneia aguda intensa acompanhado de dessaturação arterial. A tomografia torácica detetou uma extensa dissecção aórtica, tendo sido submetida a cirurgia urgente para ressecção da aorta ascendente e substituição por prótese vascular. Este caso pretende realçar o desafio experienciado no diagnóstico de entidades clínicas raras como aquela aqui descrita, bem como a importância da abordagem multidisciplinar nas situações clínicas complexas e potencialmente fatais.

Palavras-chave

Dispneia, dissecção aórtica, gravidez

Introdução

A ocorrência de dispneia aguda pós-parto abre um leque de diagnósticos diferenciais extenso e complexo, cujo espectro de gravidade se revela igualmente amplo. Entre as etiologias mais graves de dispneia na população obstétrica incluem-se o tromboembolismo pulmonar, a embolia de líquido amniótico, intoxicação por anestésicos, choque anafilático e doenças cardiovasculares como a miocardiopatia peri-parto, o enfarte agudo do miocárdio ou a disseção aórtica. Se não forem diagnosticadas e abordadas atempadamente, todas estas situações podem culminar em paragem cardiorrespiratória.

A dissecção aórtica na gravidez é uma entidade clínica rara e potencialmente fatal, na maioria das vezes associada a alterações genéticas ou anatómicas predisponentes, como o síndrome de marfan ou a válvula aórtica bicúspide [1]. Cerca de metade dos casos de dissecções aórticas em mulheres jovens ocorre durante a gravidez [2]. Contudo, mesmo na ausência de fatores de risco, não deve ser descartada a hipótese diagnóstica de dissecção aórtica perante um quadro de dispneia aguda na gravidez ou puerpério.

Apresentamos aqui um caso de dissecção aórtica aguda espontânea, não traumática, numa grávida previamente saudável sem fatores de risco conhecidos.

Caso Clínico

Apresentamos o caso de uma mulher primigesta de 42 anos, leucodérmica, com antecedentes pessoais de perturbação da ansiedade, medicada com sertralina e um benzodiazepínico, sem outra patologia médica conhecida e sem antecedentes cirúrgicos, alergias medicamentosas, hábitos tabágicos ou alcoólicos. A gravidez foi vigiada em consulta de medicina materno-fetal (CMMF) do hospital por se tratar de uma gestação gemelar monocoriónica biamniótica pós-fertilização *in vitro* (FIV) com tensão arterial *borderline* durante gravidez, não medicada. O rastreio combinado do primeiro trimestre foi de baixo risco para aneuploidias. A ecografia do segundo trimestre não demonstrou alterações morfológicas fetais; o feto 1 encontrava-se no percentil 11 e o feto 2 no percentil 50, sem evidência de síndrome de transfusão feto-fetal e com evidência de fluxos normais nas artérias uterinas. Face ao perfil tensional *borderline*, realizou no terceiro trimestre duas avaliações da proteinúria de 24h, ambas negativas, para exclusão de doenças hipertensivas da gravidez, nomeadamente pré-eclâmpsia. Por constatação ecográfica de colo curto às 30 semanas de gravidez, foi administrada betametasona para indução da maturação pulmonar fetal.

Na consulta de rotina às 33 semanas e 5 dias, a grávida apresentava-se com uma tensão arterial de 137/90mmHg e o traçado cardiotocográfico (CTG) do primeiro feto não apresentava critérios de reatividade. Realizou ecografia de urgência que revelou diminuição dos movimentos e desaceleração do crescimento do feto 1, encontrando-se este no percentil 9,8. Em ambos os fetos o índice cérebro-placentar era inferior ao percentil 5 (<P5), diagnosticando redistribuição hemodinâmica nos dois fetos. Perante o cenário de restrição de crescimento do feto 1 com redistribuição hemodinâmica de ambos os fetos e tensão arterial no limite superior da normalidade,

optou-se por internamento da grávida na enfermaria de medicina-materno fetal para vigilância do bem-estar materno e fetal e investigação de pré-eclâmpsia.

Durante o internamento a grávida manteve-se assintomática, hemodinamicamente estável com perfil tensional *borderline* e frequência cardíaca normal. As avaliações analíticas seriadas realizadas durante o internamento revelaram um valor de hemoglobina normal, função renal e função hepática sem alterações e os dois doseamentos da proteinúria de 24h foram negativos, excluindo o diagnóstico de pré-eclâmpsia. Repetiu ainda a avaliação ecográfica, com avaliações fluxométricas sobreponíveis às da admissão.

Ao quarto dia de internamento, às 34 semanas e 1 dia de gestação, a equipa de urgência foi chamada ao internamento por evidência de registo CTG não tranquilizador em ambos os fetos, registando uma taquicardia fetal mantida e desacelerações síncronas em ambos os fetos, profundas e repetidas, que não reverteram após cerca de duas horas de vigilância e manobras (Figura 1). Face

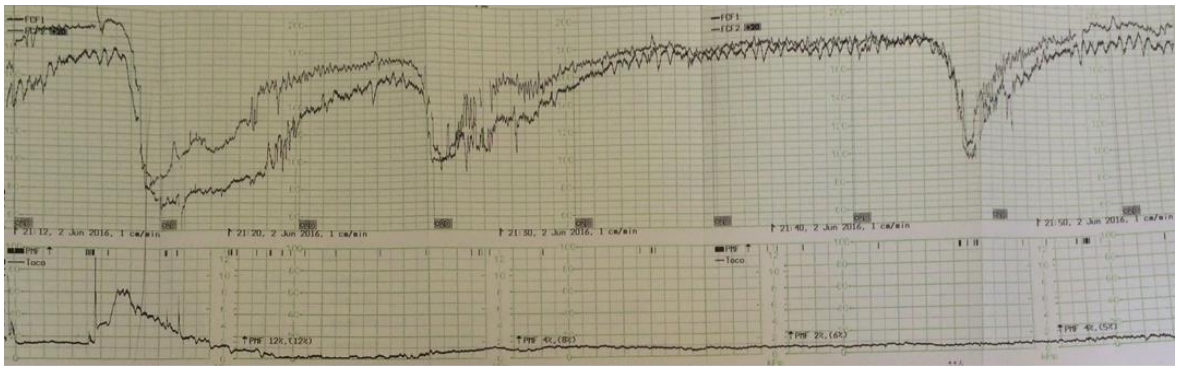

ao estado fetal não tranquilizador de ambos os fetos, optou-se pela realização de cesariana emergente sob anestesia geral. O procedimento cirúrgico decorreu sem intercorrências, destacando-se hipotensão materna ligeira, mas conservação da estabilidade hemodinâmica intraoperatória, com tensão arterial (TA) sistólica variando entre 80-110mmHg, diastólica 40-57mmHg, frequência cardíaca (FC) 79-90bpm, saturação periférica de oxigénio (SpO2) de 95-99%, tendo sido aplicados 800 µg de misoprostol por via rectal no final da cirurgia como medida uterotónica profilática. O recém-nascido 1, do sexo feminino, nasceu com 2100g e Índice de Apgar (IA) 1/2/7; o recém-nascido 2, também do sexo feminino, nasceu com 2150g e IA 4/6/8, tendo sido ambos transferidos para Unidade de Cuidados Intensivos (UCI) neonatal.

A avaliação realizada duas horas após o parto não demonstrava qualquer alteração analítica (Hb 11,7g/dL) ou dos parâmetros clínicos avaliados, com PA 115/80mmHg, FC 80bpm, apirexia e débito urinário normal, útero bem contraído sem hemorragia vaginal ativa. Perante a estabilidade hemodinâmica descrita, a doente foi transferida para a enfermaria do puerpério, onde se manteve em vigilância.

No final do primeiro dia de puerpério, quase 24h após o parto, foi contactada a equipa de urgência de Obstetrícia por quadro de dispneia súbita intensa, sudorese, astenia e mal-estar generalizado, sem queixas de toracalgia. Ao exame objetivo a doente apresentava TA 131/55mmHg, FC 111bpm, SpO2 de 60% em ar ambiente e palidez mucocutânea com sinais de hipoperfusão, cianose labial e fervores generalizados em ambos os hemitóraces. O útero encontrava-se bem contraído, sem hemorragia vaginal ativa e os lóquios eram normais. A

abordagem inicial consistiu na aplicação de medidas direcionadas a um quadro suspeito de edema agudo do pulmão, com elevação da cabeceira, oxigenoterapia por máscara de alto débito a 16L/min, algaliação, administração de 2 fórmulas de furosemida e 100mg de hidrocortisona, bem como colheita de sangue para gasimetria arterial, que revelou pH 7,38, hipoxémia (pO2 49mmHg), hipocápnia (pCO2 32,2mmHg) e hiperlactacidémia de 20mg/dL. O débito urinário foi de 1600ml em 30 min e a SpO2 de 80% sob oxigenoterapia de alto débito. Apesar de todas as medidas de suporte, não houve melhoria do quadro nem reversão da hipoxémia, pelo que a doente foi transferida para a Unidade de Cuidados Intensivos Respiratórios (UCIR), onde foi sedada e submetida a entubação orotraqueal e ventilação mecânica invasiva, com cateterização central e arterial. O ecocardiograma demonstrou ventrículo esquerdo sem alterações, ventrículo direito com boa função sistólica global, moderada regurgitação tricúspide e veia cava inferior dilatada. Por suspeita de tromboembolismo pulmonar, foi realizada uma tomografia torácica de urgência, que revelou uma extensa dissecção aórtica aguda, do tipo A, com origem proximal ao nível da raiz da aorta e limite distal terminando na emergência das artérias renais. A TC demonstrava ainda consolidações pulmonares com envolvimento central e simétrico, suspeito de edema pulmonar e derrame pleural bilateral. Após avaliação pela equipa de Cirurgia Cardíaca, foi realizada uma cirurgia urgente sob cardioplegia e circulação extracorporal, com ressecção da aorta ascendente e substituição por prótese vascular. O pós-operatório decorreu na Unidade de Cuidados Intensivos da Cirurgia Cardiotorácica, com boa evolução clínica, tendo sido possível a extubação no dia seguinte à cirurgia. Ao segundo dia de pós-operatório a doente mantinha boas saturações de oxigénio sem suplementação e tolerava o decúbito e a deambulação, sendo transferida para a enfermaria da Cirurgia Cardiotorácica no terceiro dia de pós-operatório, clinicamente estável. A puérpera teve alta clínica ao sétimo dia de pós-operatório, clinicamente estável. Ambos os recém-nascidos tiveram uma evolução clínica favorável, estando em respiração espontânea em ar ambiente ao quinto dia de vida a tolerar a alimentação oral.

Discussão

A dissecção aórtica aguda em mulheres jovens saudáveis é uma entidade clínica extremamente rara, com múltiplos fatores de risco. Os mais importantes são a gravidez e as doenças do tecido conjuntivo, que podem associar-se a alterações da parede aórtica, como é o caso da síndrome de Marfan, síndrome de Loeys-Dietz, síndrome de Ehlers-Danlos, válvula aórtica bicúspide (VAB), síndrome de Turner ou disseção/aneurisma da aórtica torácica familiar, associado a mutação no gene MYH11 [3,4].

O terceiro trimestre da gravidez e o puerpério imediato constituem fatores de risco importantes para a ocorrência de dissecção aórtica aguda (DAA), devido ao estado hiperdinâmico e ao efeito hormonal nos leitos vasculares que se verifica nestas fases [5]. Estima-se que este tipo de síndrome aórtico agudo ocorra com uma incidência aproximada de 1,2 casos por milhão na mulher não grávida, estando o terceiro trimestre da gravidez associado a um aumento de cerca de 11 vezes nesta incidência [6].

Entre os fatores de risco mais comuns destacam-se a idade avançada e a hipertensão crónica prévia à gravidez, presente em cerca de 70% dos casos [2,[7]]. A doença aterosclerótica, hipercolesterolémia, consumo tabágico ou de cocaína e as aortites inflamatórias como a arterite de Takayasu ou a arterite de células gigantes, são outros fatores de risco importantes. As doenças genéticas que afetam a aorta são uma causa importante e muitas vezes subestimada da dissecção aórtica [9]. No caso particular desta doente, não eram conhecidos fatores de risco à exceção da tensão arterial *borderline* durante a gravidez.

Na maioria das vezes a DAA apresenta-se como uma dor precordial súbita e muito intensa, podendo associar-se a dispneia, vómitos e síncope. É também comum a ocorrência de tamponamento pericárdico agudo e de insuficiência aórtica aguda, sobretudo nas dissecções mais proximais. Por vezes ocorre broncoespasmo devido à irritação do nervo vago pela dissecção da camada íntima da aorta.

O diagnóstico pode ser inicialmente suspeitado através de alterações na radiografia de tórax, como o alargamento da silhueta aórtica; porém, estas são evidentes em apenas 85% dos casos, pelo que um exame normal não exclui esta patologia. O ECG é geralmente inespecífico [1,9]. A tomografia computorizada, ressonância magnética e o ecocardiograma transesofágico são os métodos de eleição para diagnosticar a dissecção aórtica e suas variantes (úlcera aterosclerótica penetrante e hematoma intramural), e devem obrigatoriamente avaliar o envolvimento do segmento proximal da aorta.

Na maioria dos casos de dissecção aórtica, o principal achado histológico encontrado é a degeneração quística da média. Esta alteração, tal como a perda de tecido elástico, é típica em doentes mais jovens com doença aórtica [[8]]. As alterações da estrutura da parede aórtica ocorridas durante a gravidez são muito semelhantes ao padrão de degeneração quística da média, o mais prevalente em doentes com dissecção aórtica [1].

Este tipo de síndrome aórtico agudo é causado por uma laceração do tipo circunferencial da camada íntima da parede da aorta que ocorre na maioria das vezes ao longo da parede lateral direita da aorta ascendente ou na aorta torácica descendente abaixo do canal arterial, locais onde a tensão de cisalhamento é maior [**Error! Bookmark not defined.**]. Após a ocorrência do evento índex, o fluxo pulsátil aórtico vai dissecando distalmente por entre as camadas da parede aórtica e seus ramos, criando um falso lúmen.

Os dois principais sistemas de classificação da dissecção aórtica aguda baseiam-se no padrão de envolvimento anatómico. A classificação de DeBakey subdivide-as em tipo I (lesão da íntima que envolve a aorta ascendente e descendente), Tipo II (dissecção limitada à aorta ascendente) e tipo III (dissecção circunscrita à porção descendente da aorta). A classificação de Stanford, atualmente a mais utilizada na prática clínica, categoriza as dissecções em tipo A, onde a dissecção envolve a aorta ascendente (dissecção proximal); e tipo B, limitada ao arco aórtico e/ou aorta descendente (dissecção distal). As dissecções que envolvem a aorta ascendente (tipo A) requerem uma intervenção cirúrgica emergente, com reparo vascular ou substituição por prótese, como foi o caso desta doente. No caso das dissecções agudas do tipo B, a abordagem médica é a estratégia inicial indicada, devendo administrar-se bloqueadores β-adrenérgicos como o propranolol, metoprolol ou o esmolol caso não haja contra-indicações, com o objetivo de atingir uma

frequência cardíaca de ±60 bpm, acompanhado de infusão de nitroprussiato de sódio para manter a pressão arterial sistólica ≤120 mmHg [**Error! Bookmark not defined.**].

A taxa de mortalidade na dissecção aórtica aguda é cerca de 1% por hora durante as primeiras horas, tornando o diagnóstico precoce e o tratamento essenciais para a sobrevivência [9].

Conclusão

O caso desta doente foi diferente de outros descritos na literatura, dado que esta grávida não tinha qualquer evidência de doenças do tecido conjuntivo, valvulopatia ou história de hipertensão arterial prévia à gravidez. Como a DAA é muito menos comum do que outras condições associadas dispneia, é importante existir um elevado índice de suspeição para fazer este diagnóstico. Apesar da potencial gravidade da dissecção aórtica aguda, uma intervenção atempada realizada por uma equipa multidisciplinar poderá culminar num desfecho clínico favorável, como ocorreu no caso que aqui reportamos, com sobrevivência da mãe e ambos os recém-nascidos.

Referências

1. Immer FF, Bansi AG, Immer-Bansi AS, et al. Aortic dissection in pregnancy: analysis of risk factors and outcome. Ann Thorac Surg. 2003 Jul; 76(1):309-14.
2. Zeebregts CJ, Schepens MA, Hameeteman TM, et al. Acute aortic dissection complicating pregnancy. Ann Thorac Surg. 1997; 64:1345–1348
3. Yuan S. Aortic Dissection During Pregnancy: A Difficult Clinical Scenario. Clinical Cardiology. 2013 Oct; 36(10):576–84
4. Braverman AC. Acute aortic dissection: clinician update. Circulation. 2010; 122:184–188.
5. Kinney-Ham L, Nguyen H, Steele R, Walters E. Acute Aortic Dissection in Third Trimester Pregnancy without Risk Factors. West J Emerg Med. 2011 Nov; 12(4): 571–574.
6. Nasiell J, Lindqvist PG. Aortic dissection in pregnancy: the incidence of a life-threatening disease. Eur J Obstet Gynecol Reprod Biol. 2010; 149:120–121.
7. Nienaber CA, Fattori R, Mehta RH, et al. Gender-related differences in acute aortic dissection. International Registry of Acute Aortic Dissection. Circulation. 2004 Jun 22; 109(24):3014-21
8. Borst HG, Heinemann MK, Stone CD. Basic Considerations. Borst HG. Surgical treatment of aortic dissection. New York, Churchill Livingstone 1996, 47–54, 282.
9. Braverman AC, Thompson R, Sanchez L. Diseases of the aorta. Bonow RO, Mann DL, Zipes DP, Libby P. Braunwald's Heart Disease, 9th ed. Philadelphia, Elsevier 2011